24th Annual Congress
ESVCP 2022 ECVCP
European Society College of Veterinary Clinical Pathology
Belgrade, Serbia | October 5-8, 2022

MISTERY SLIDES SESSION

- Cytology -

Carlo Masserdotti DVM

Dipl ECVCP, Spec Bioch Clin IAT

Brescia

IDEXX LABORATORIES

Case #1

- 11-year-old, DSH, neutered male cat.
- Sublingual lump, with mandibular involvement.

- FNCS of the lesion
- MGG stain

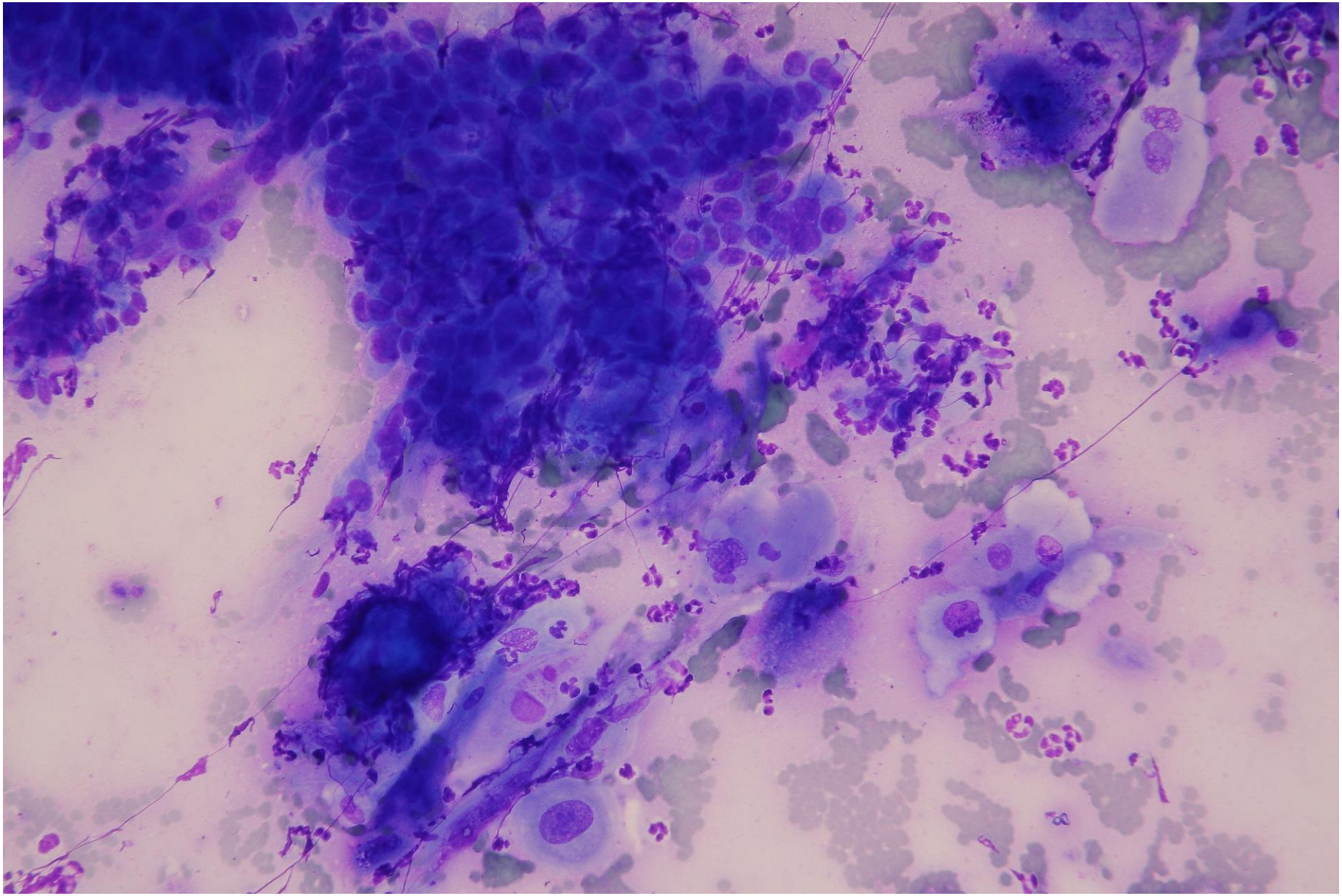

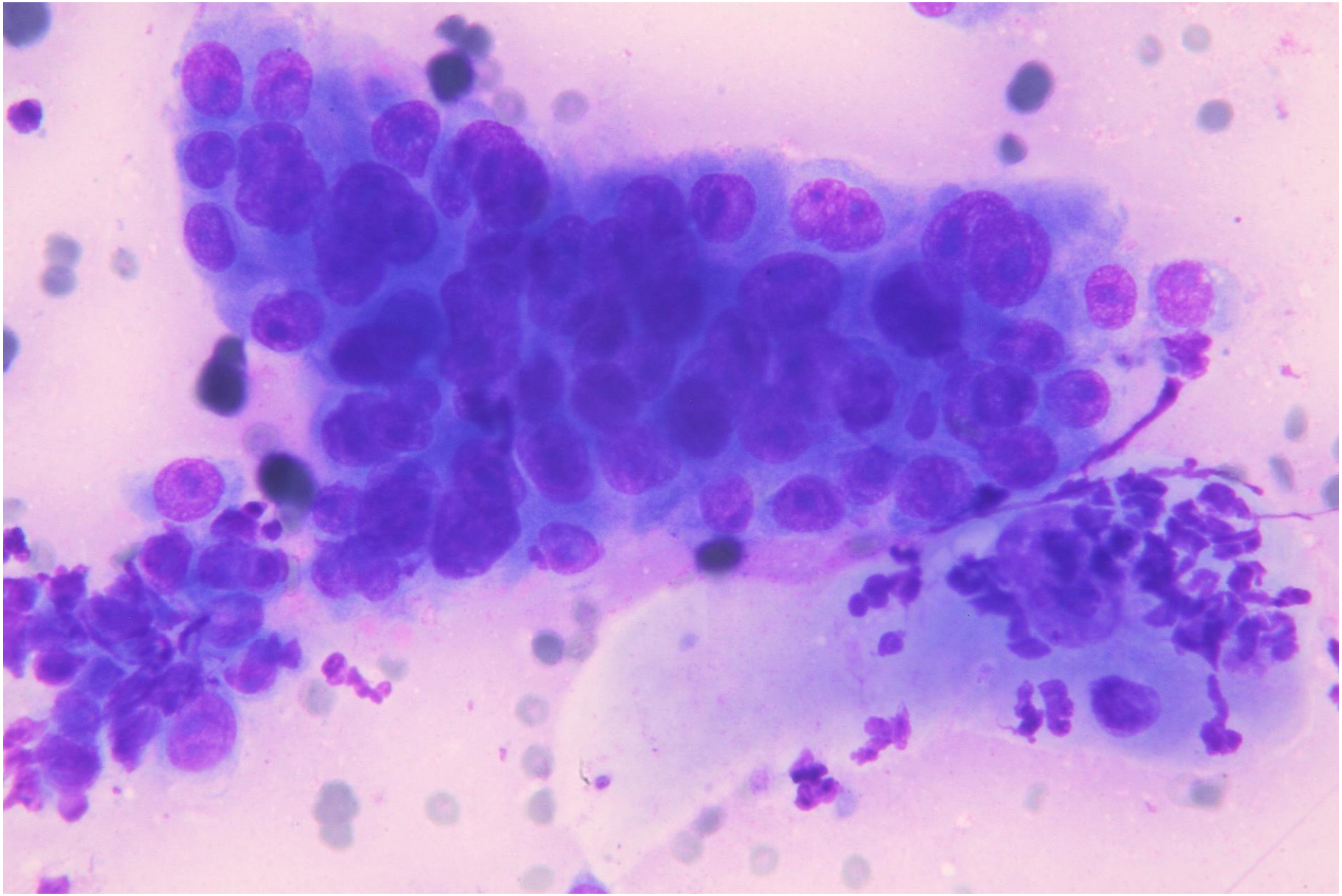

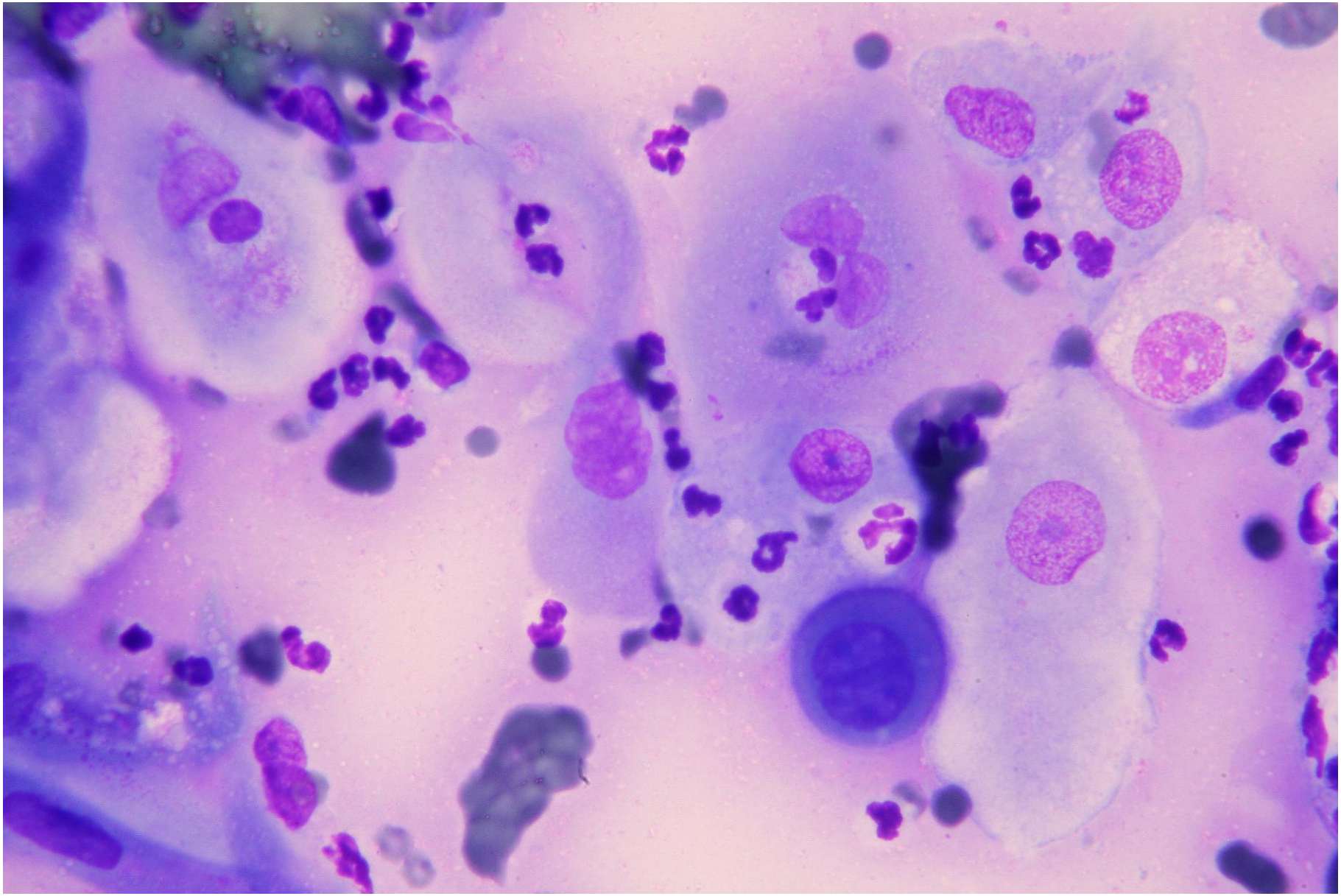

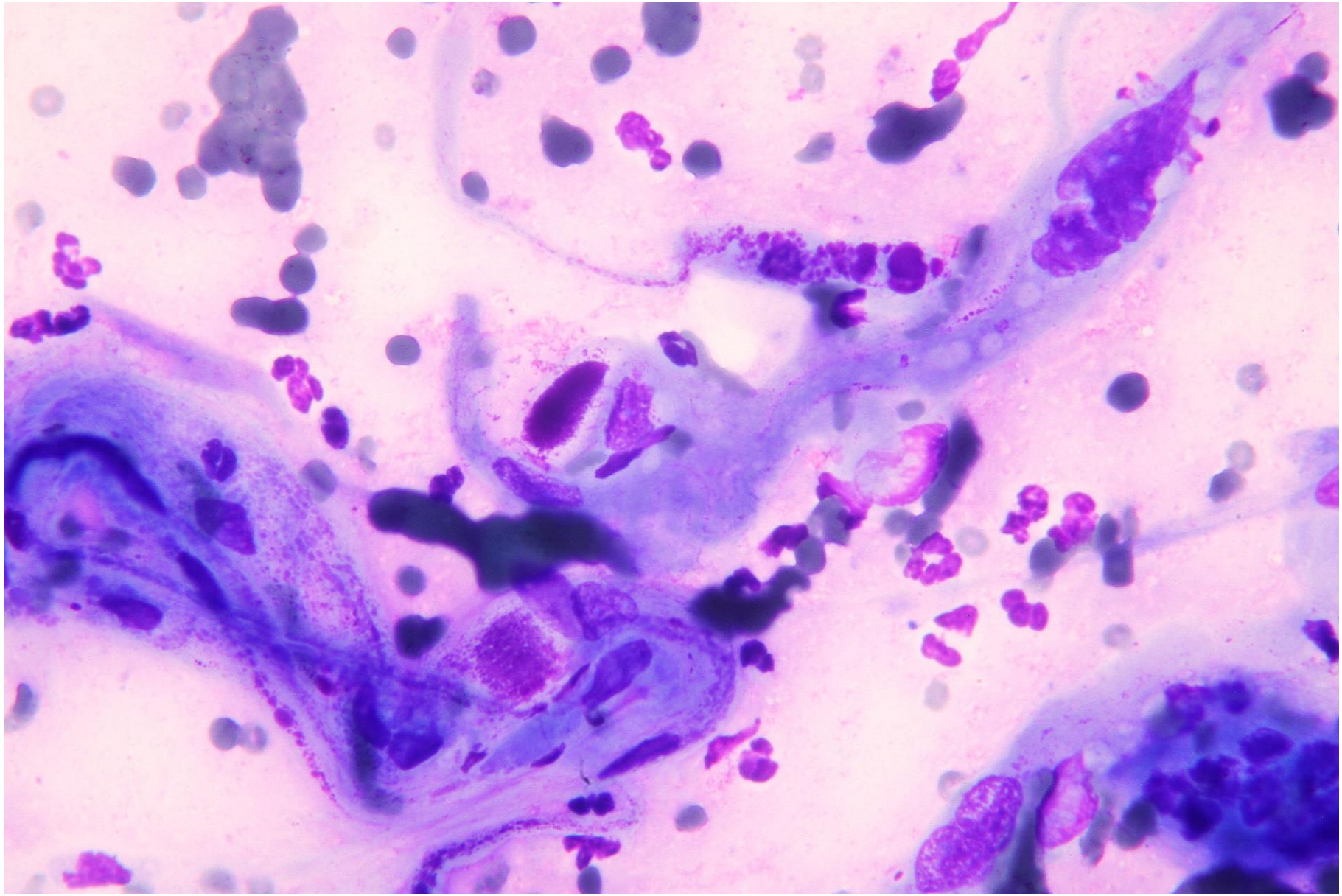

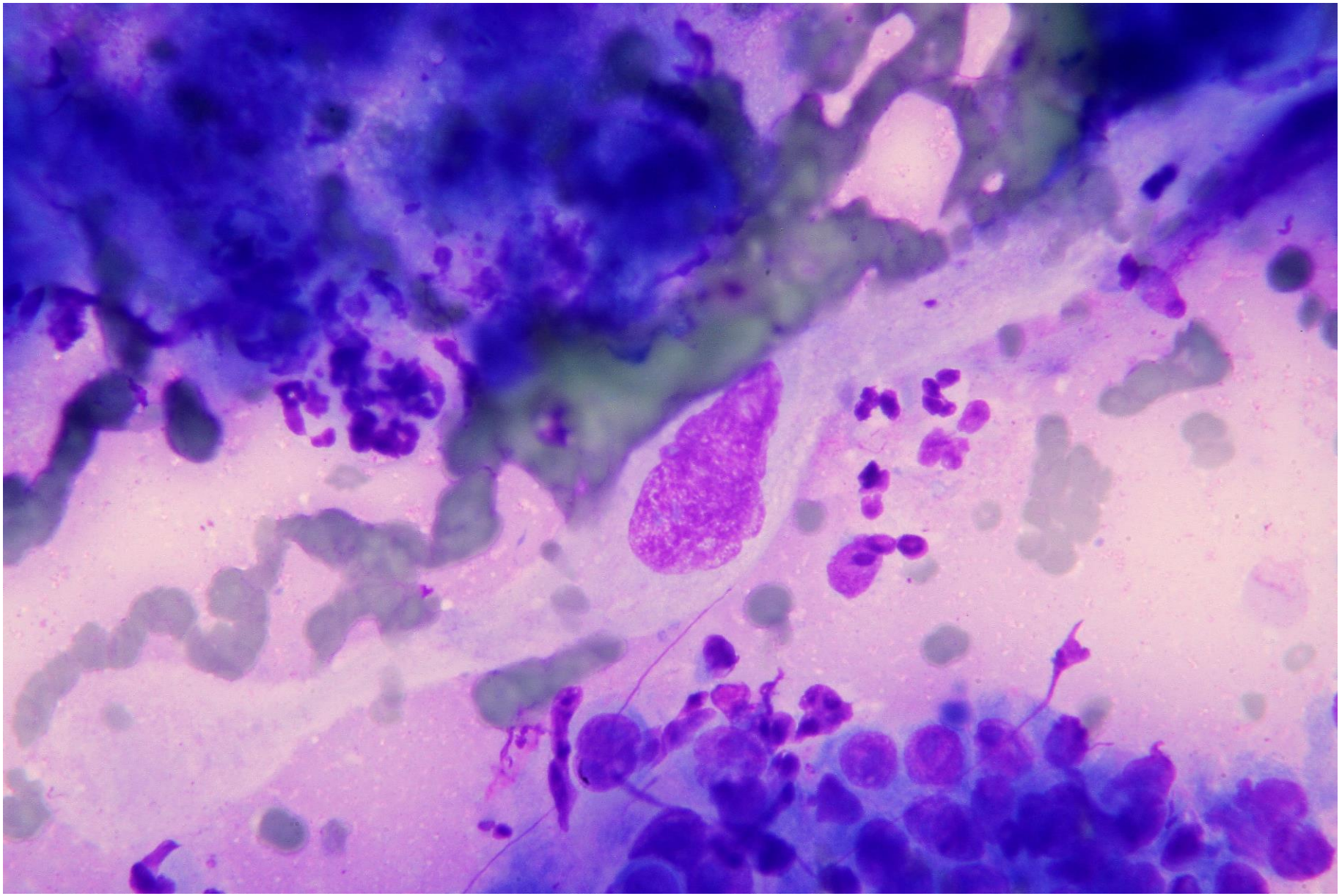

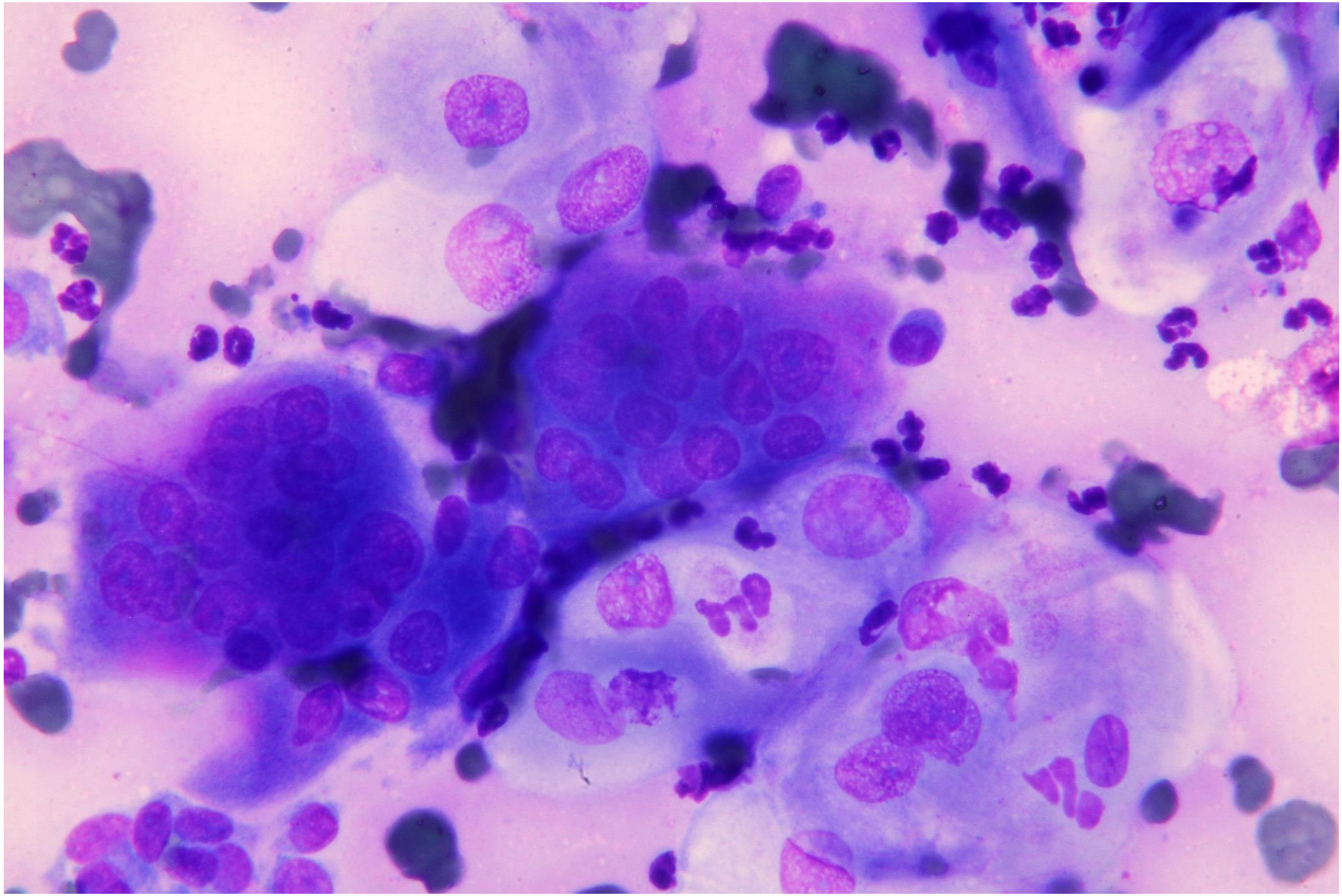

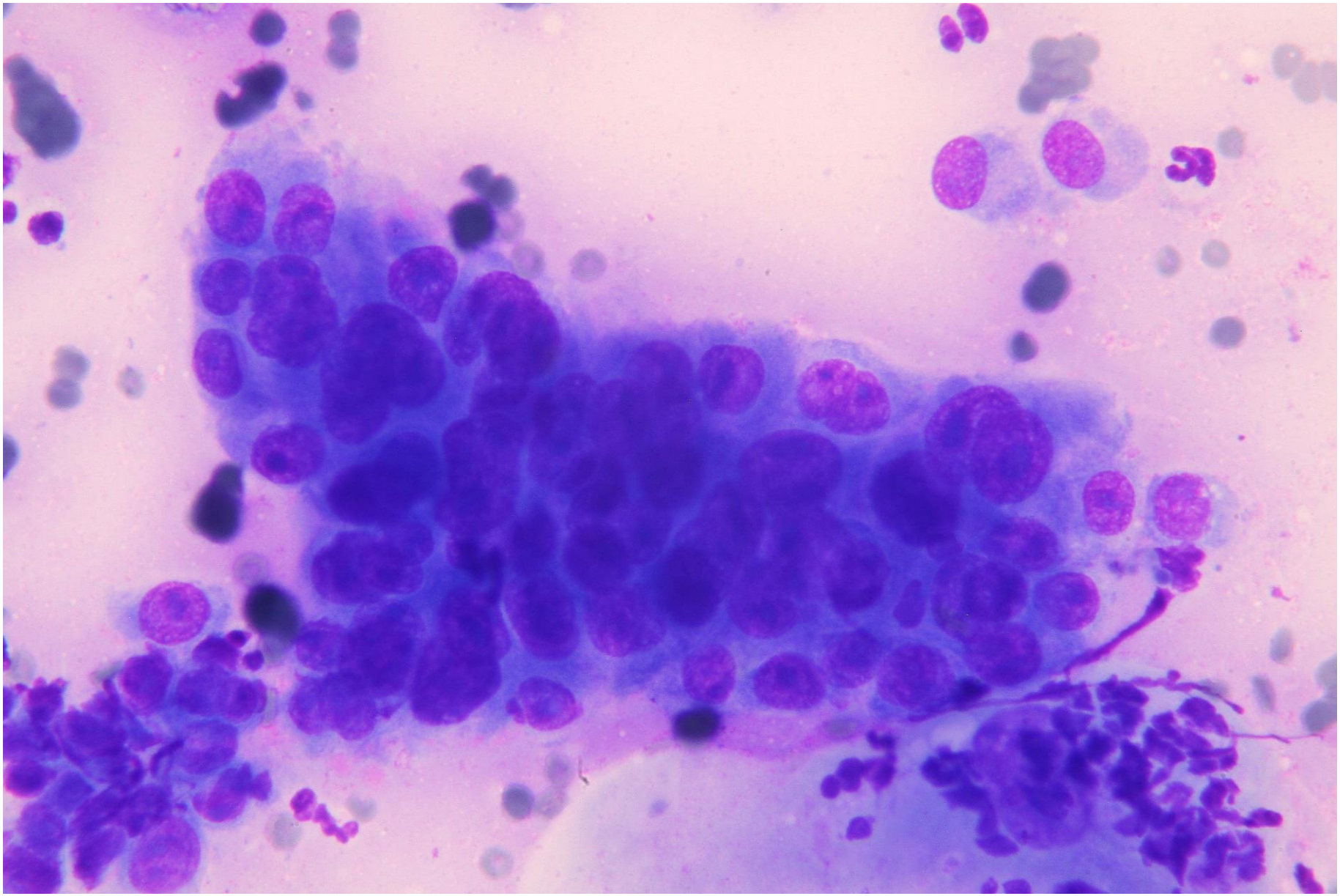

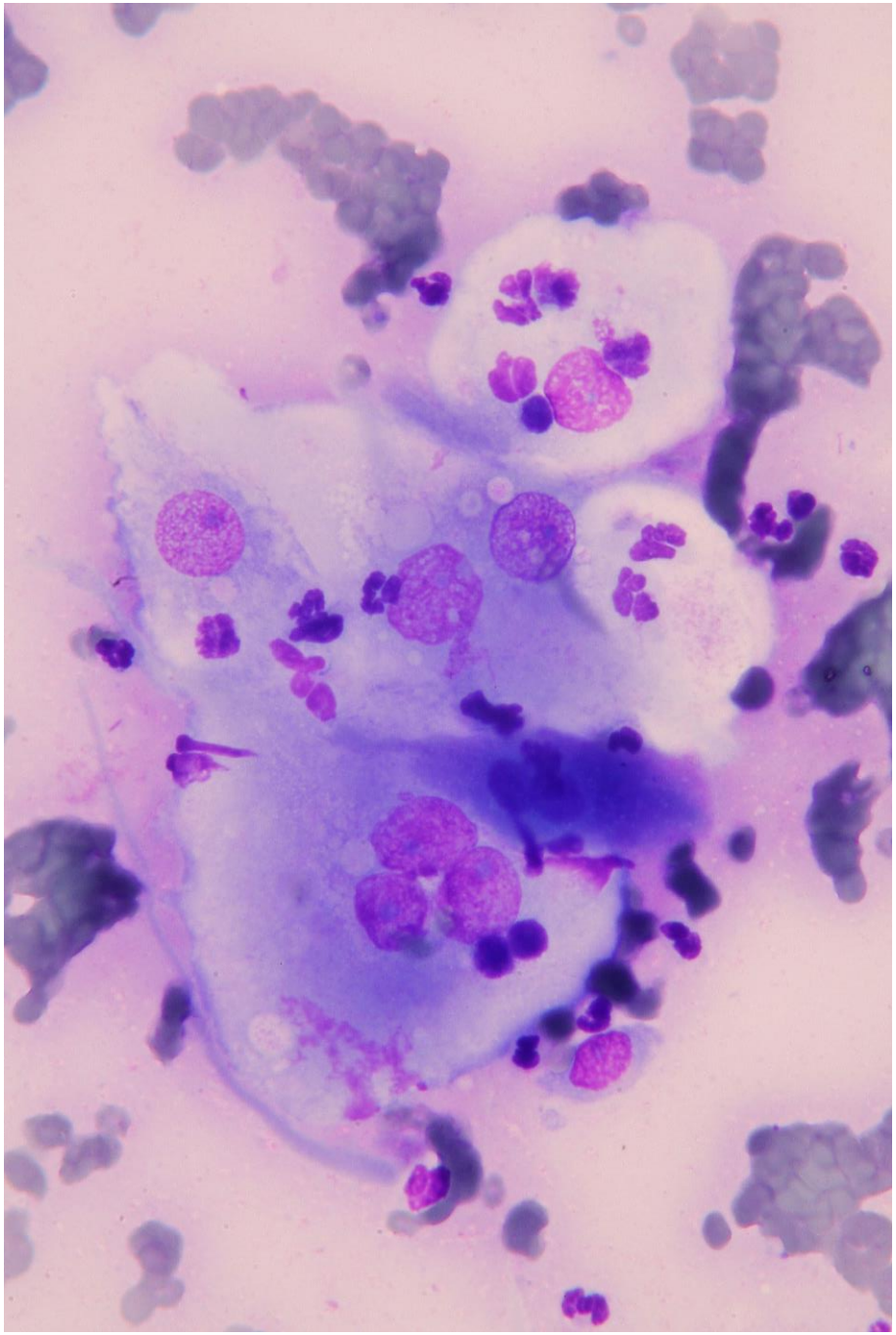

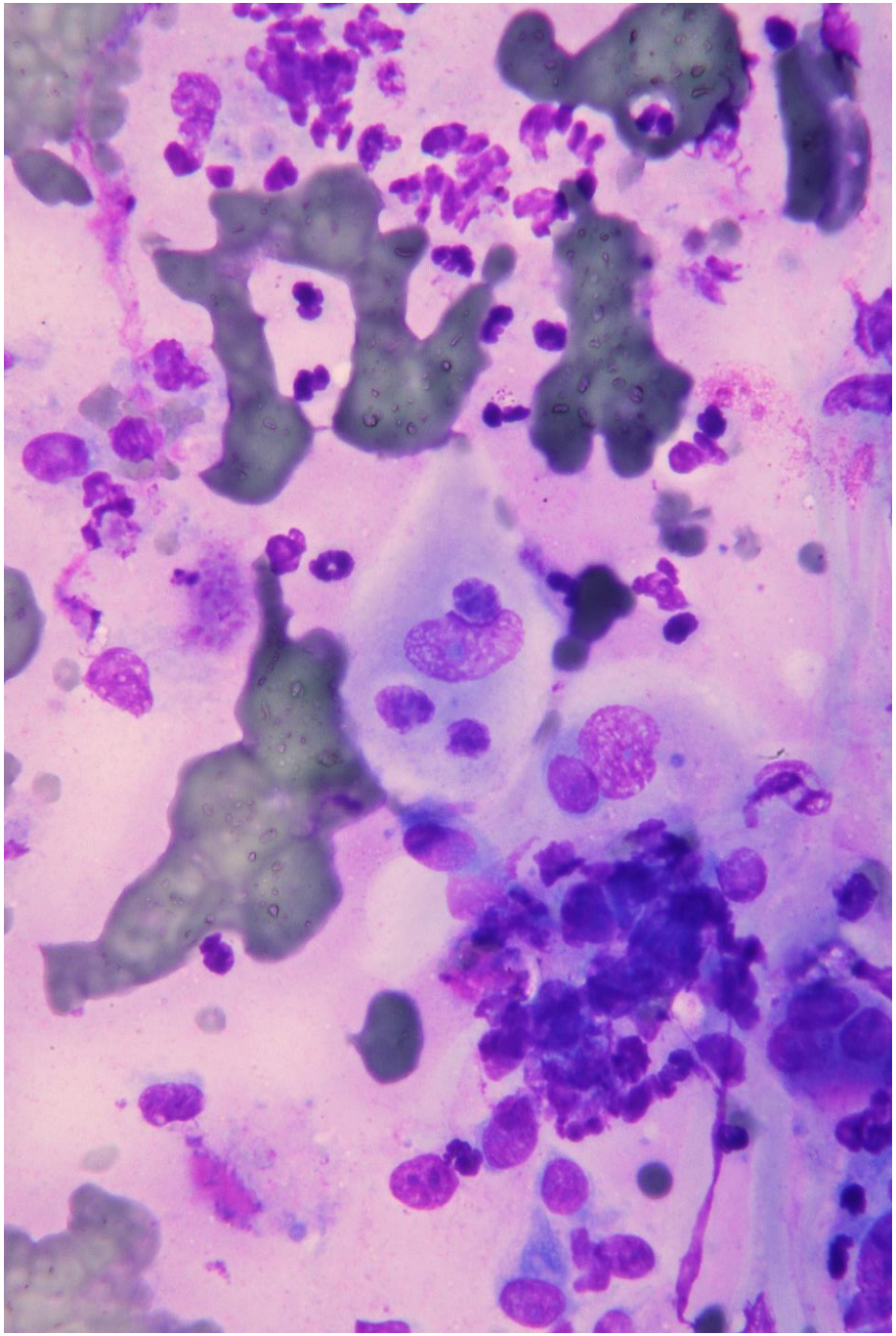

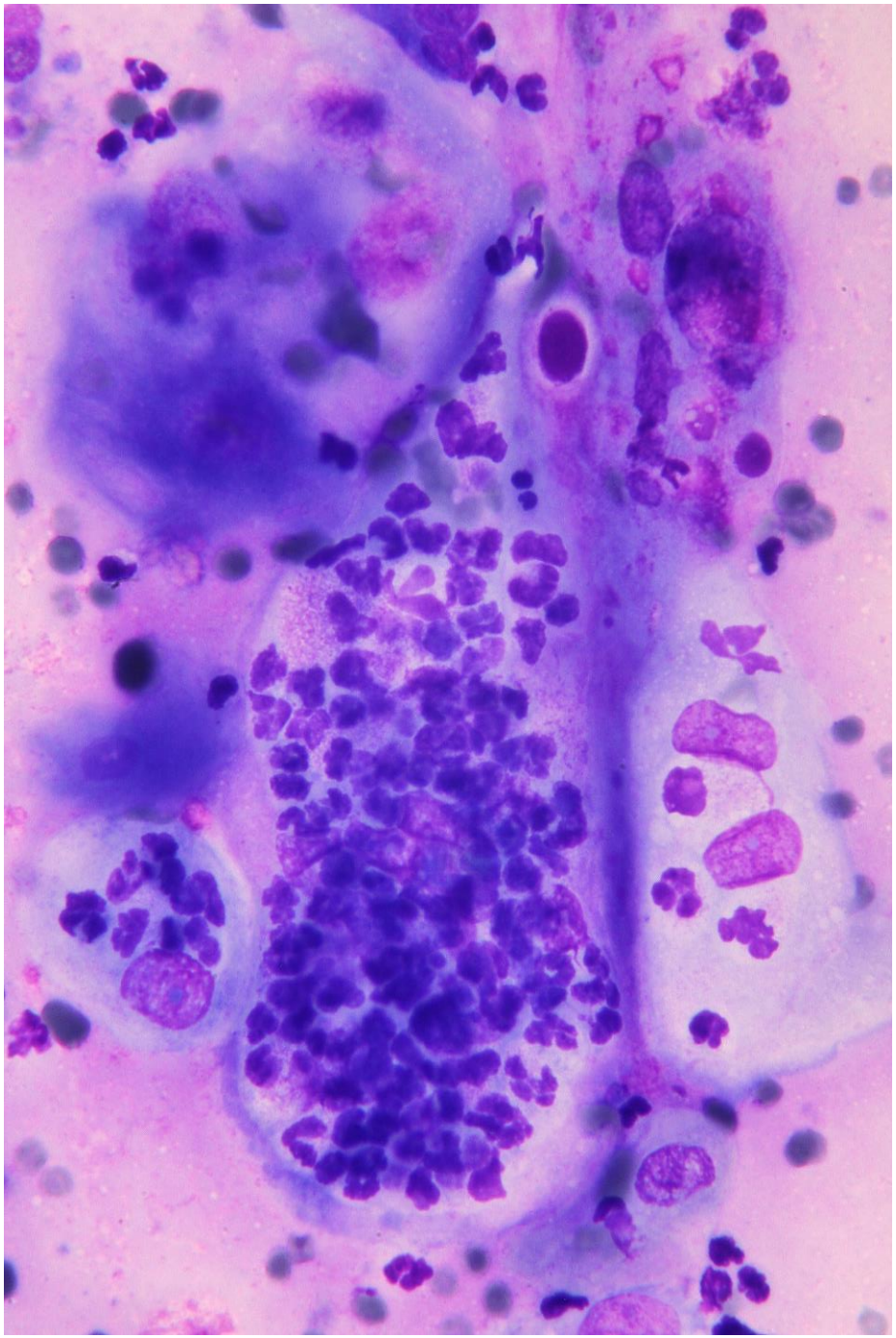

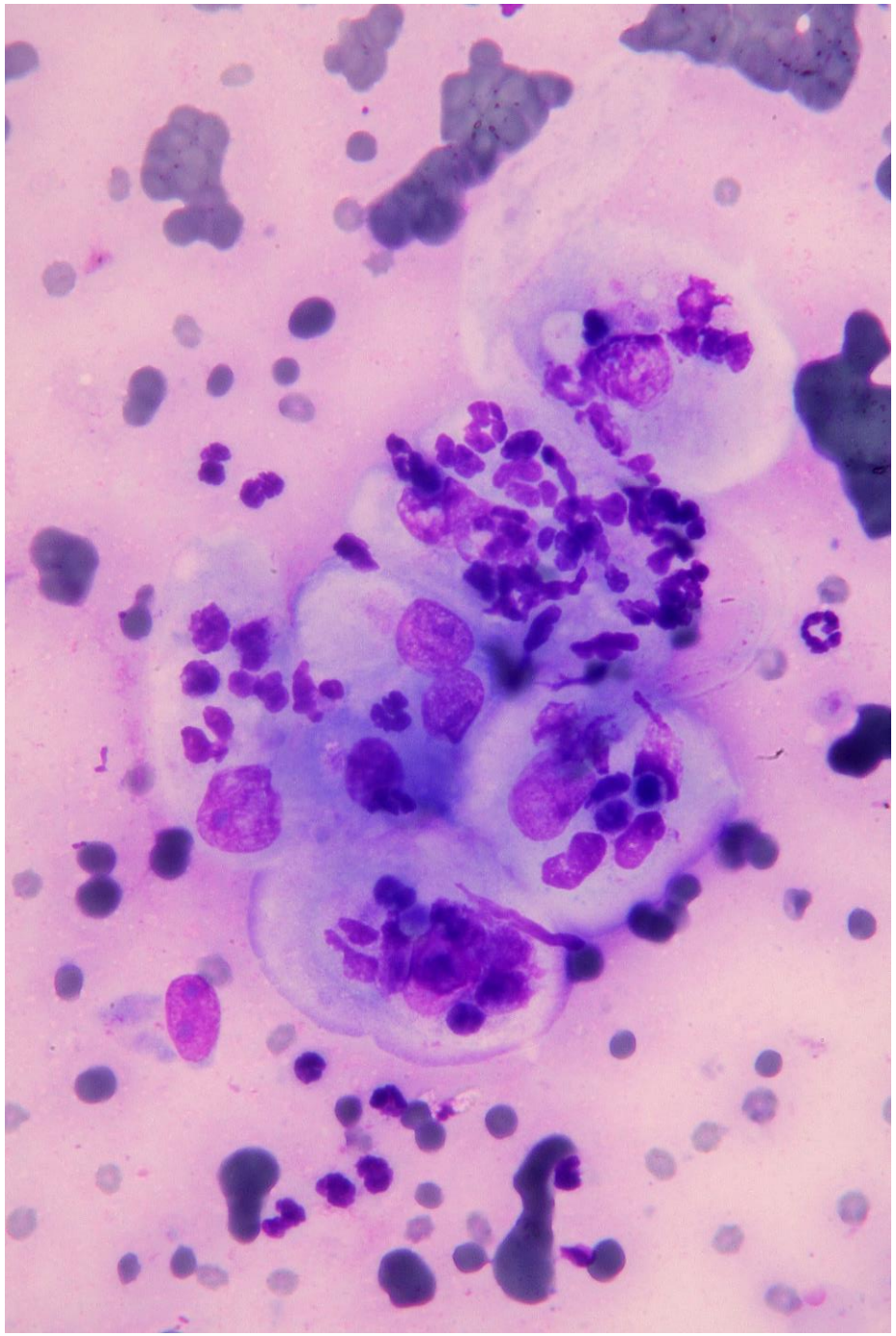

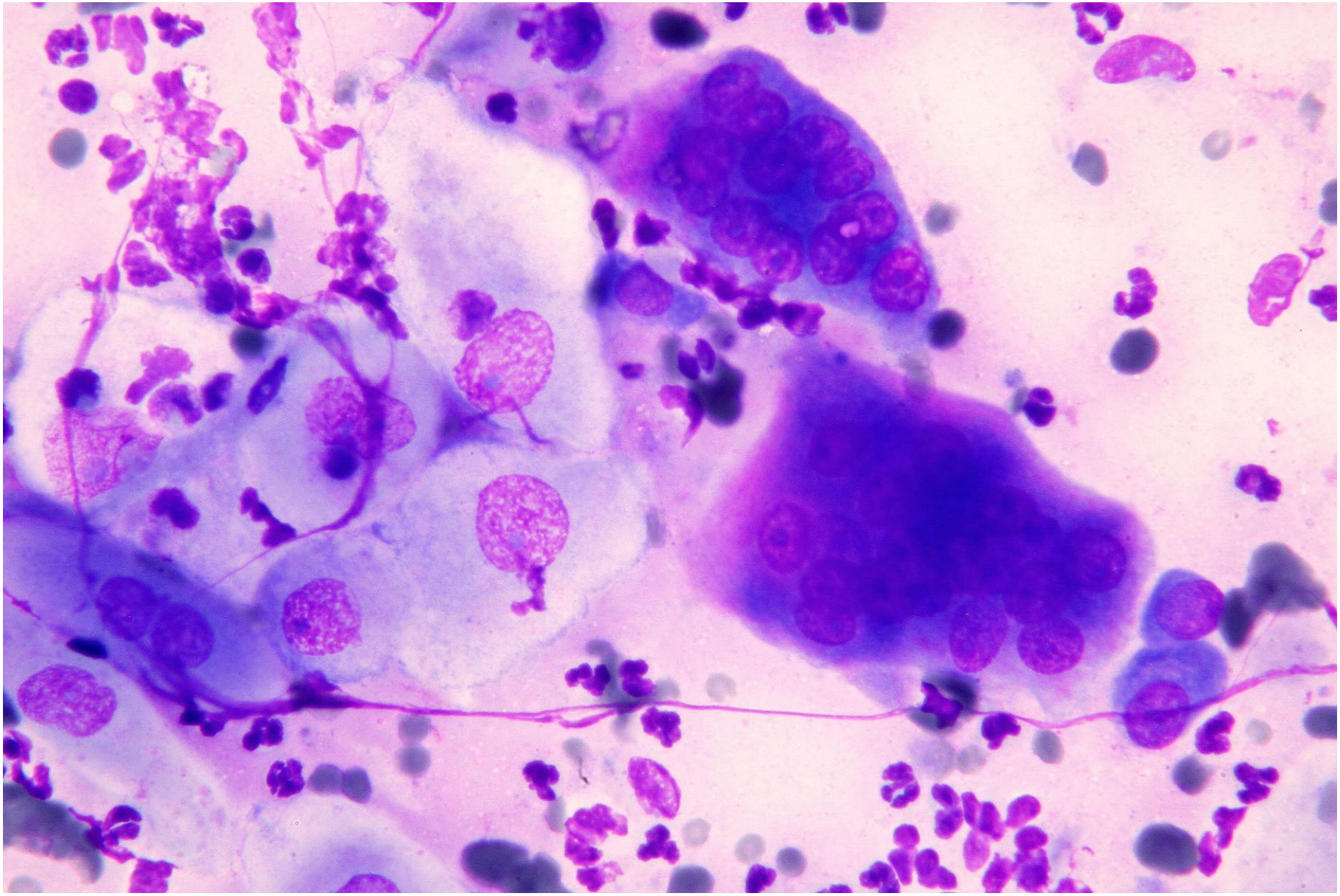

Cytologic findings

- Malignant epithelial cells
  - Cells with cuboidal cytoplasm
  - Malignant squamous cells
- Pavement arrangement
- Osteoblasts
- Osteoclasts
- Inflammatory cells
  - Emperipolesis

Diagnosis

- Cytologic diagnosis:
  - Squamous cell carcinoma (SCC) with bone involvement
- Histological diagnosis:
  - Infiltrative SCC with bone invasion

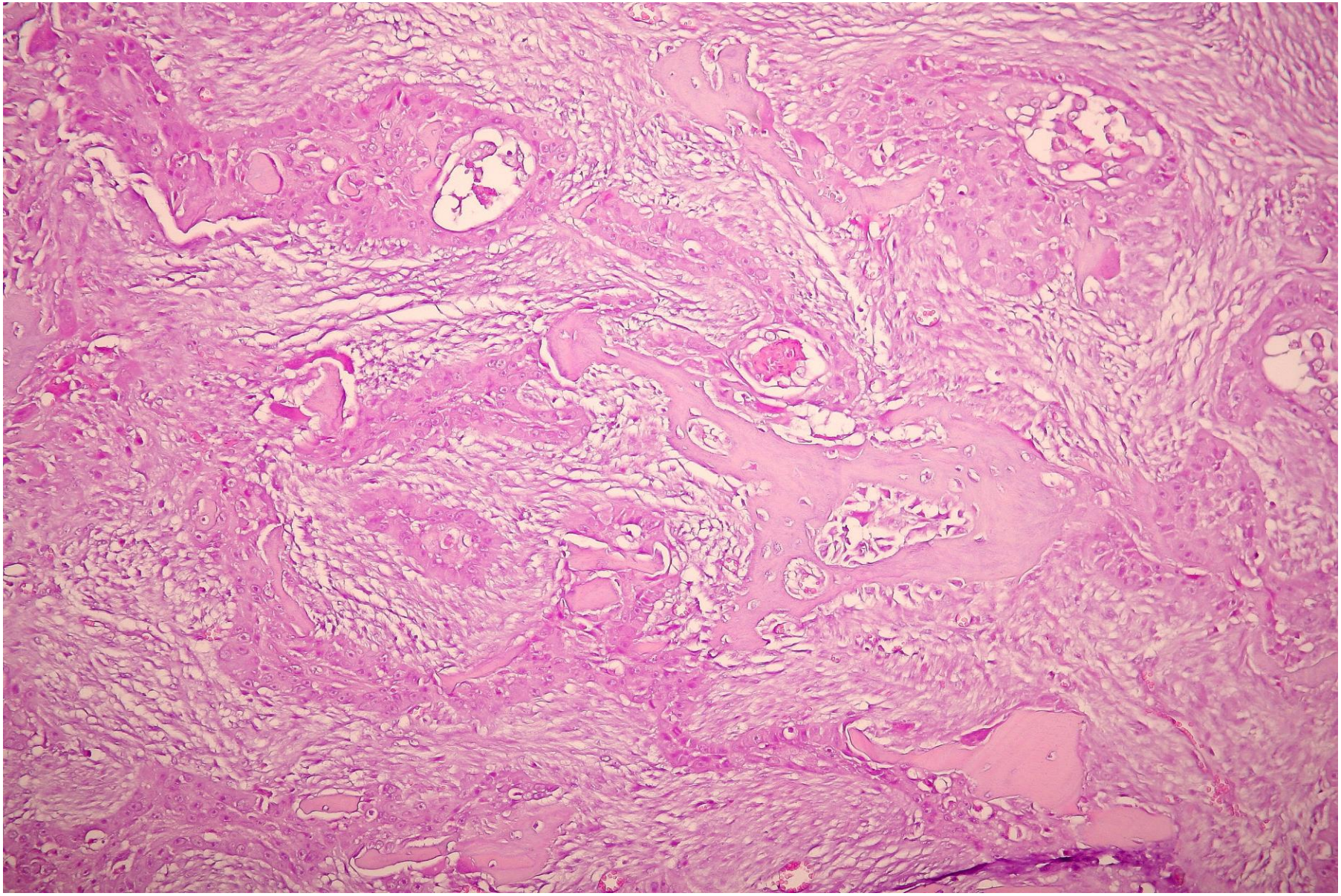

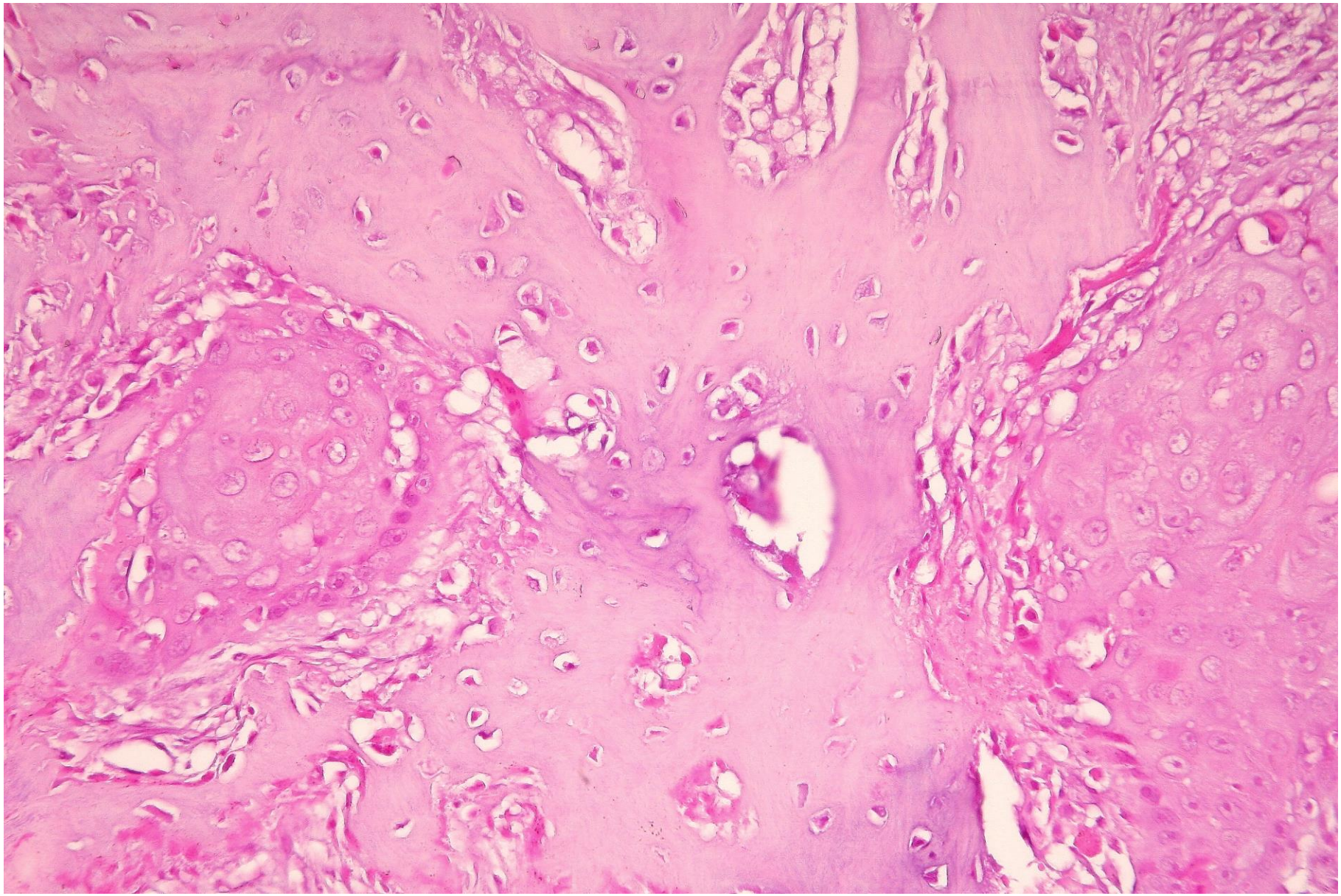

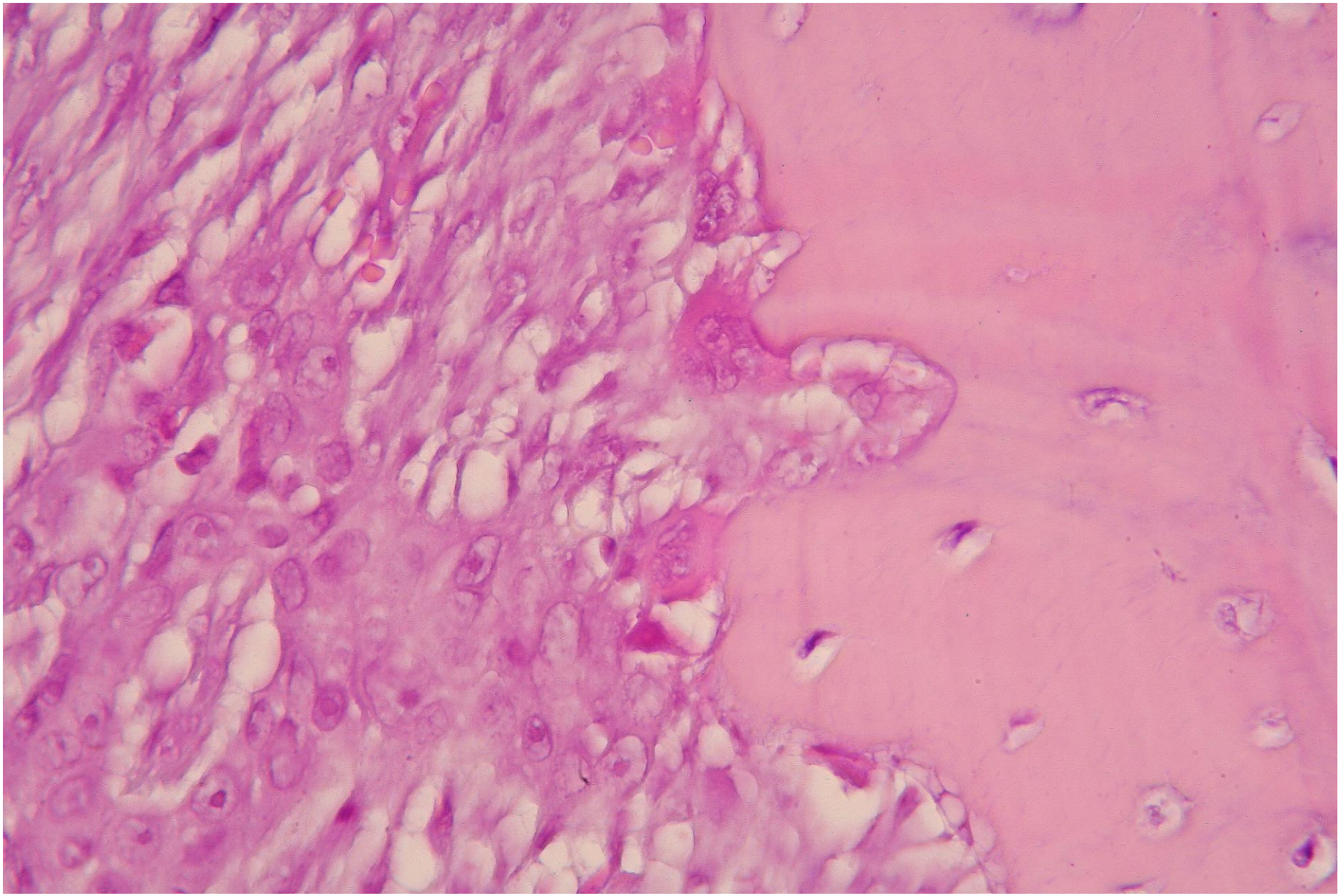

Discussion

- In a study of 52 cats with oral SCCs, bone invasion was present at diagnosis in 38 (**73%**) Postorino R et al. Oral squamous cell carcinoma in the cat. JAAHA, 1993(29):438-441
- In another study of 18 feline oral SCCs, bone invasion was present at diagnosis in 9 (**50%**) Gendler A et al. Computed tomographic features of oral squamous cell carcinoma in cats: 18 cases (2002-2008). JAVMA, 2010(236):319-325
- Among the prognostic indicator, bone involvement seems to be not evaluated Munday JS Tumors of the alimentary tract. In Meuten Tumors in Domestic Animals Vth ed. 2017:508

Discussion

- Prognostic factos in feline oral SCC Munday
  - Maxillary location: longer survival time
  - Lymph node or distant metastasis: MST 24 days
  - No metastasis: 90 days
  - Few studies determine whether the histological grade is prognostic

Discussion

- In this case, cytological features suggest that SCC invades the regional bone
- Is this feature helpful in management of the clinical case?
  - Need for radiographic evaluation?
  - Prognostic considerations?

Cell-in-cell events

- Cannibalism:
  - The outer cell engulfs the inner cell

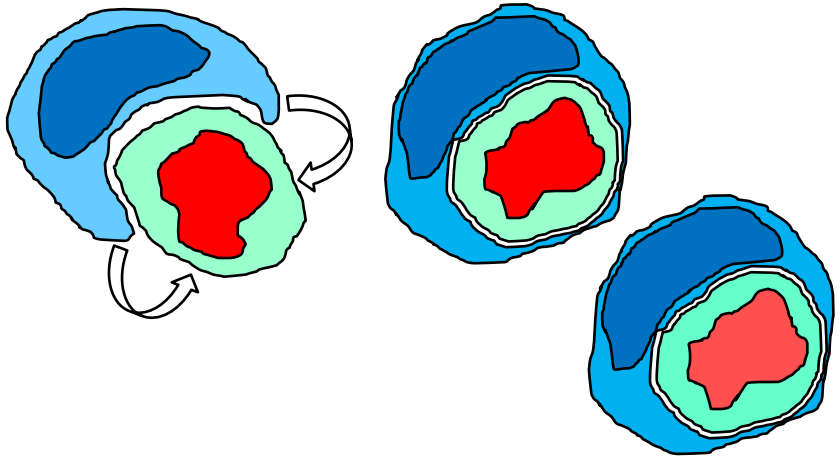

- Entosis:
  - One cell of the same phenotype invades another

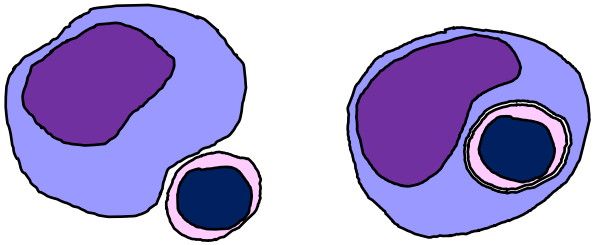

- Emperipolesis:
  - Heterotypic cells transit other cell

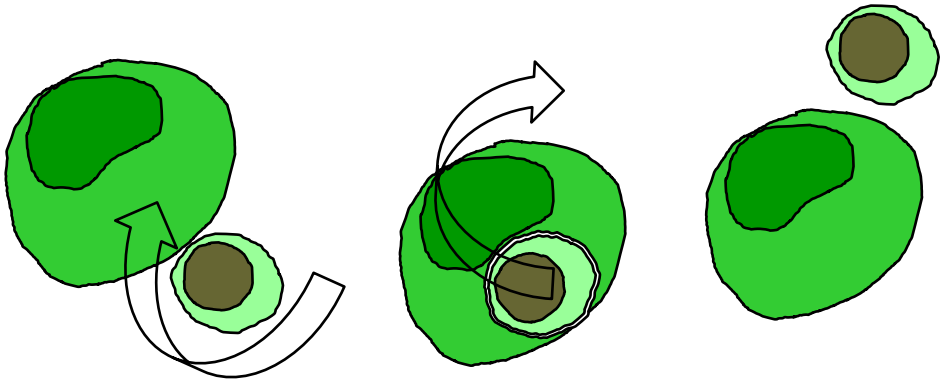

Cell-in-cell events

- Enclysis:
  - Cell-in-cell formation in a manner similar to pinocytosis, but so far is considered specific to hepatocytes engulfing CD4+ T lymphocytes

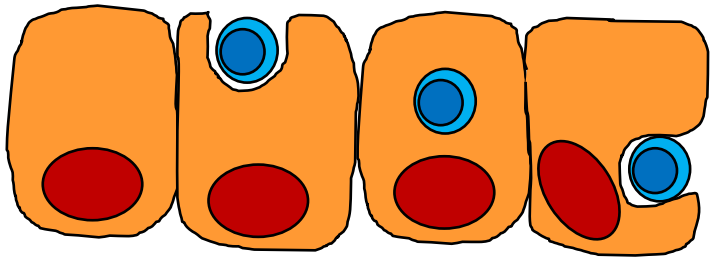

- Phagoptosis:
  - A form of cell death in which a macrophage engulf viable cells (not dead or dying cells)



Discussion

- Emperipolesis. What's new??
- In human being, in cancers such as oral squamous cell carcinoma, **cell-in-cell events have been linked to aggressiveness, metastasis, and therapeutic resistance** (Siquara da Rocha et al, Front Oncol, 2022)
- Should emperipolesis be related with biological behaviour of a neoplasia?
- Starting point for future studies?

Case #2

- 14-year-old, neutered female, Beagle dog
- Clitoral mass

- FNCS of the lesion
- MGG stain

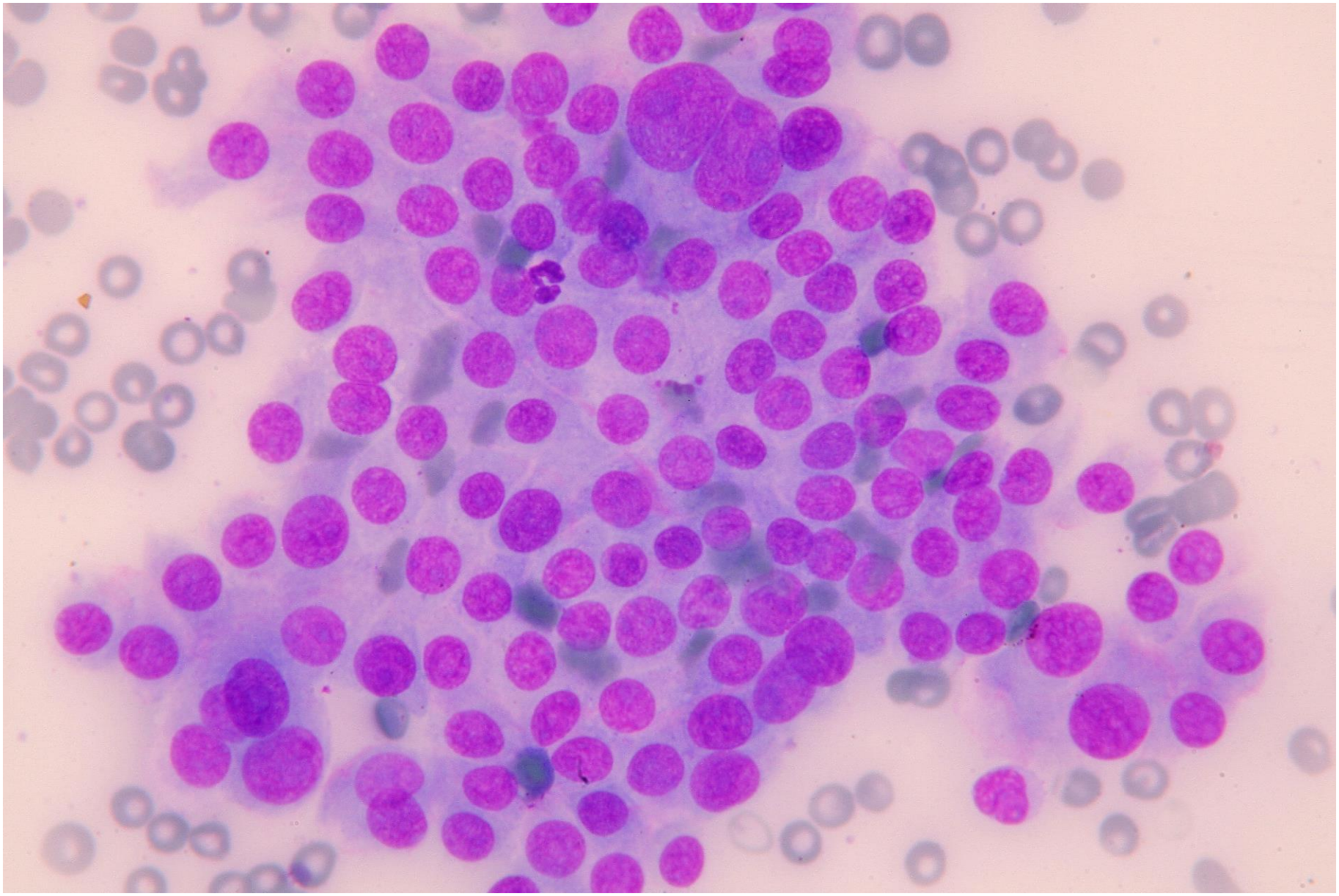

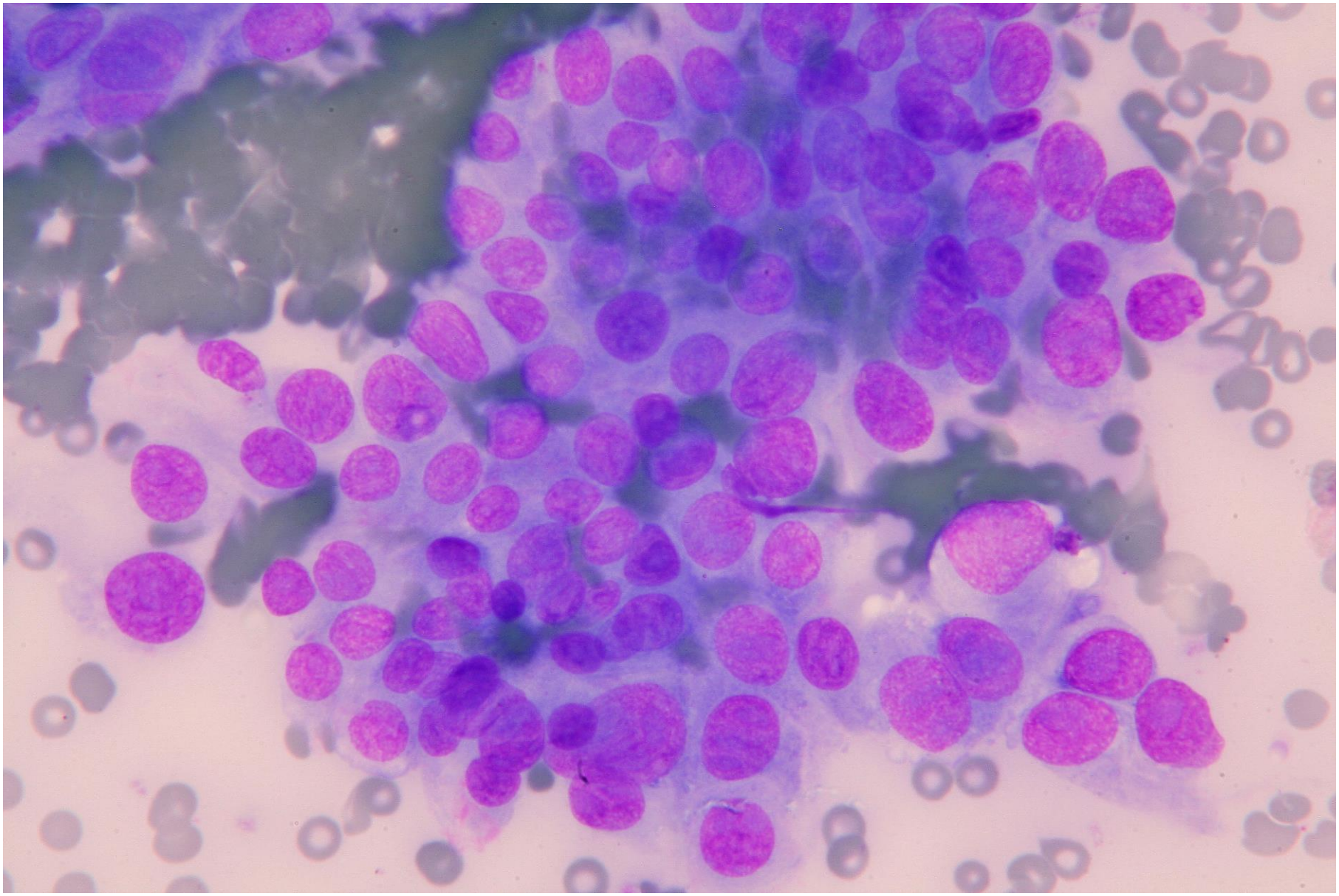

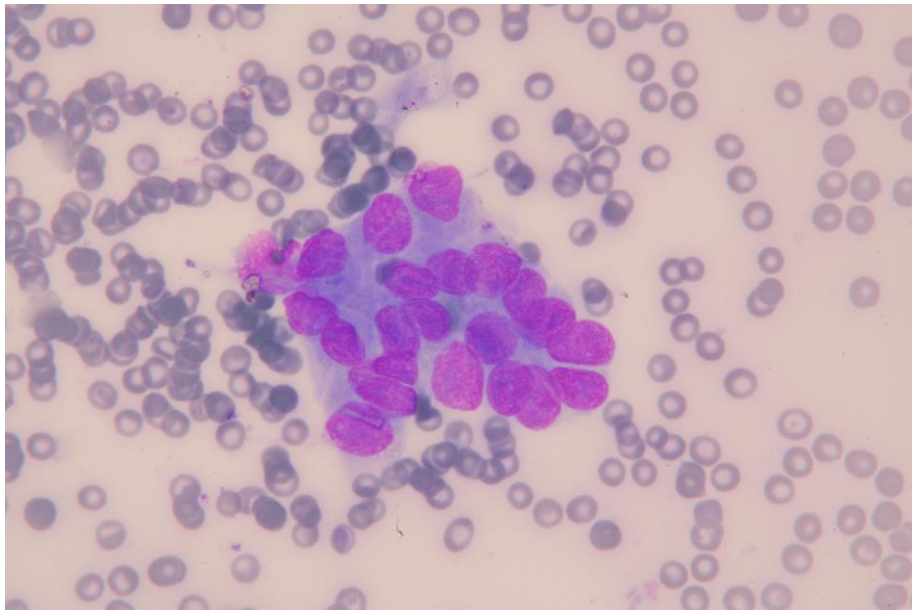

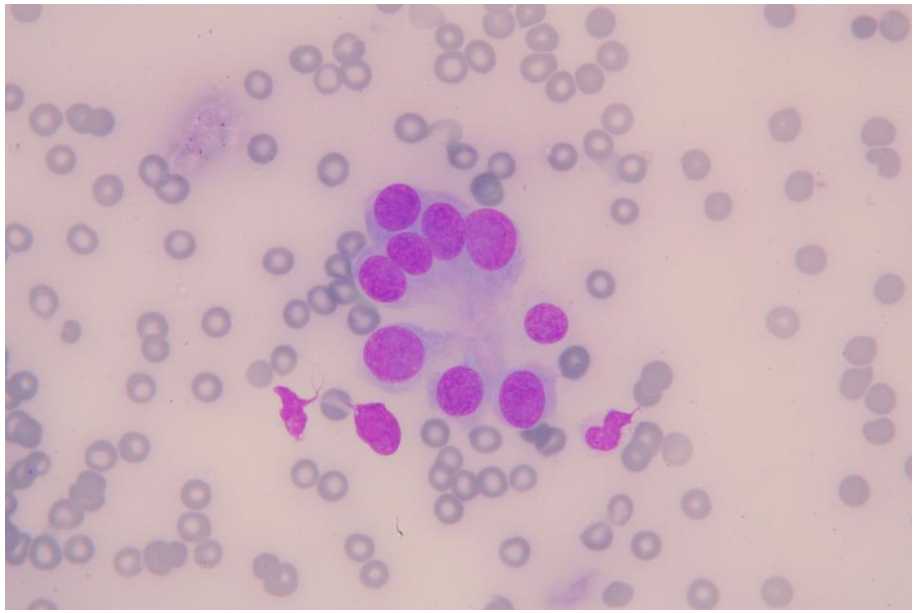

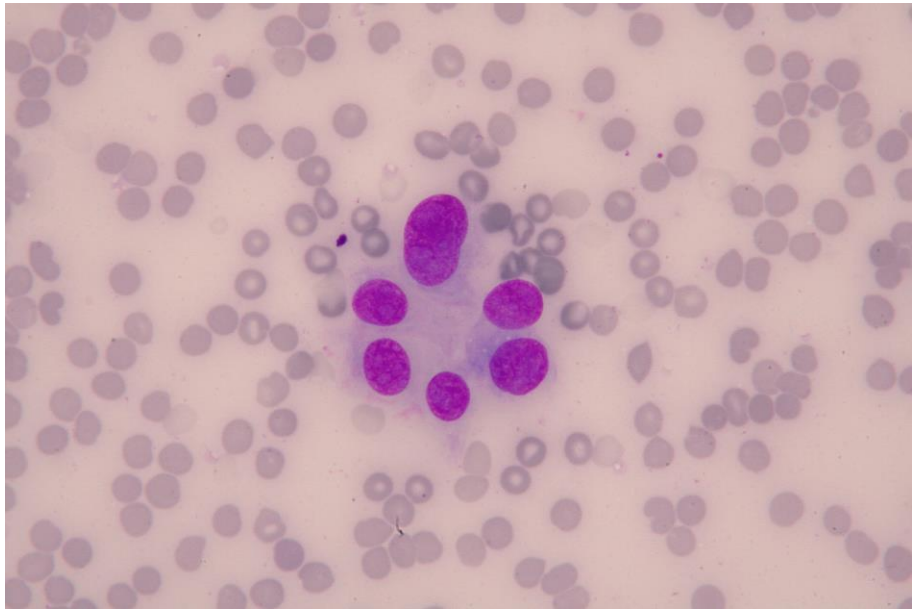

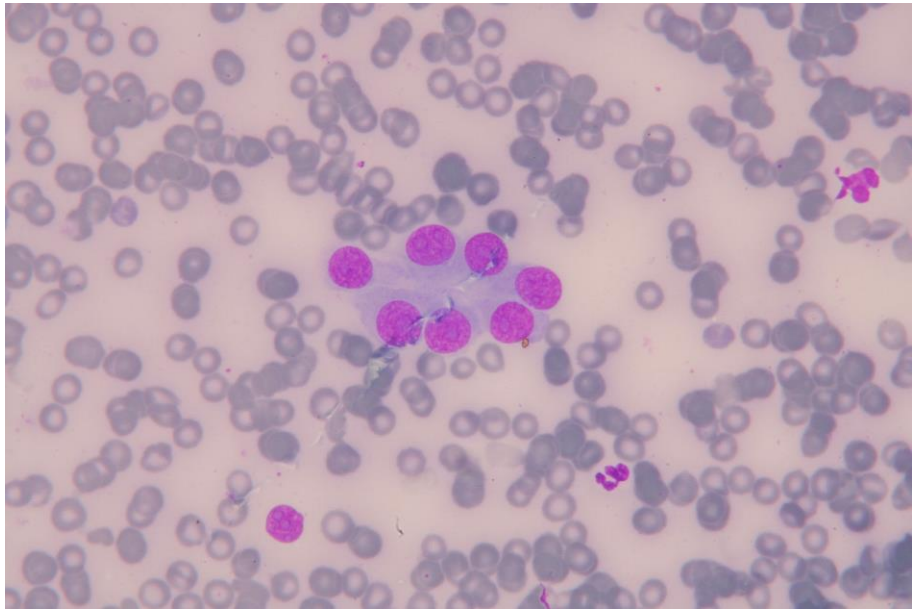

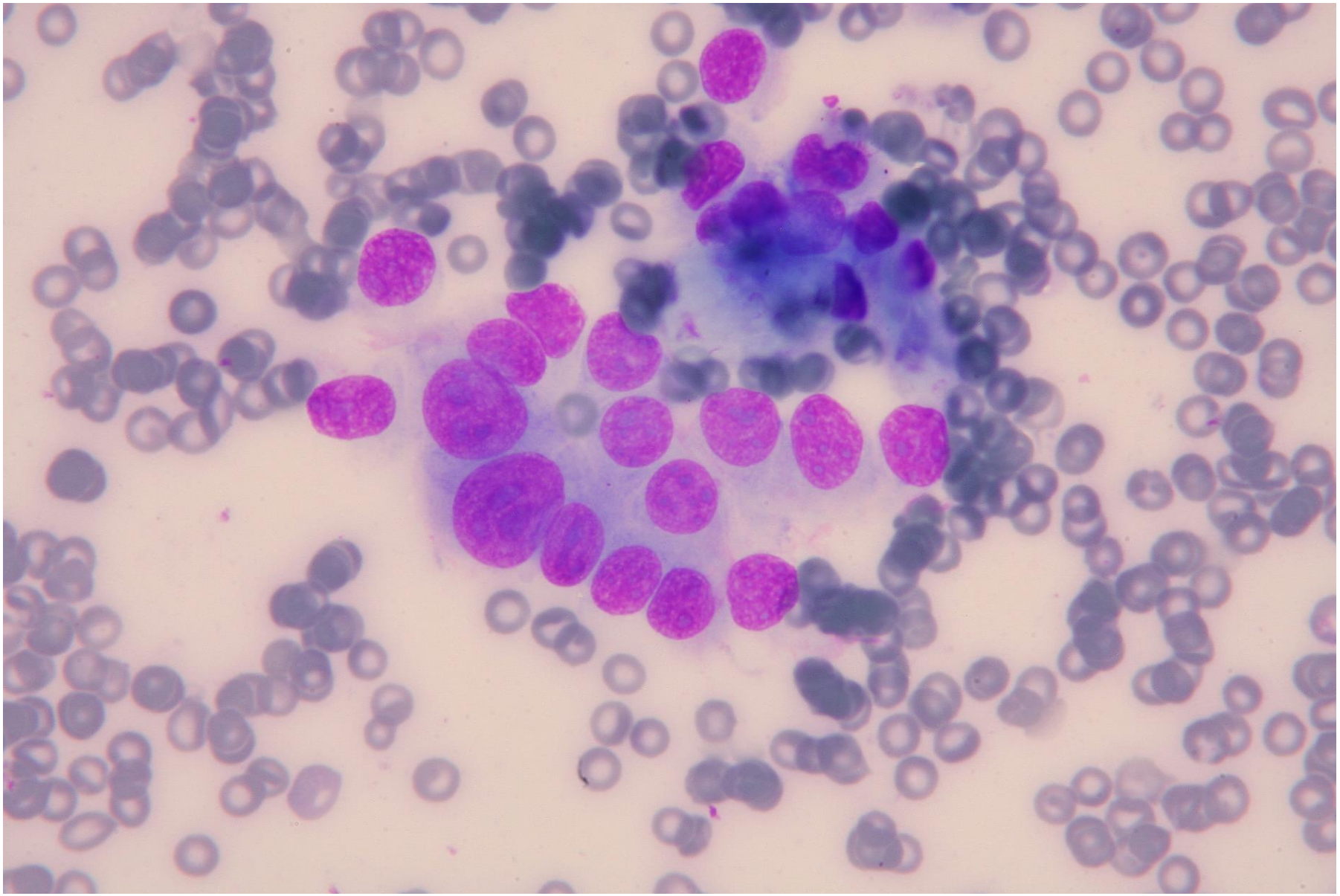

Cytologic findings

- Epithelial cells with cuboidal to columnar indistinct cytoplasm
- Marked anisokaryosis and anisocytosis

- Arrangement in large irregular, bidimensional sheets
- Presence of microacinar structures
- Presence of brief palisade arrangement

Diagnosis

- Cytologic diagnosis
  - Malignant epithelial neoplasia of apocrine cell origin (possibly clitoral carcinoma)
- Histologic diagnosis
  - Apocrine, infiltrative carcinoma

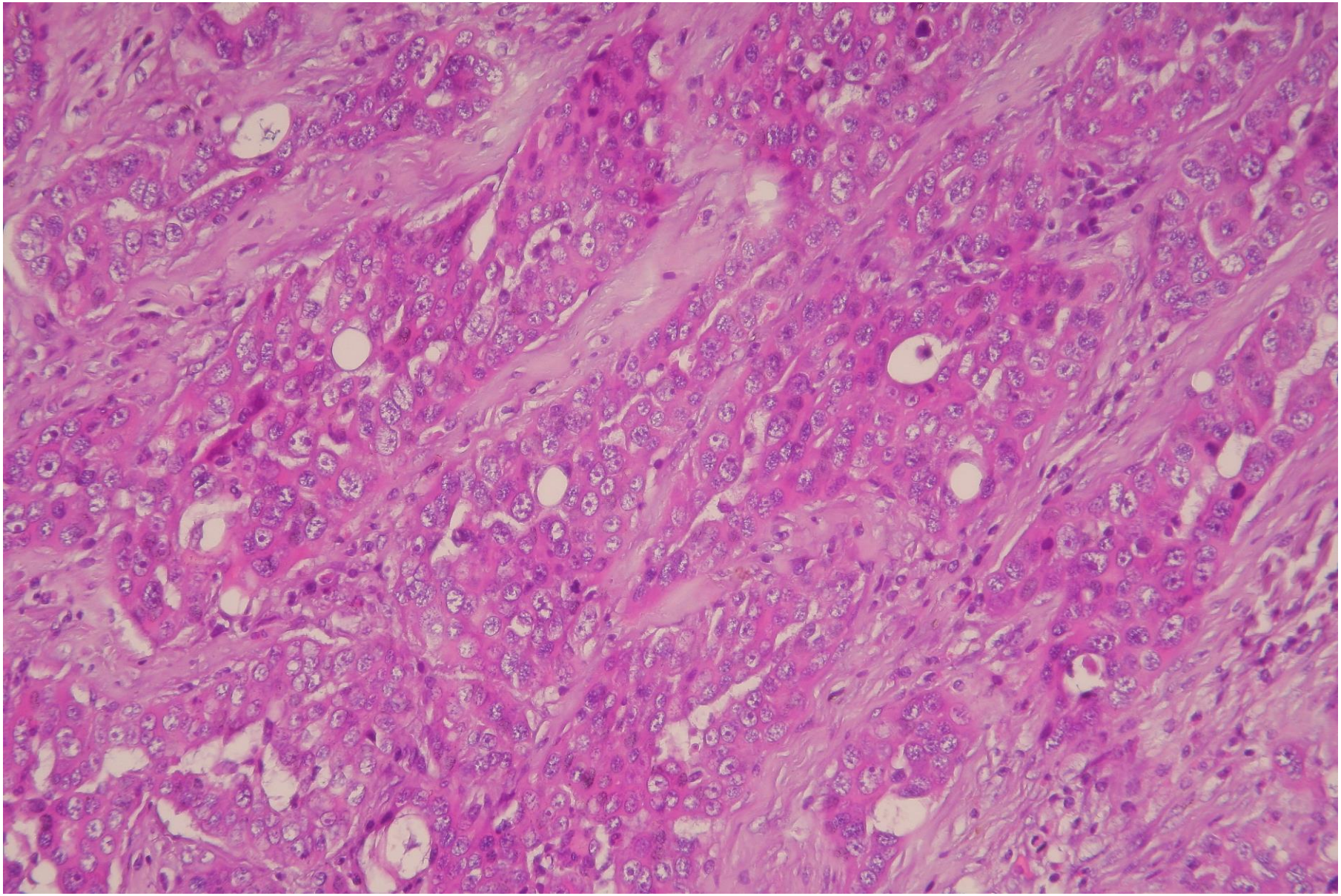

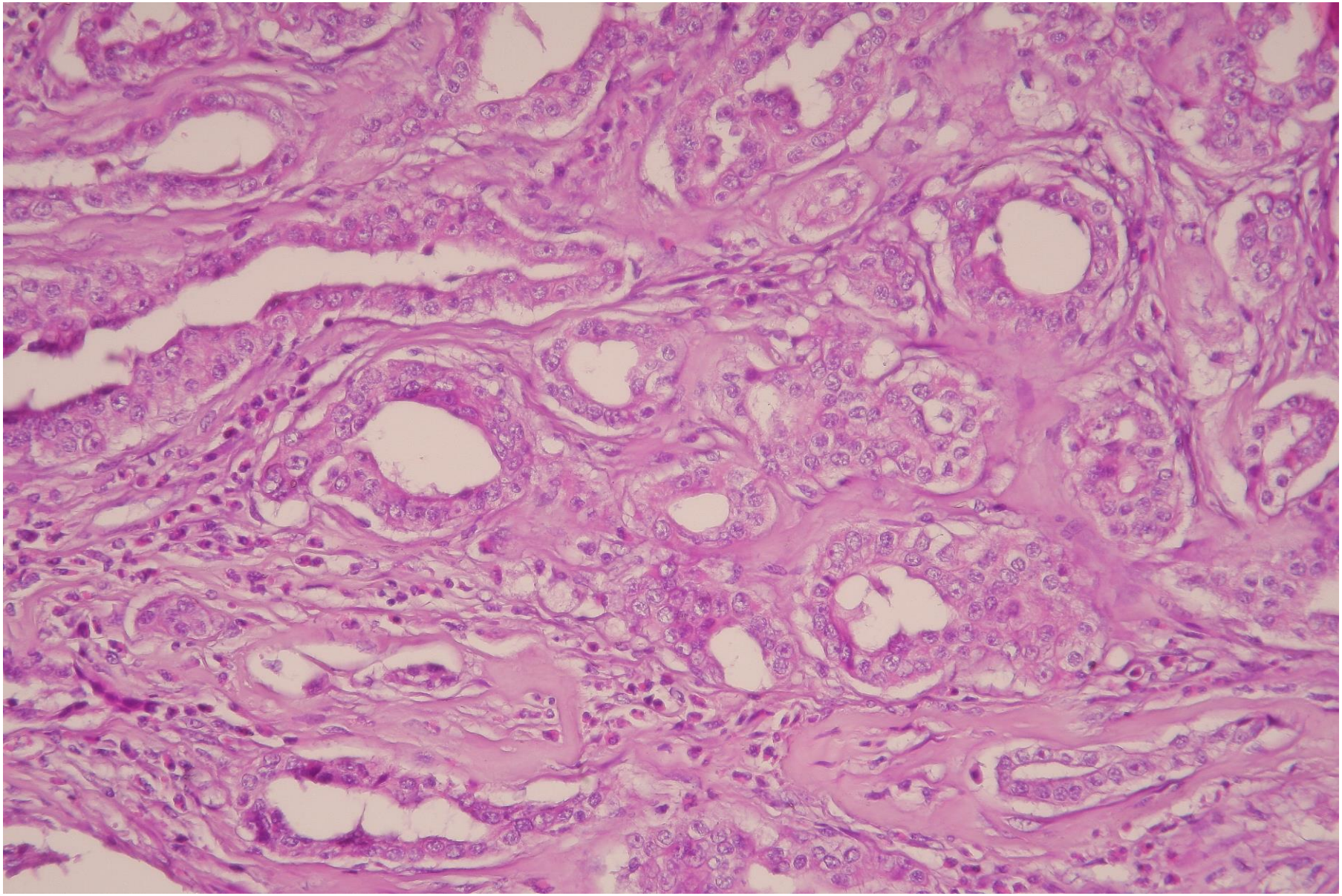

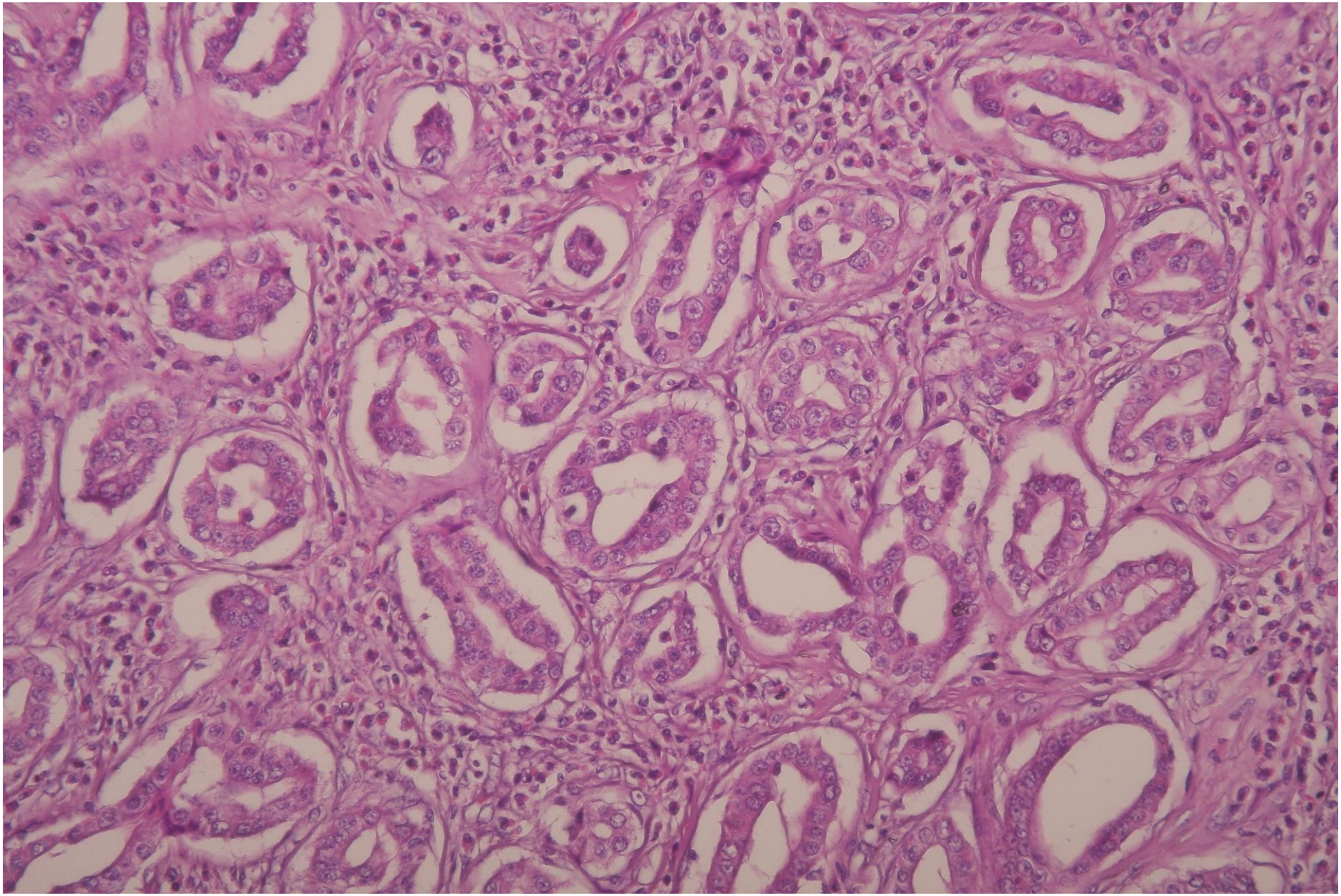

Histology

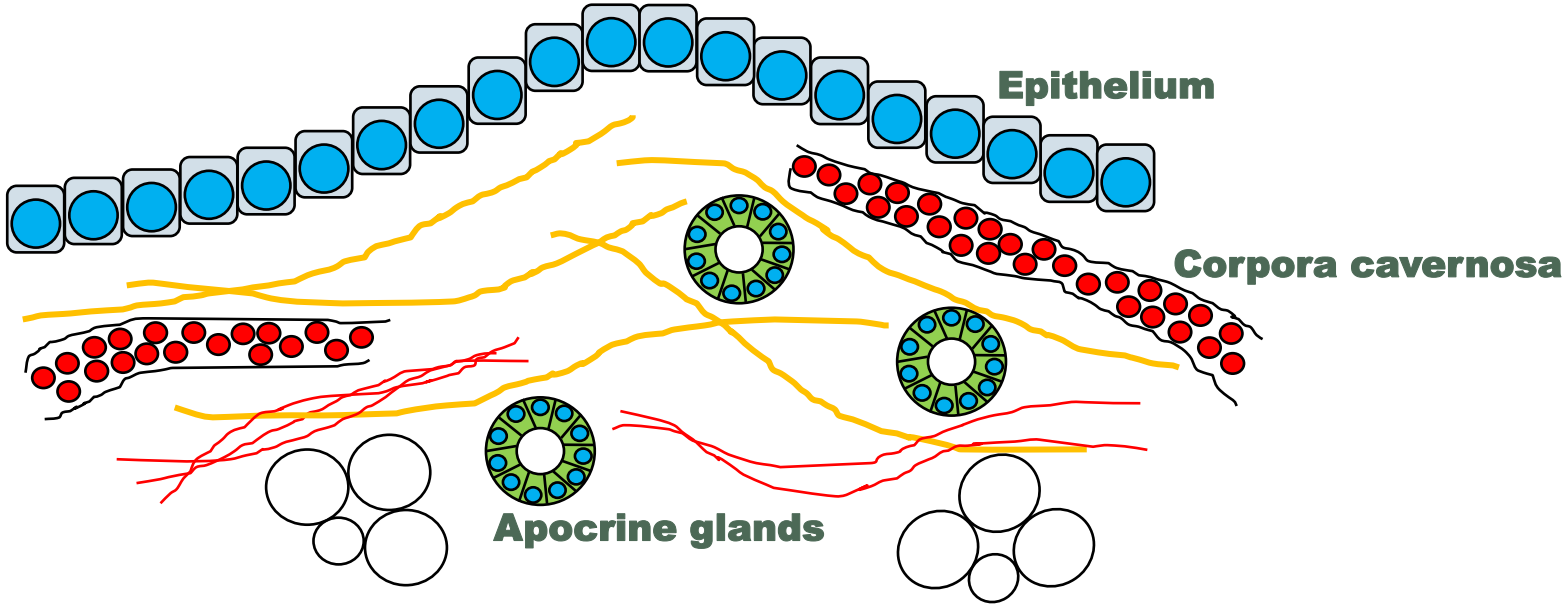

Discussion

Canine Clitoral Carcinoma: A Clinical, Cytologic, Histopathologic, Immunohistochemical, and Ultrastructural Study

Veterinary Pathology
2018, Vol. 55(4) 501-509
© The Author(s) 2018
Reprints and permission:
sagepub.com/journalsPermissions.nav
DOI: 10.1177/0300985818759772
journals.sagepub.com/home/vet

Ranieri Verin[1], Francesco Cian[2], Jennifer Stewart[3], Diana Binanti[4], Amy L. MacNeill[5], Martina Piviani[6], Paola Monti[7], Gianna Baroni[8], Sophie Le Calvez[9], Timothy J. Scase[10], and Riccardo Finotello[6]

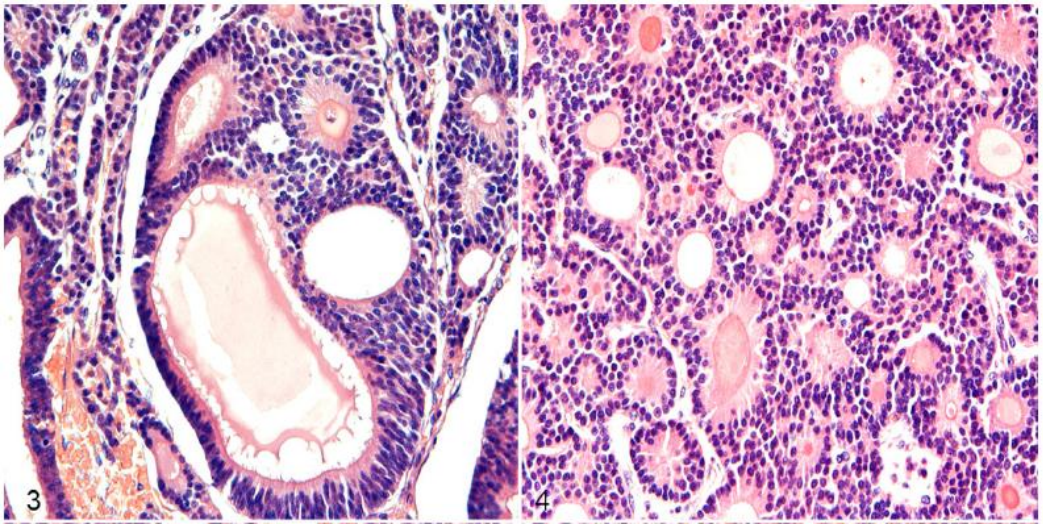

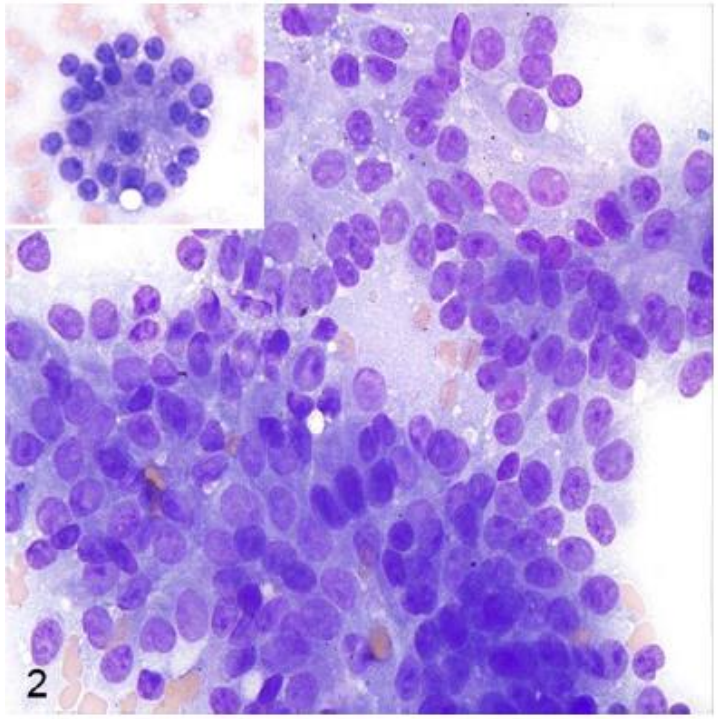

Discussion

Our case

- Very marked anisocytosis and anisokaryosis
- Acinar arrangement
- No naked nuclei
- Tubular structures

Published cases

- Anisokaryosis mild to moderate
- Rosette-like arrangement
- Naked nuclei
- Tubular, rosette-type and solid pattern

Discussion

- Apocrine carcinoma vs clitoral carcinoma
- Need for IHC, not here performed
- Possible that from apocrine gland of clitoris a carcinoma similar to others cutaneous sites may arise

Case #3

- 6-year-old, DSH, male cat
- Cutaneous nodule in axillary region, cystic in appearance (liquid content)

- FNCS of the lesion
- MGG stain

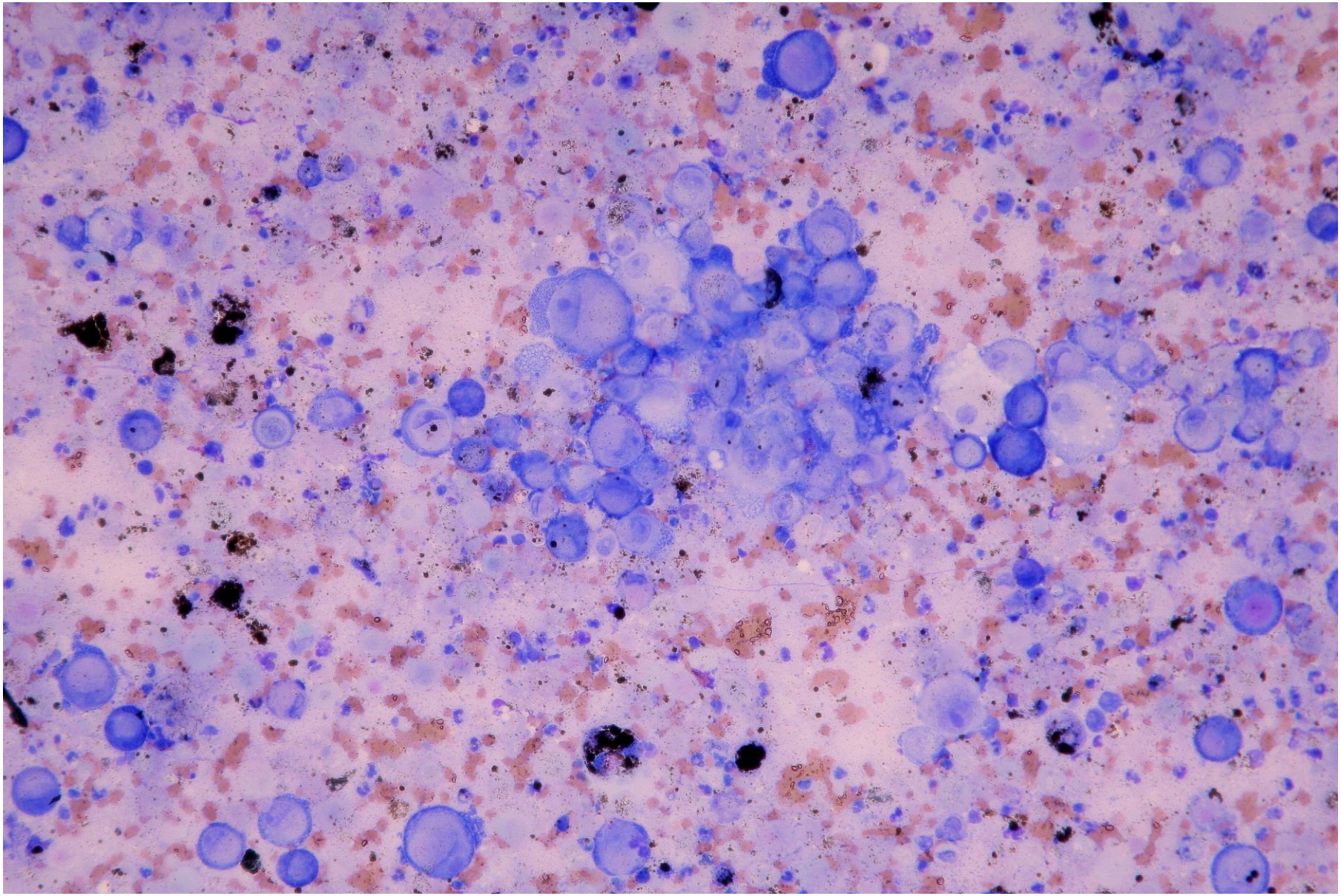

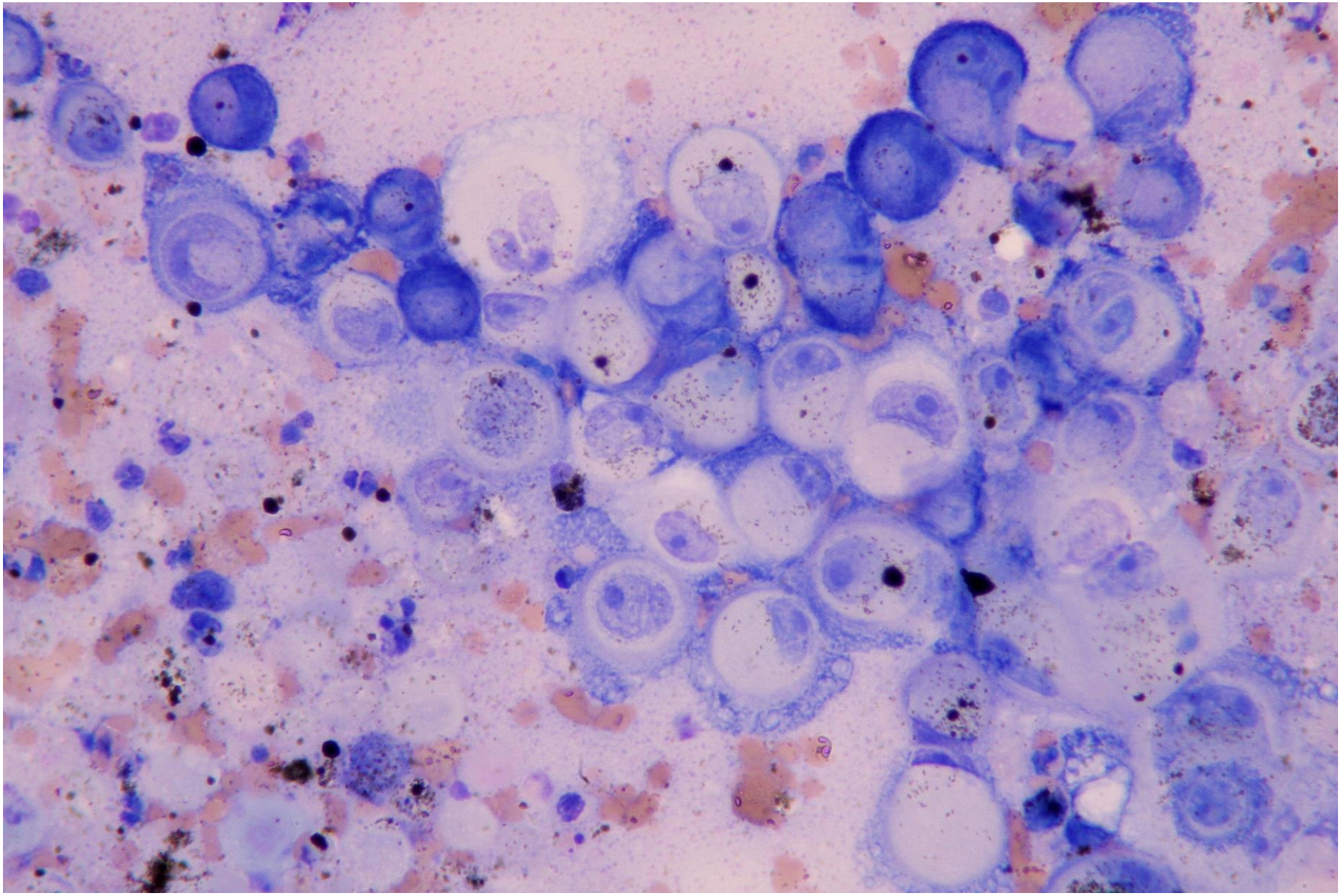

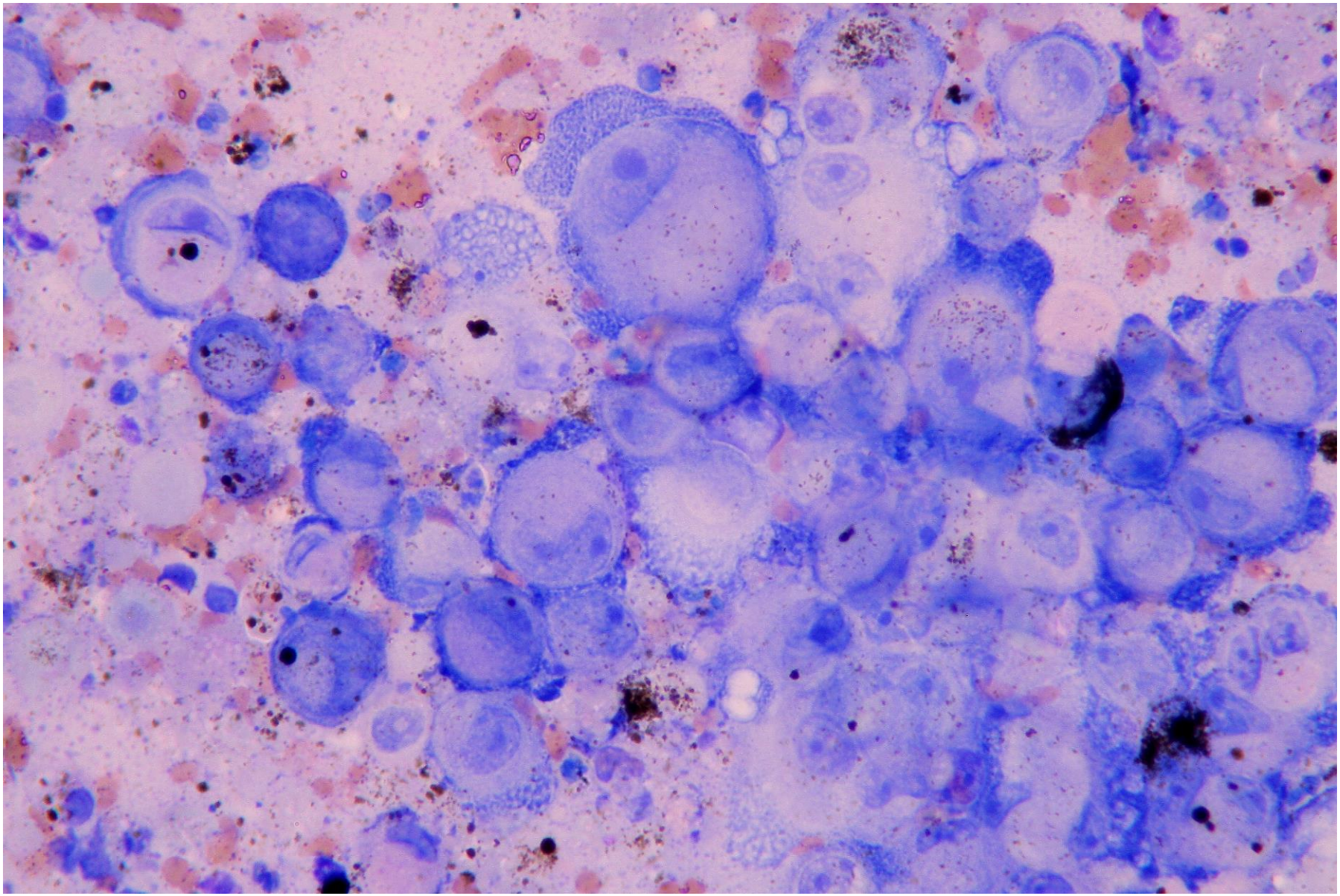

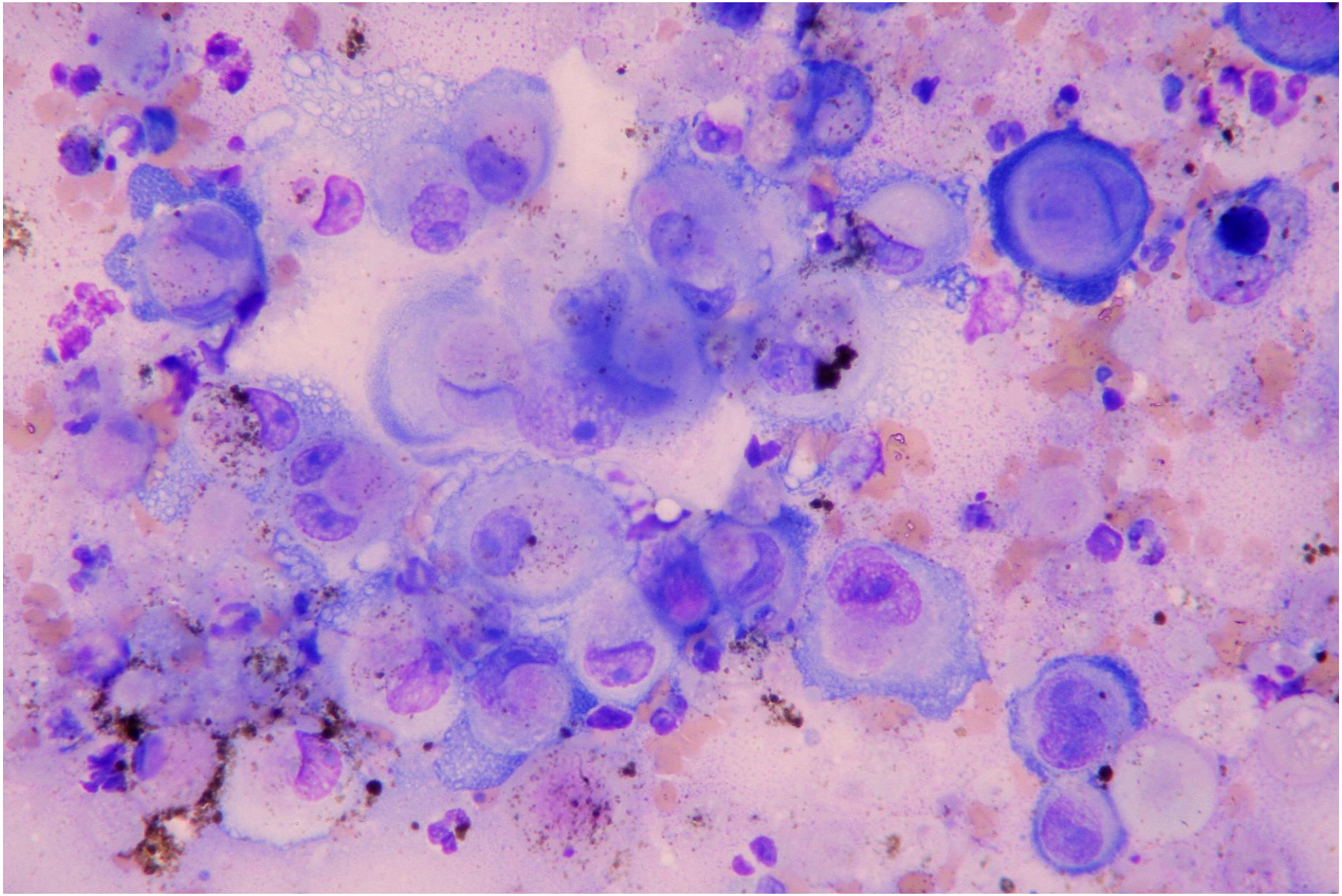

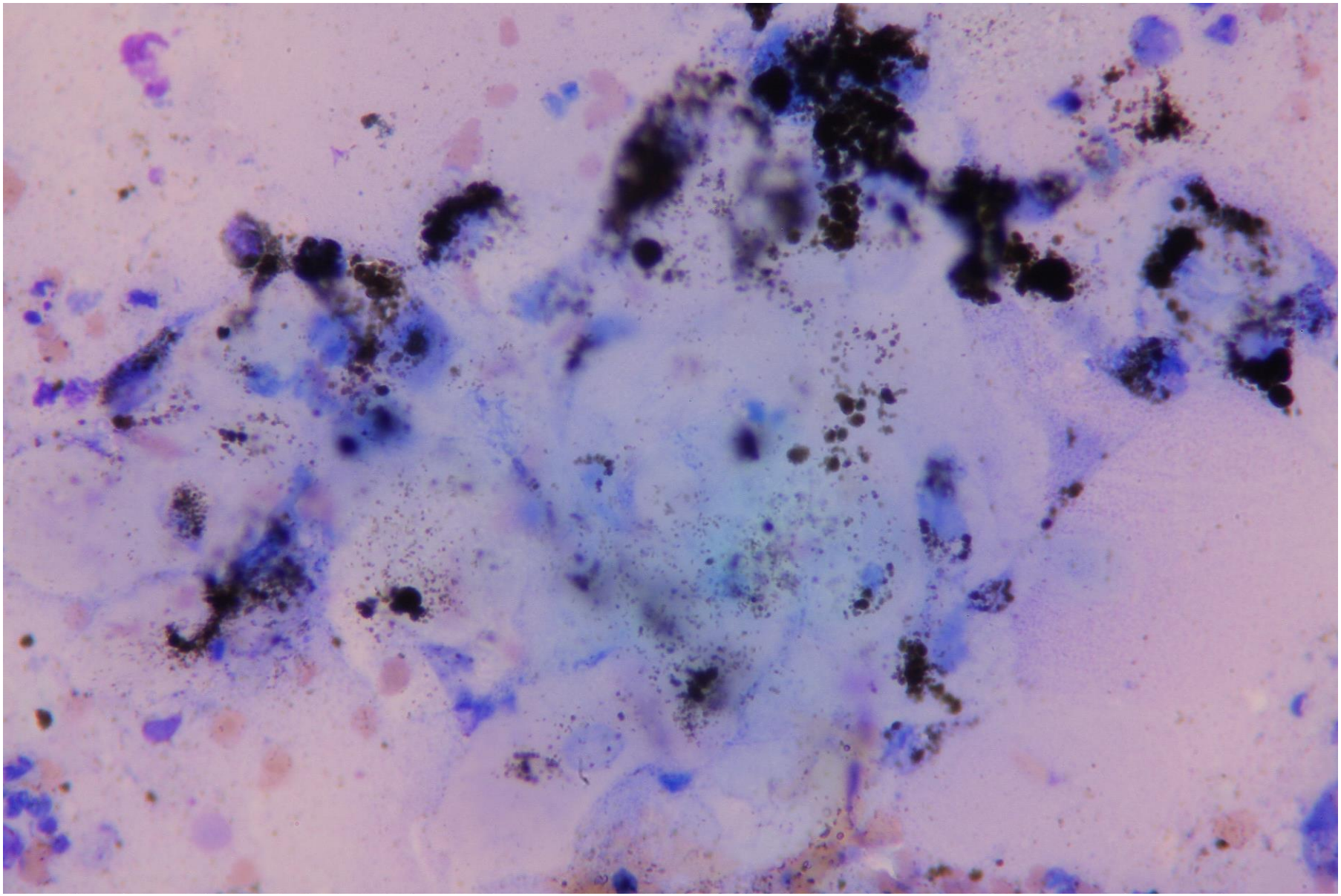

Cytologic findings

- Poor quality of sample (weak staining)
- Round cells of epithelial origin
  - Pigmented cytoplasm, large achromatic globules
  - Irregular borders
  - Mild anisokaryosis and anisocytosis
- Arrangement in dischoesive sheets, sometimes with psuedo-papillary arrangement
- Presence of pigmented keratin

Diagnosis

- Cytologic diagnosis
  - Pigmented neoplasia of adnexal origin
  - More likely apocrine origin
- Histologic diagnosis
  - Trichoblastoma with cystic spaces

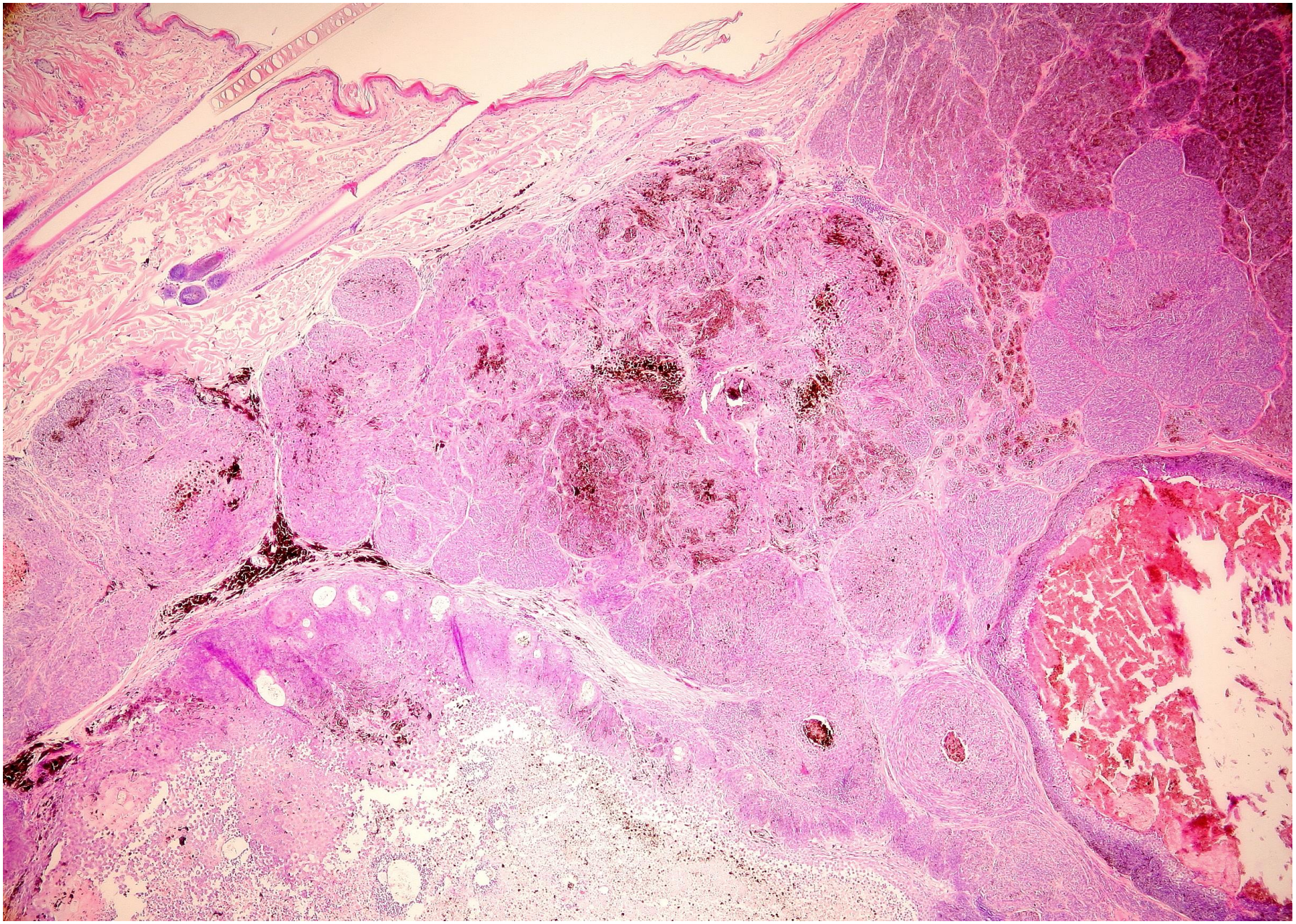

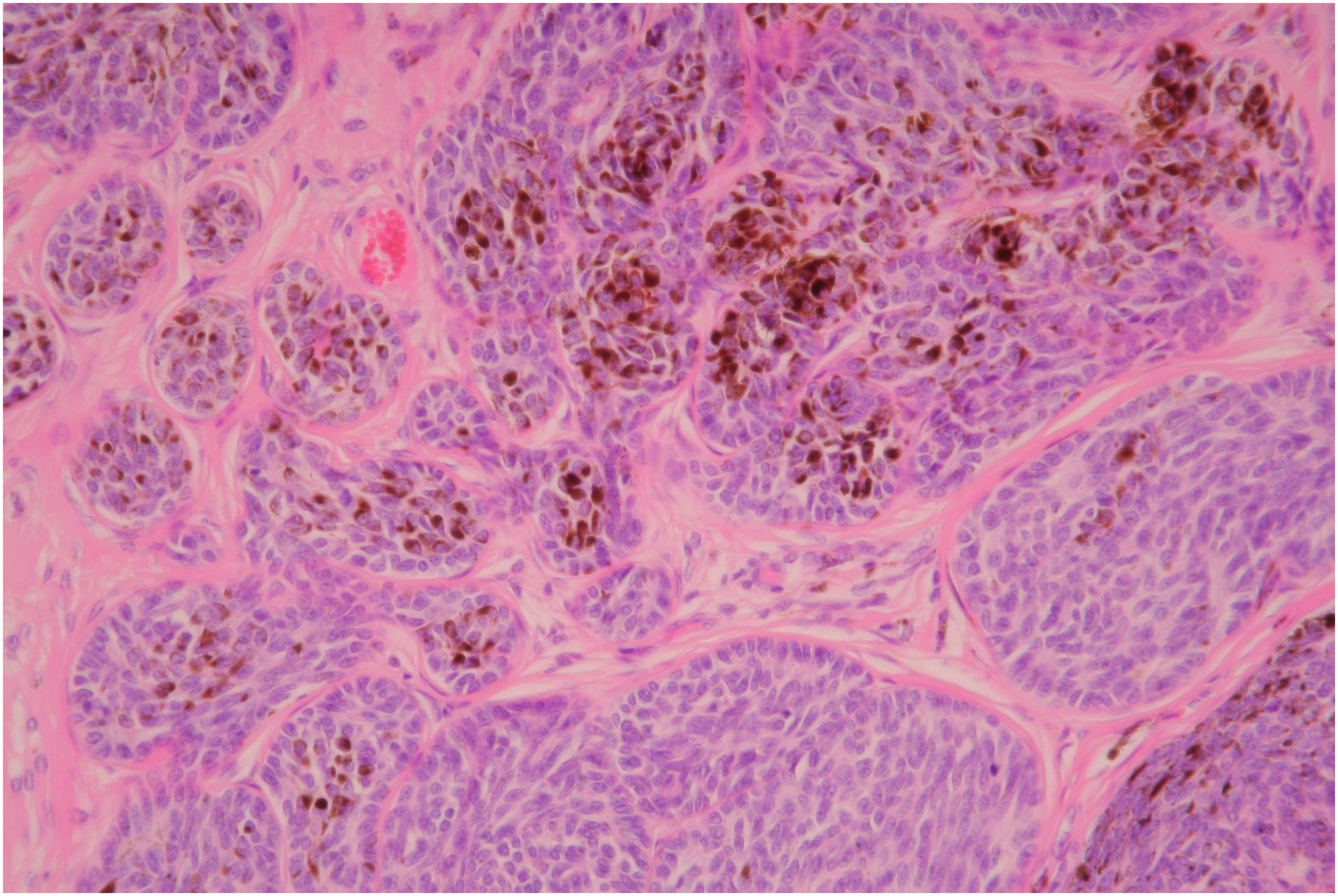

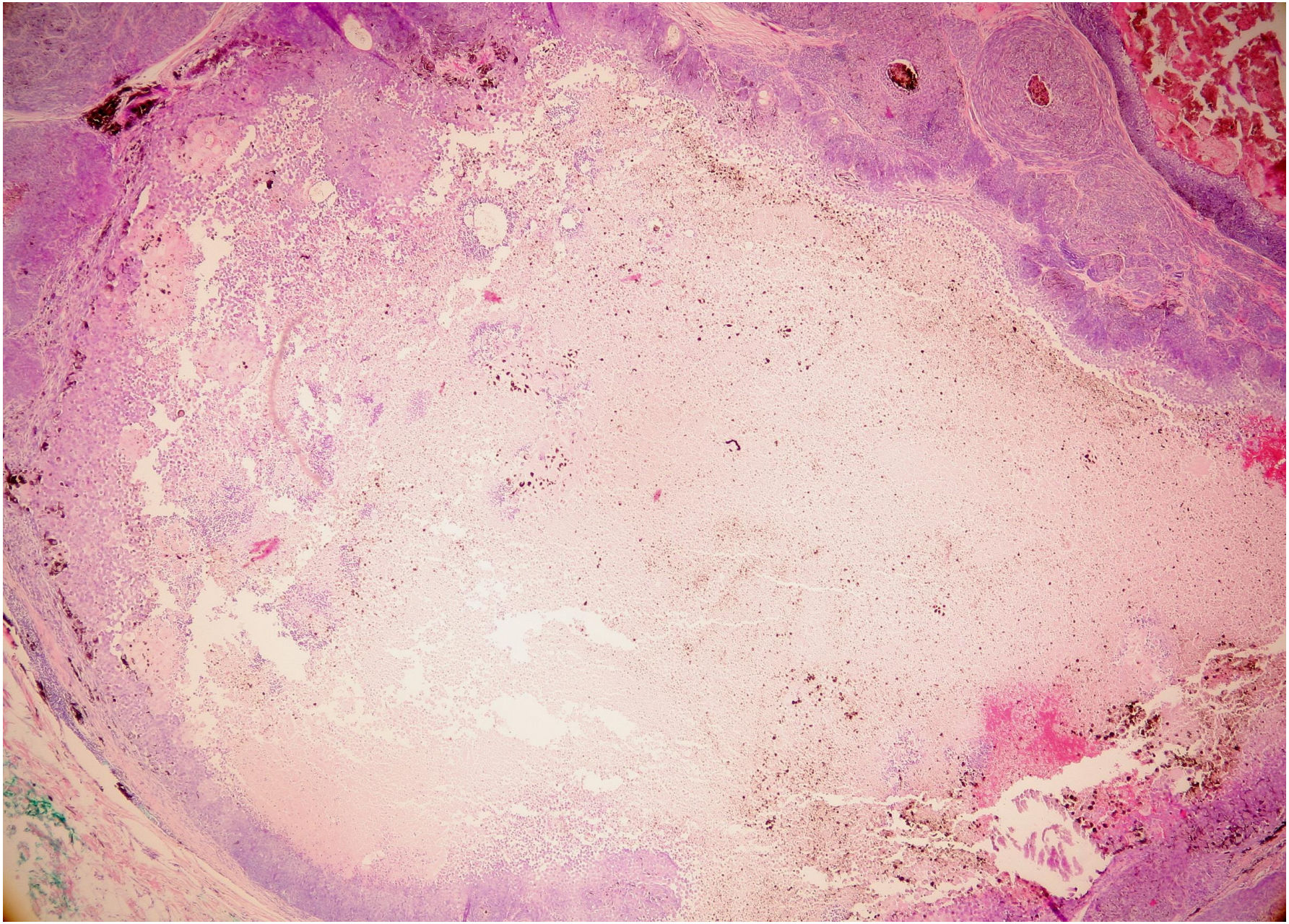

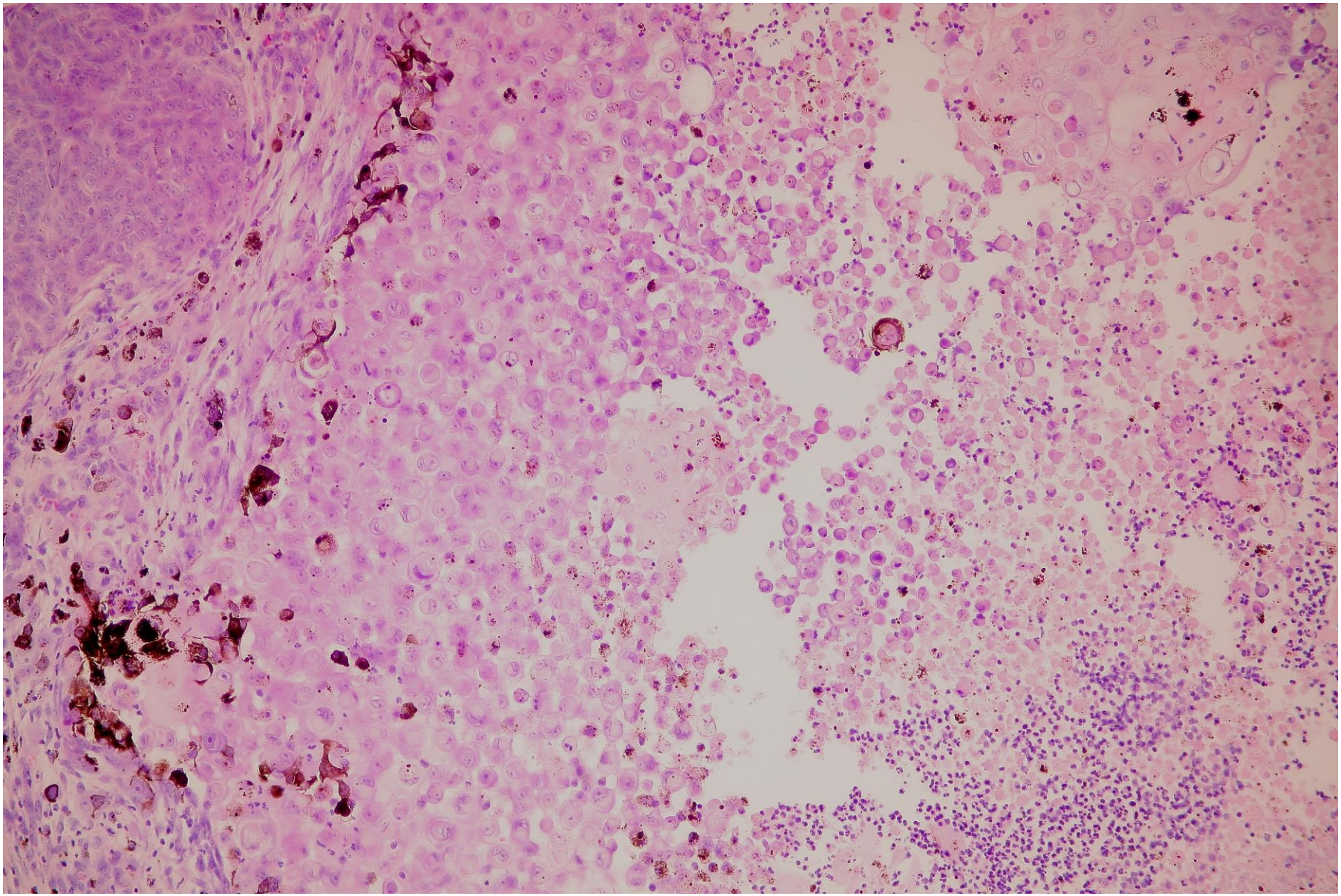

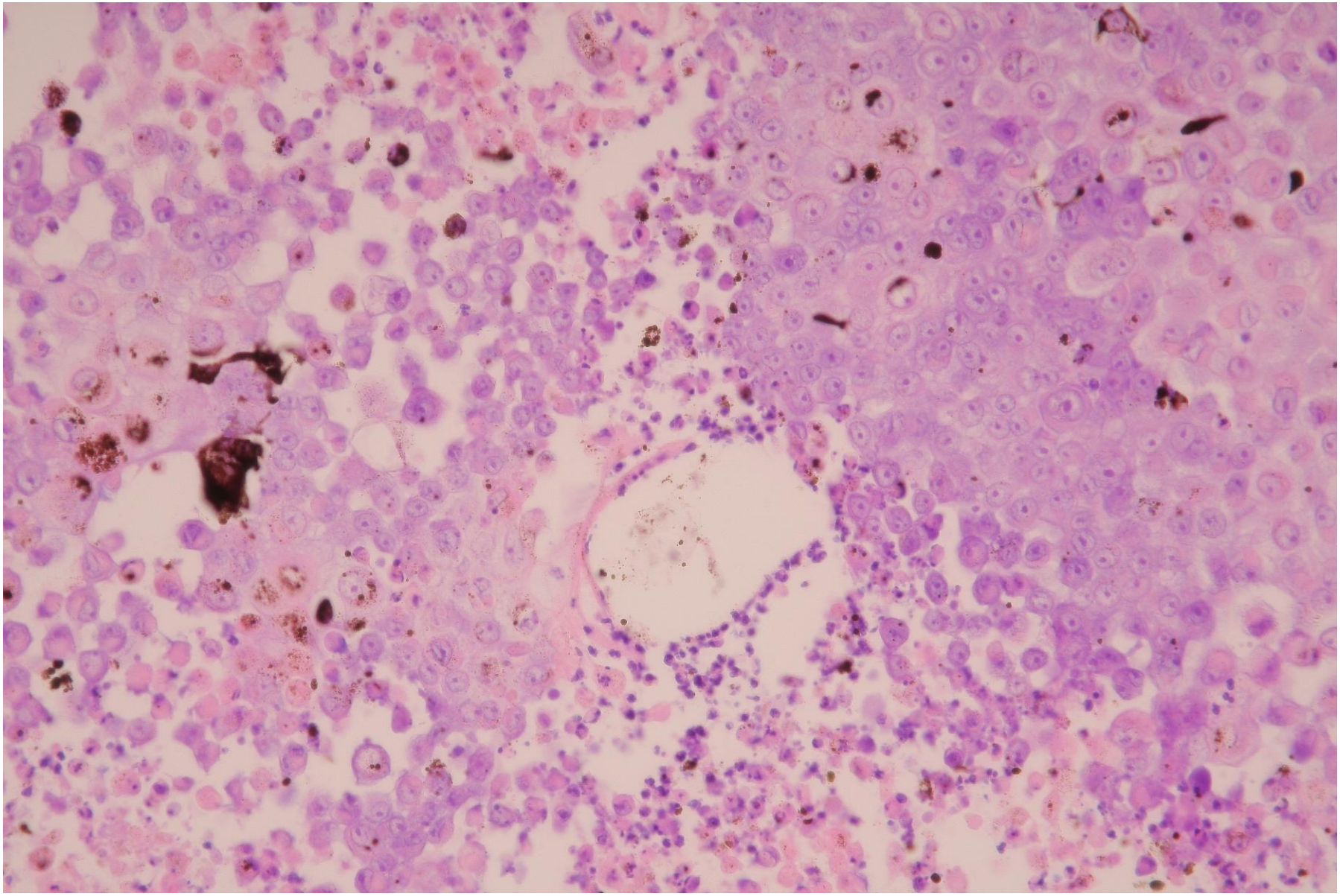

Discussion

- Unusual presentation of a trichoblastoma
  - Due to the fact that the cystic area has been sampled
- The morphological features of the cells depend from the transformation that occurs in a cystic space
  - Similar to cells when exfoliate in an effusion
  - Loss of contact
  - Irregular outline of the cytoplasm
- Transformation make the cytological diagnosis almost impossible

Discussion

- Trichoblastoma (according with TL Gross, 2005)
  - Ribbon type trichoblastoma
  - **Trichoblastoma with outer root sheath differentiation**
  - Trabecular type trichoblastoma
  - Spindle cell type trichoblastoma
  - Granular cell type trichoblastoma

Ribbon type

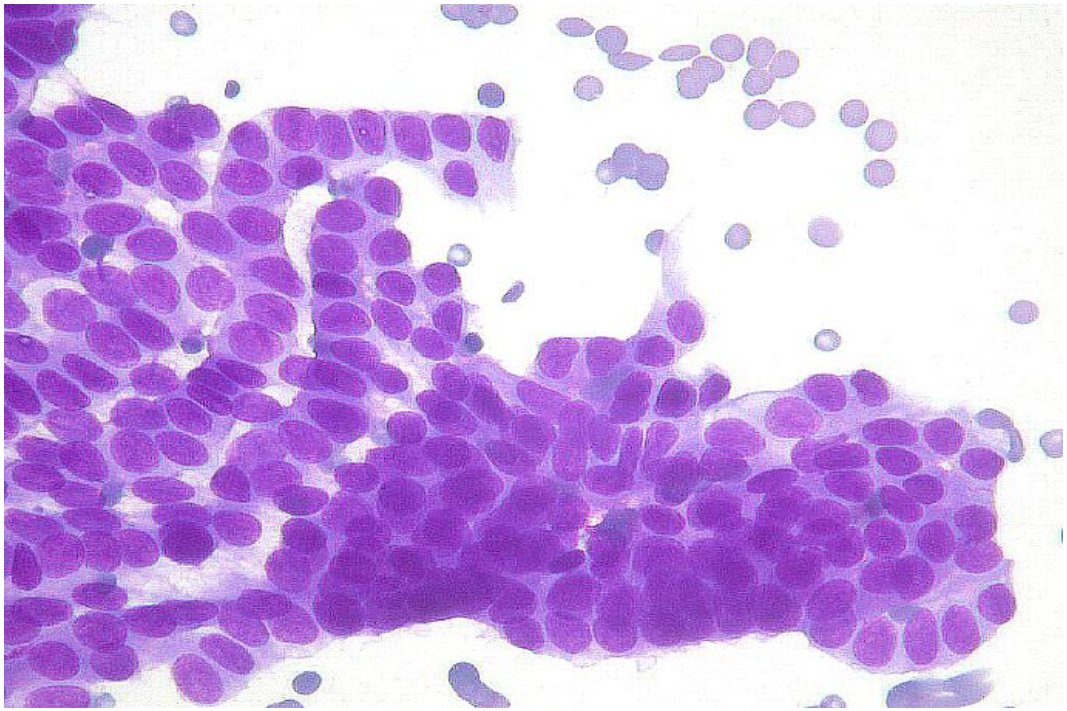

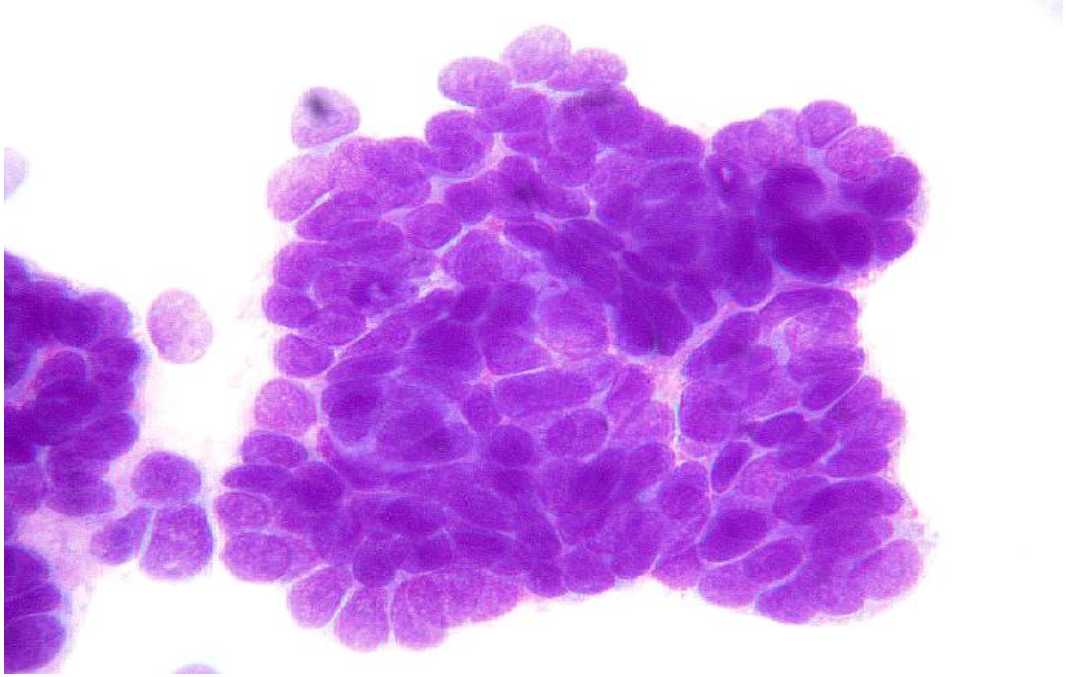

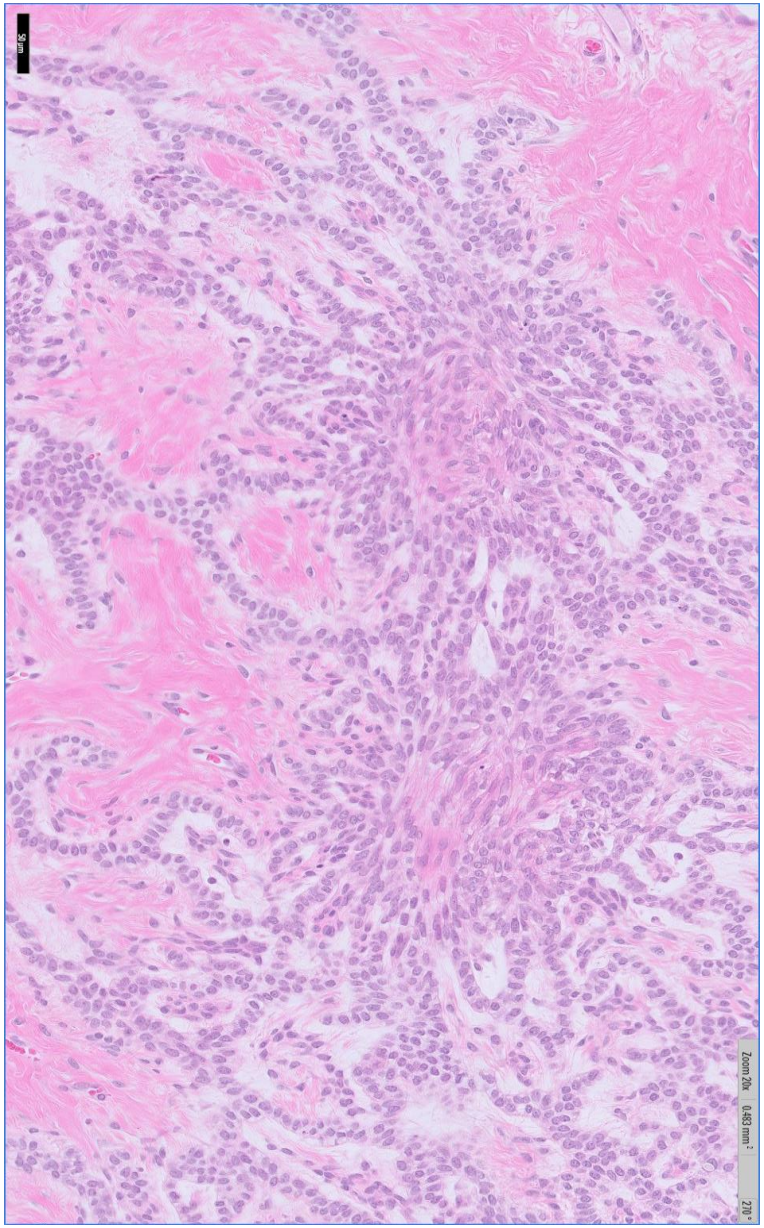

Spindle cell type

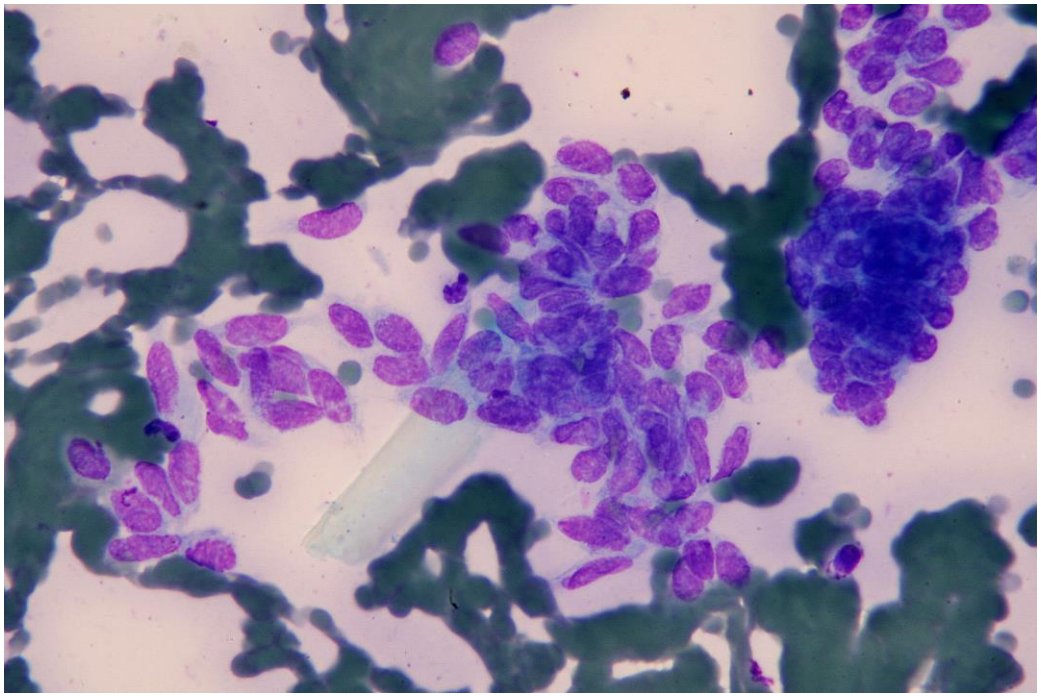

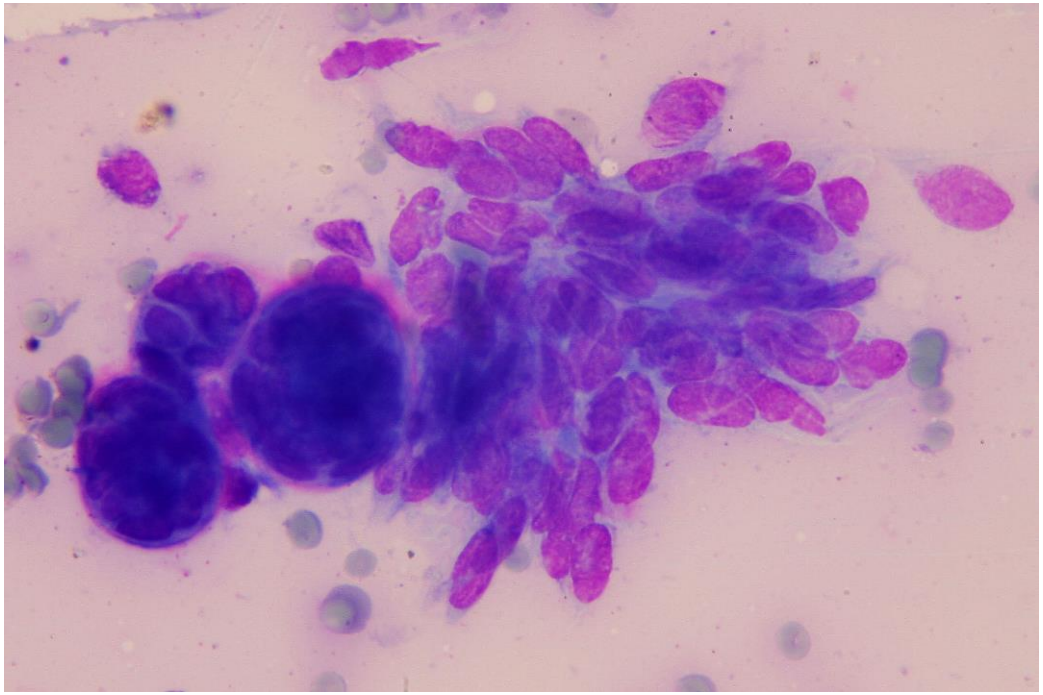

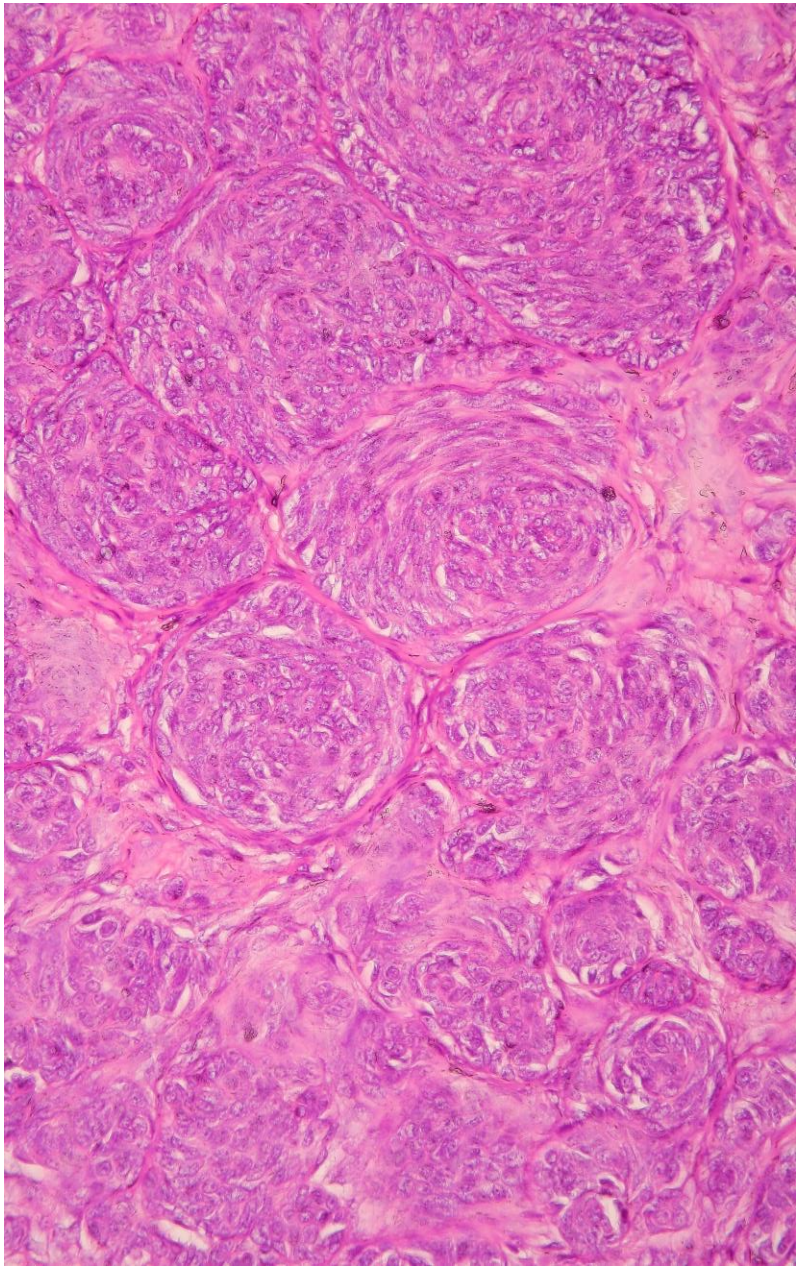

Granular cell type

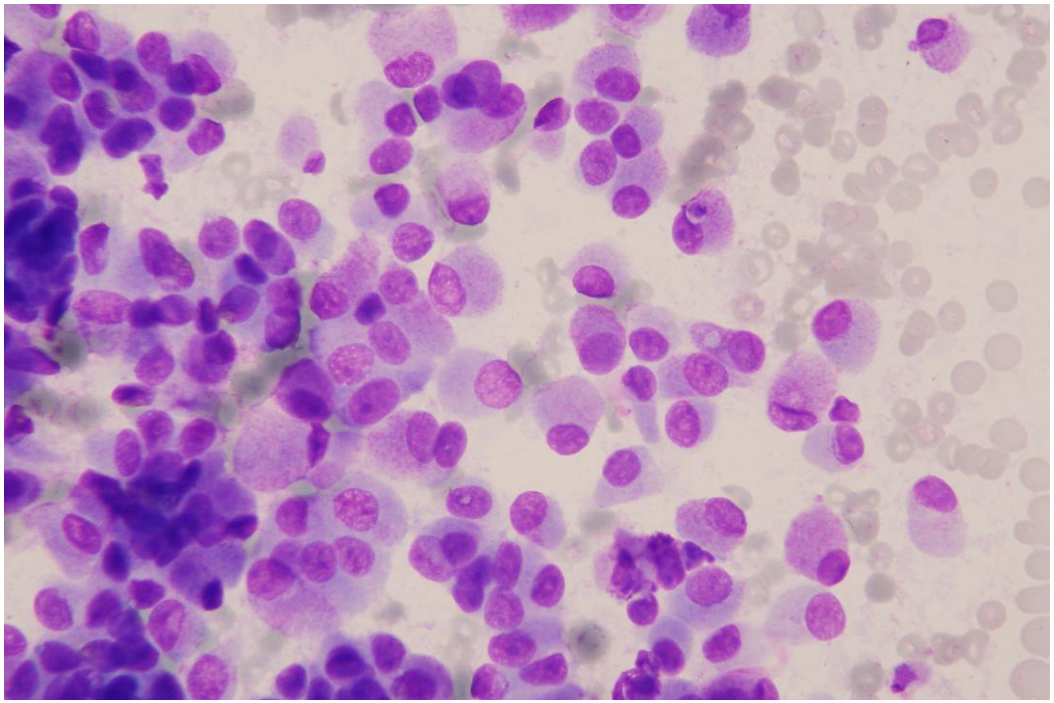

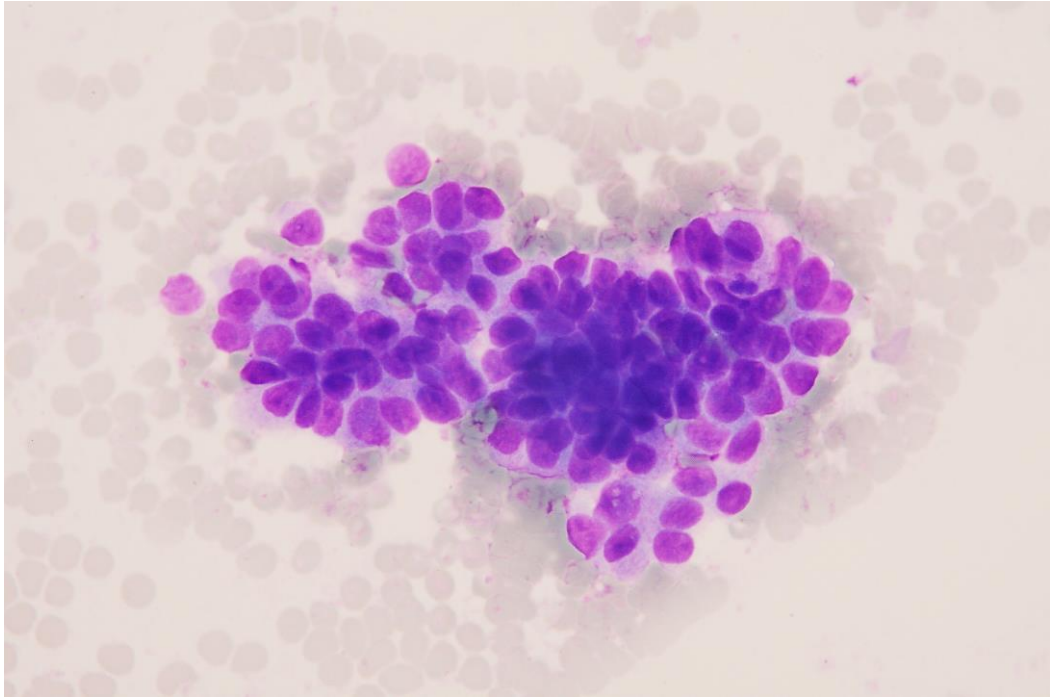

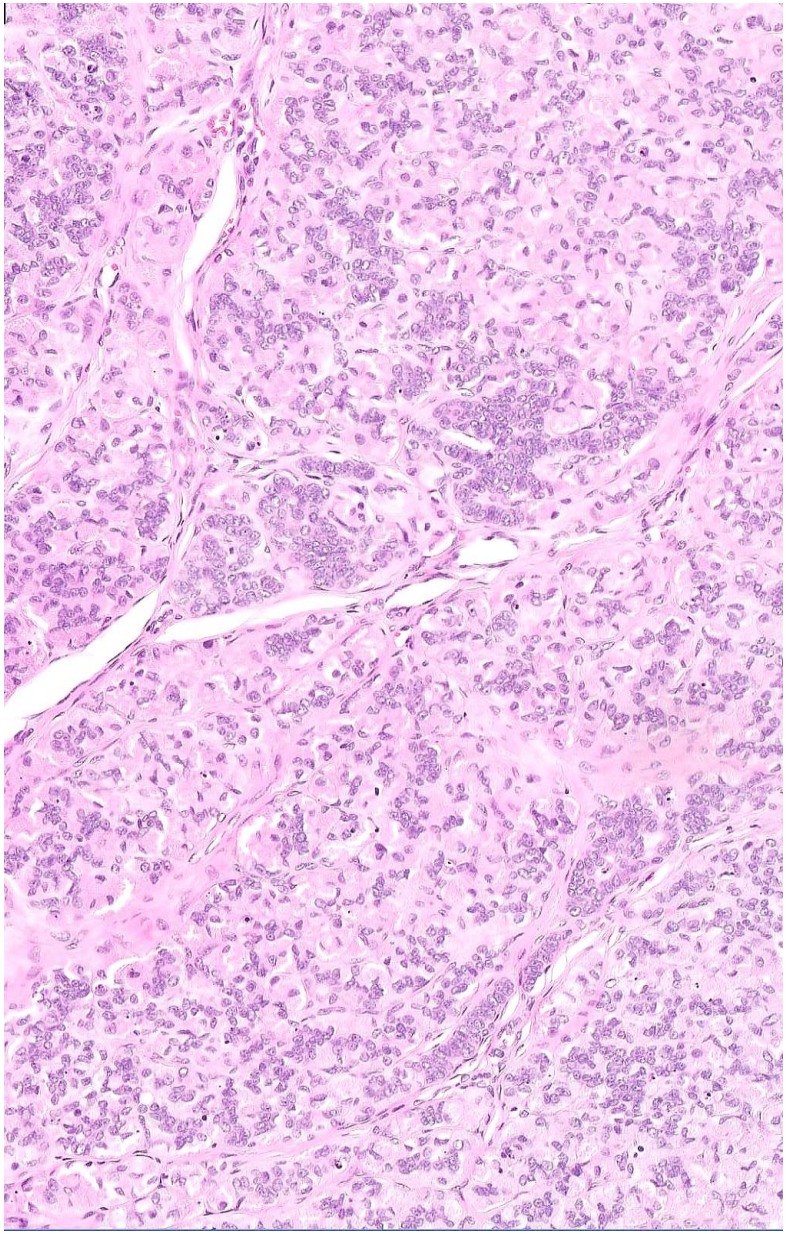

Discussion

- Trichoblastoma with outer root sheath differentiation (according with TL Gross):
  - “lesions are well circumscribed with multilobular and trabecular architecture and large areas of cystic degeneration”
  - “the cystic zones appear to be a result of apoptosis, acantholysis and keratinocyte drop-out”
  - “the trichoblast are frequently melanized”
  - “the primary DD is apocrine ductular adenoma”

Case #4

- 9-month-old, male, French bulldog dog
- Icterus and liver failure

- FNCS of the liver
- MGG stain

CBC (automated count) and biochemistry

RBC	$6{,}91 \times 10^6$	5,70	7,90	**WBC**	**$12{,}5 \times 10^3$**	6	11	**PLT**	457×10^3	120	350
HGB	15,9 g/dl	12,0	18,0	**Neutrofili**	68 %	2,5	7,0	**MPV**	7,5 fL	7,9	12,3
HCT	47 %	37,0	55,0	**Linfociti**	30 %	1,3	5,5	**PDW**	%	10	27
MCV	68,1 fL	60,0	76,0	**Monociti**	2 %	0,06	0,25	**STIMA**	Ad		
MCH	23 pg/L	20,0	25,4	**Eosinofili**		0,07	0,8				
MCHC	33,8 g/dl	32,0	39,0	**Basofili**		0	0,1				
RDW	13,9%	12,0	16,0								

CPK	**286 U/L**	90	320	**CHO**	**29 mg/dl**	95	210
AST	**107 U/L**	15	35	**TRIG**	41 mg/dl	19	81
ALT	**257 U/L**	32	87	**BUN**	**18 mg/dl**	32	64
ALP	**1396 U/L**	19	70	**CRE**	**0,36 mg/dl**	0,95	1,85
GGT	**5.9 U/L**	0,1	0,6	**GLU**	**128 mg/dl**	86	116
TBILI	**2,86 mg/dl**	0,14	0,26	**CA**	**9,2 mg/dl**	9,3	11,2
TP	**4,5 g/dl**	6,3	7,8	**P**	**7,1 mg/dl**	3,5	6,6
ALB	**2,8 g/dl**	3	4	**Cl**	**103 mg/dl**	112	119
GLO	**1,7 g/dl**	3	4,5	**Na^+**	**133 meq/L**	145	152
A/G	**1,65**	0,72	1.25	**K^+**	**3,3 meq/L**	3,5	4,7

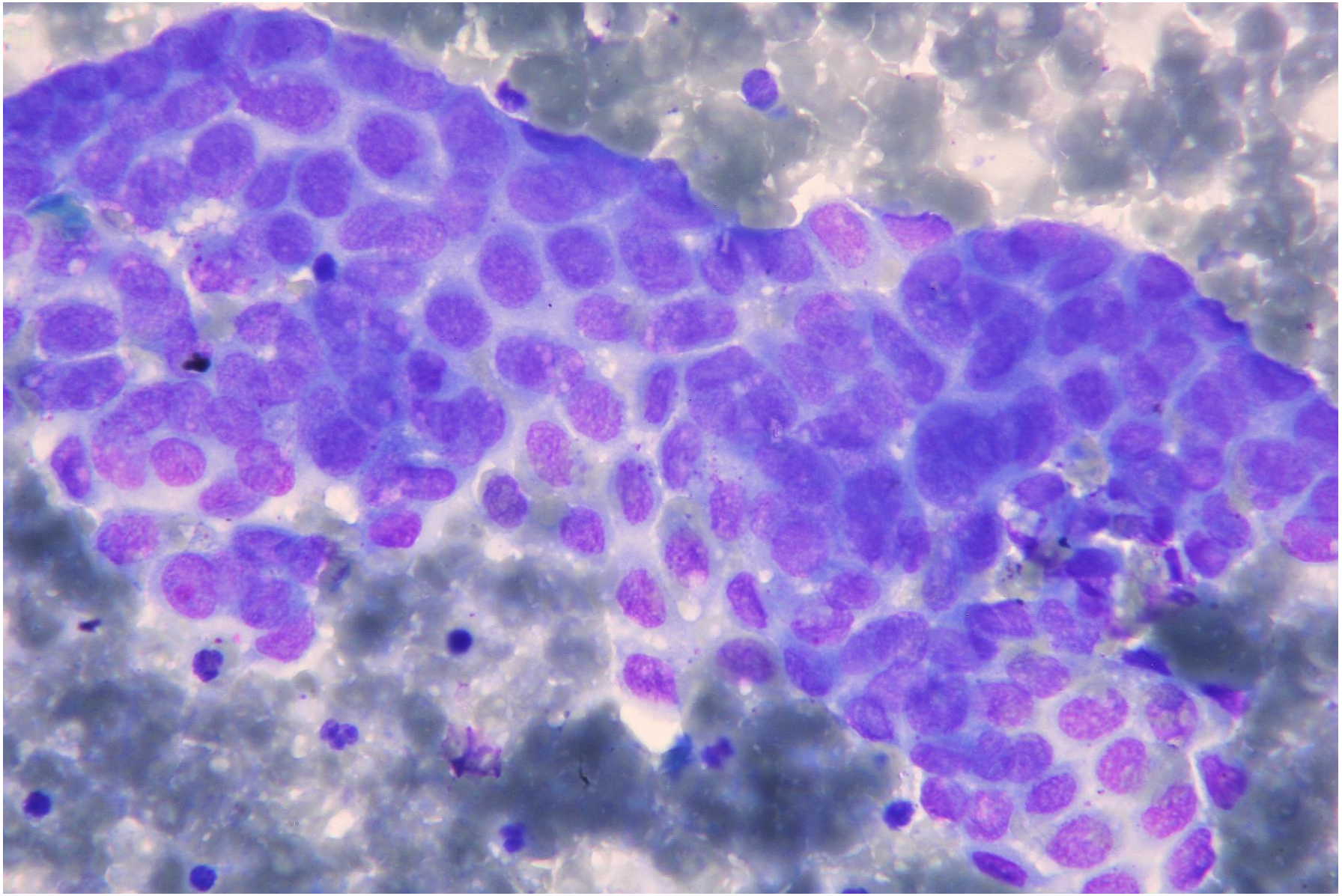

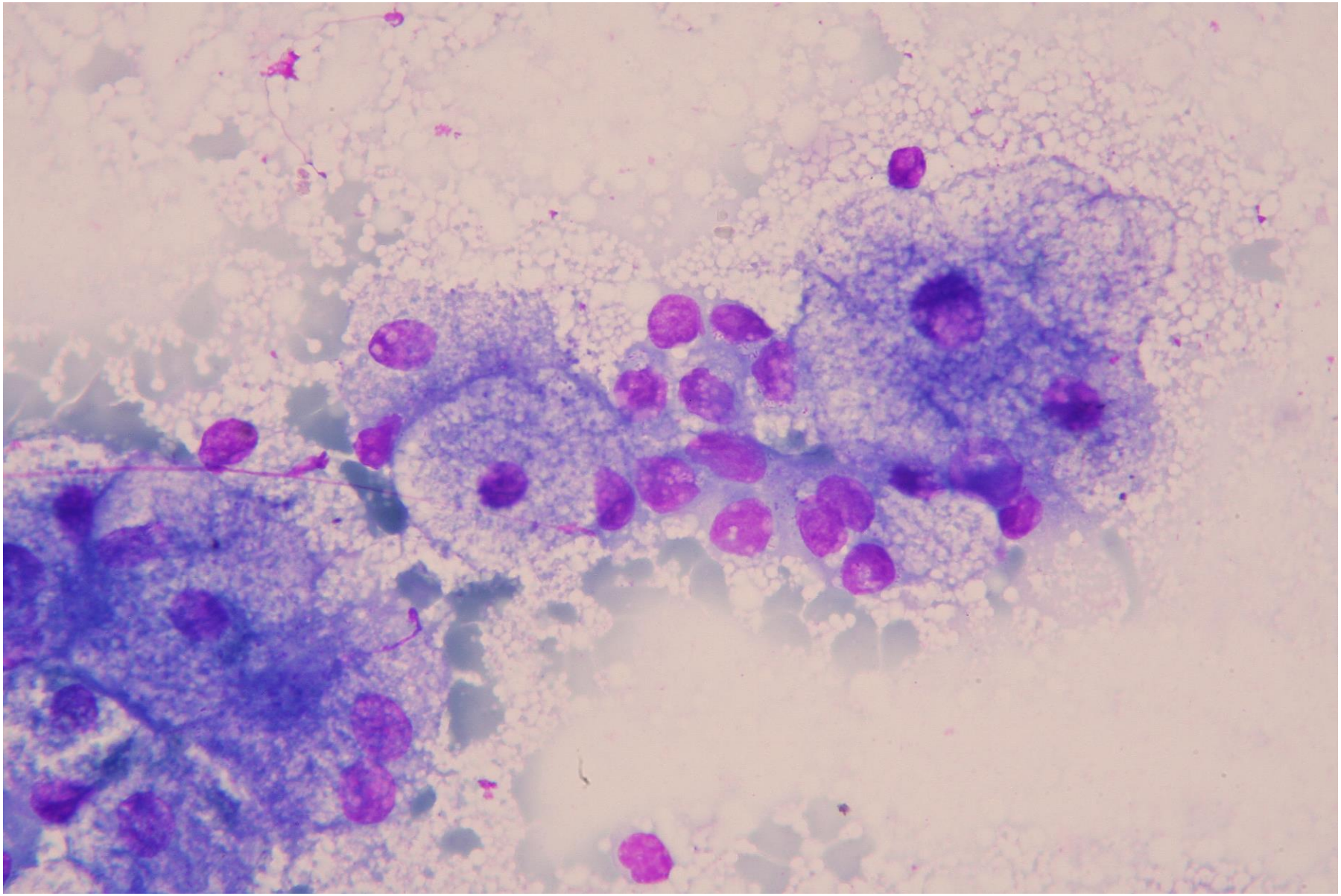

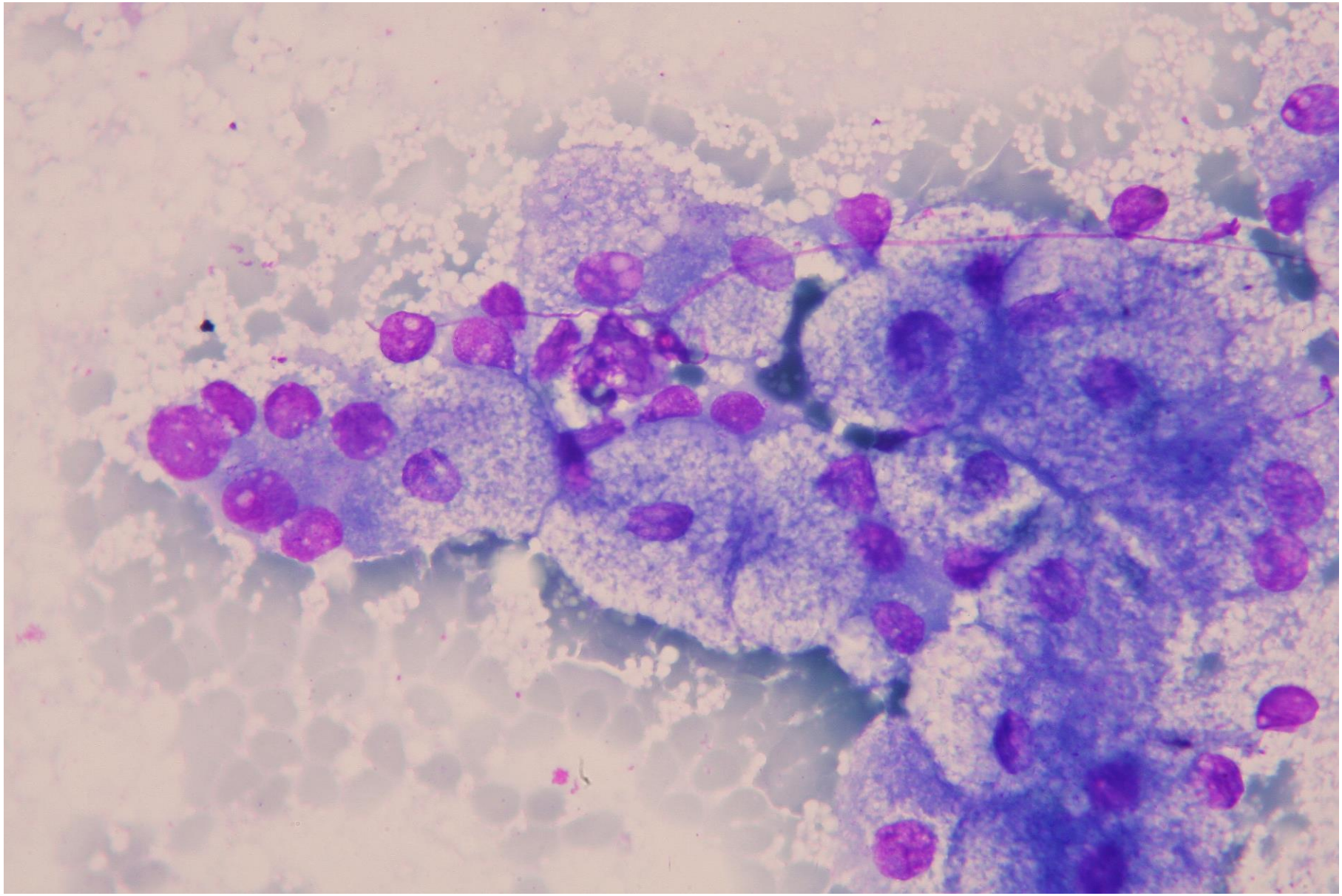

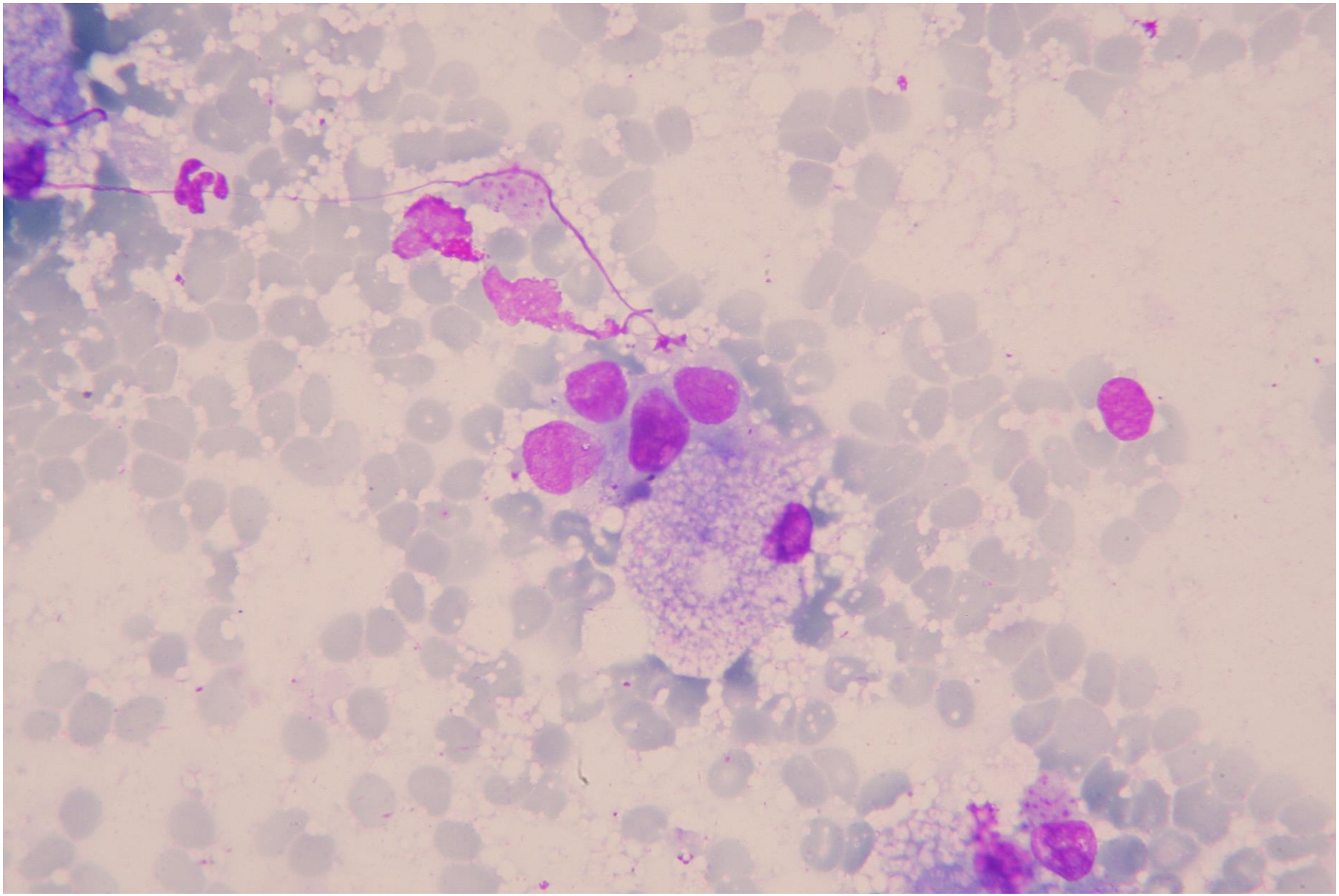

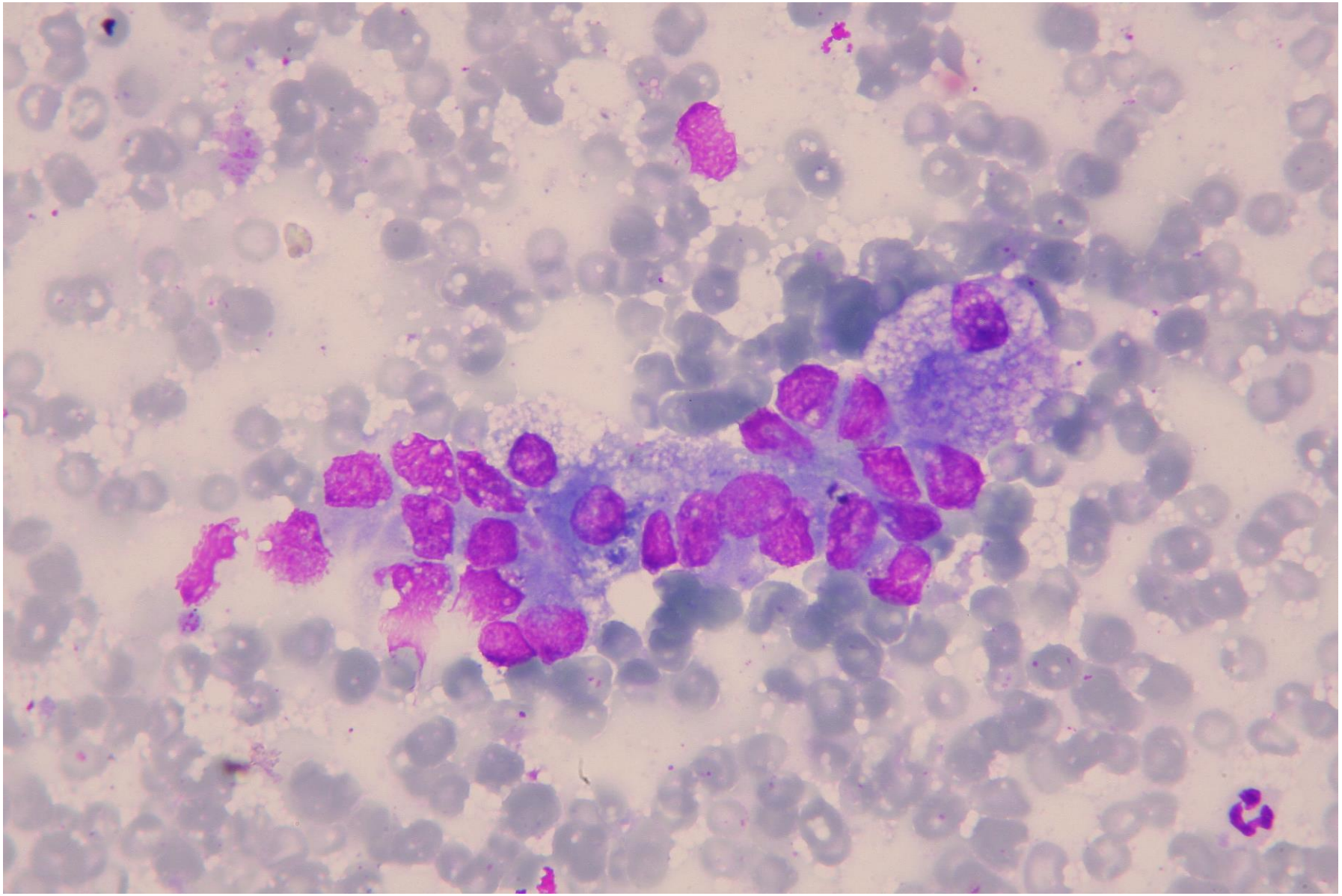

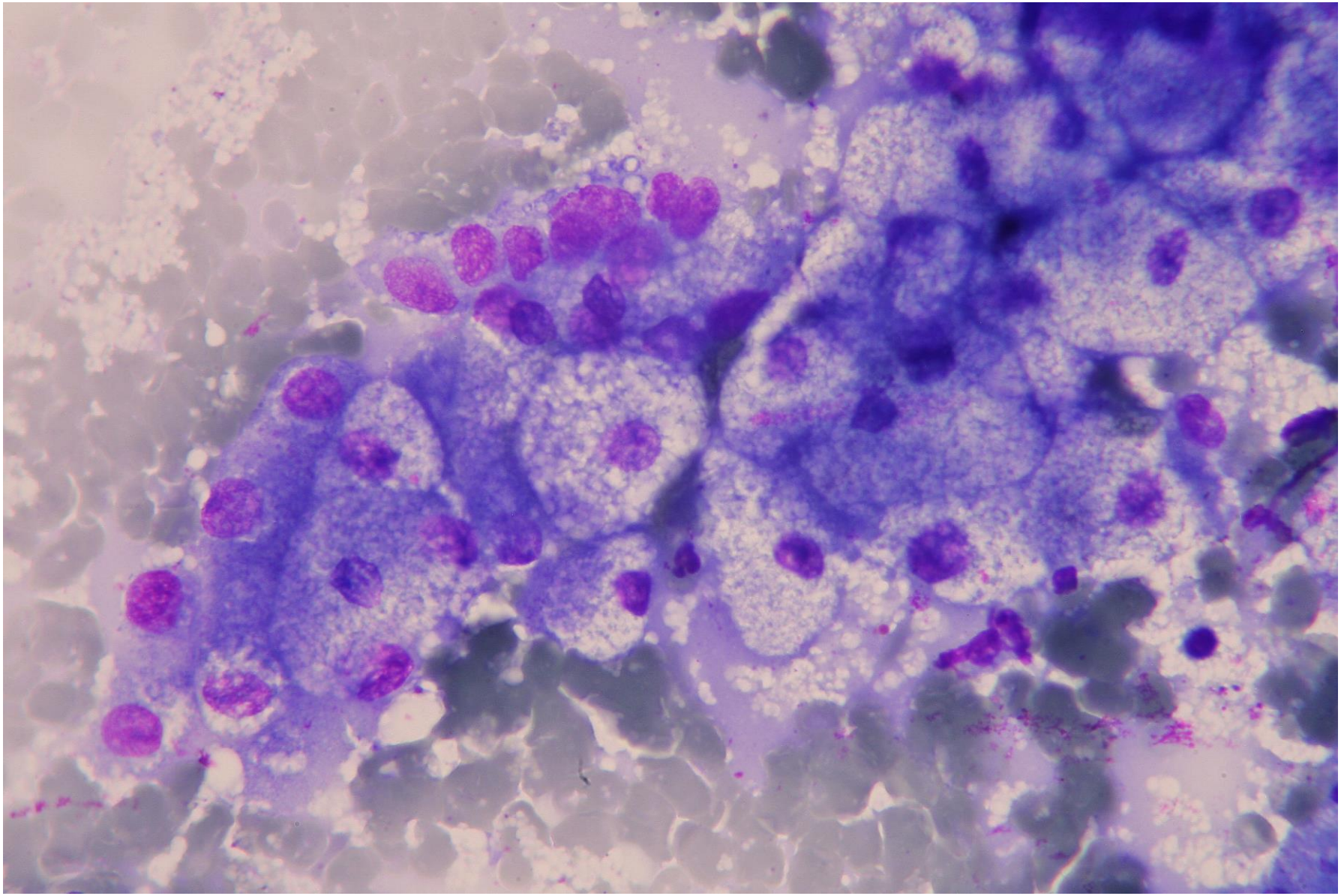

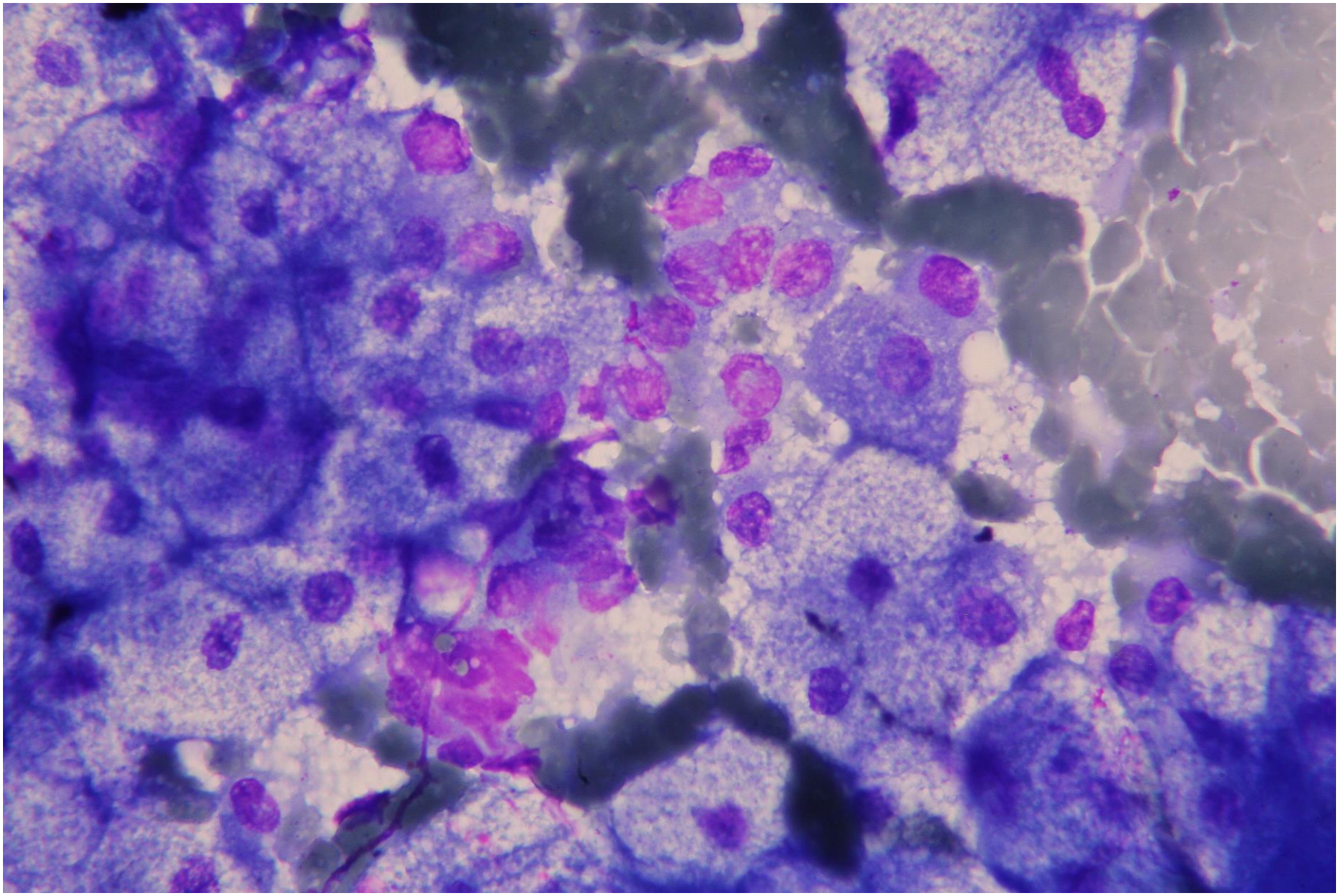

Cytological findings

- Reversible aspecific damage of the hepatocytes
  - Microvesicular steatosis
- Presence of a «high» number of cuboidal cells in small aggregate
  - Biliary origin likely

Diagnosis

- Cytologic diagnosis
  - Microvesicular steatosis
  - Proliferative disease of bilary epithelium of unknow origin
    - Reactive causes more likely
    - Congenital hepatic fibrosis was suggested
    - No signs of neoplasia
- Histologic diagnosis
  - Hepatic ductular reaction

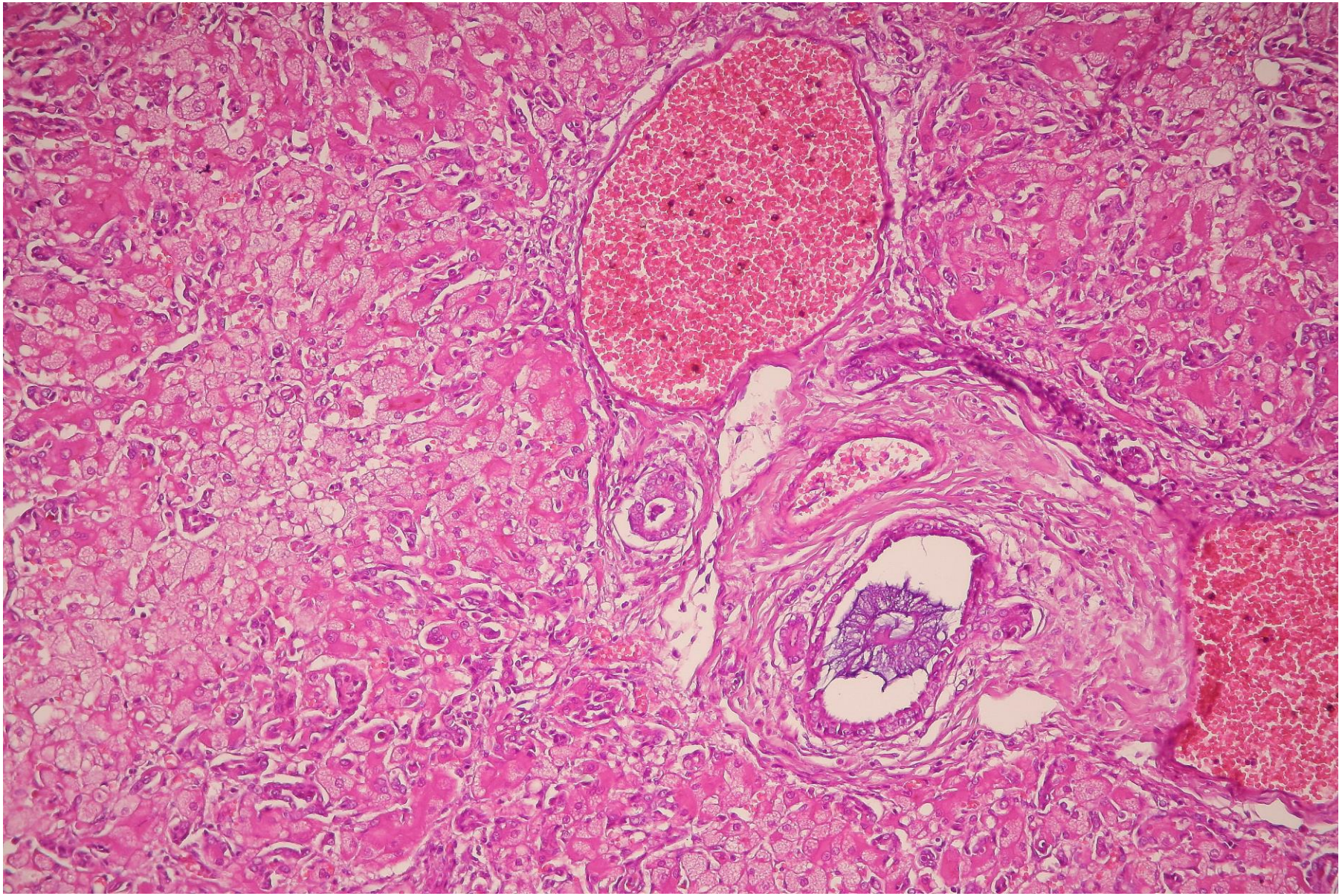

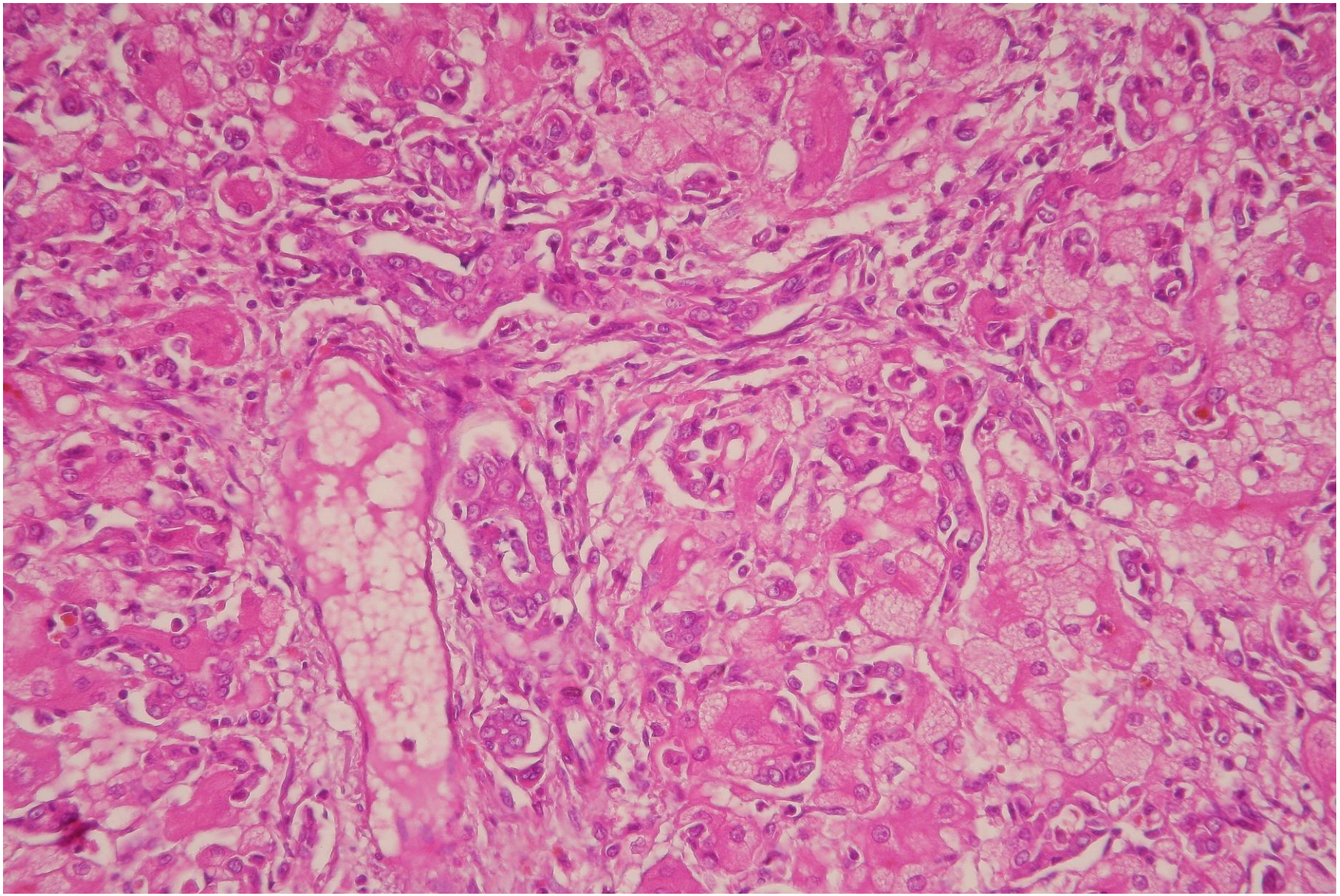

Discussion

- Ductular reaction (DR) is a stereotypical periportal response to injury, characterized by the proliferation of reactive bile ducts
- The origin of active cells during DR can be cholangiocytes, hepatocytes, or hepatic progenitor cells
- DR is pathologically recognized as bile duct hyperplasia and is commonly observed in biliary disorders
- It can also be identified in various liver disorders
  - Cholestatic liver diseases
  - Inflammatory liver diseases
  - Viral infections
  - Liver fibrosis
  - Senescence

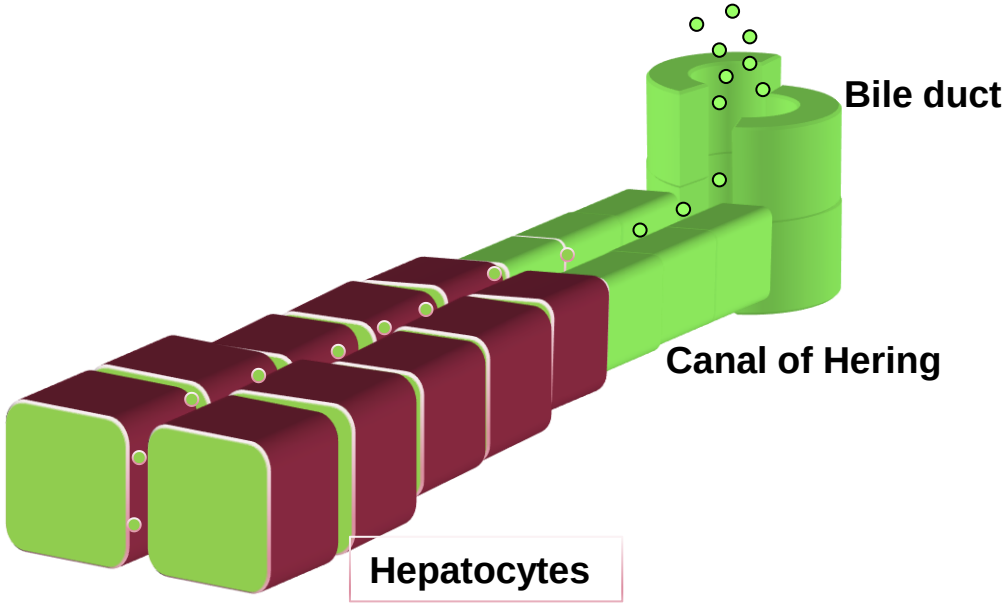
Bile duct
Canal of Hering
Hepatocytes

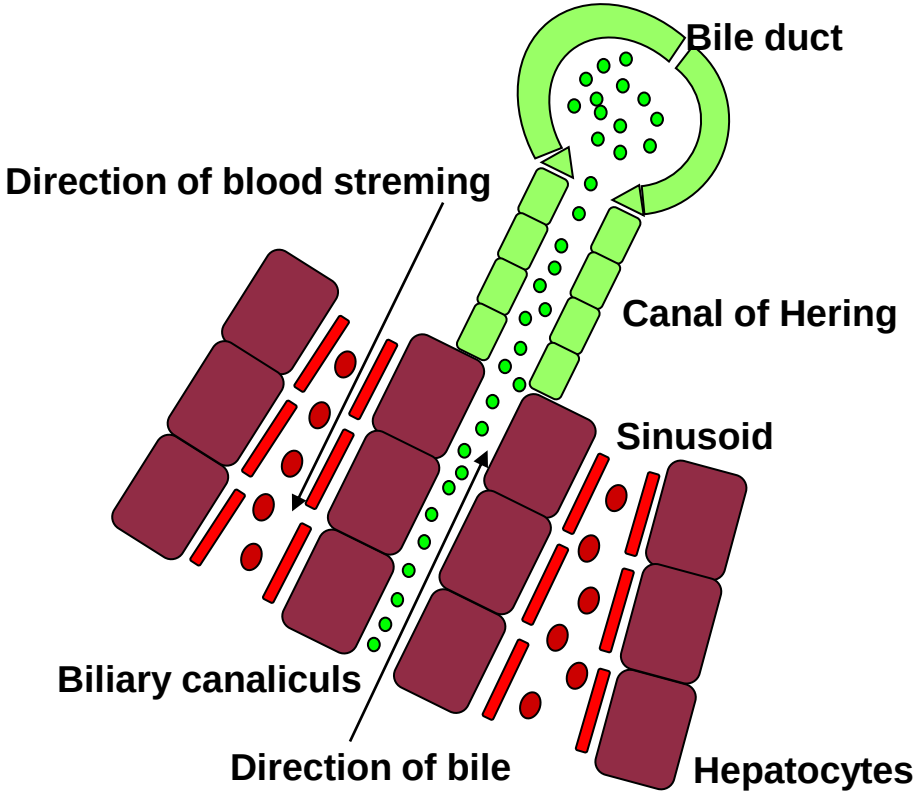
Bile duct
Direction of blood streming
Canal of Hering
Sinusoid
Biliary canaliculs
Direction of bile
Hepatocytes

Self-proliferation of cholangiocytes

- Ductular reaction type 1 (according with Desmet, 2011)
- Generally observed in acute cholestasis
- Interaction between inflammatory cells, stroma and cholangiocytes
- Elongation, branching and luminal widening of biliary tubes

Bile duct regeneration driven by hepatocytes

- Ductular reaction type 2A (according with Desmet, 2011)
- Also called “ductular metaplasia of hepatocytes”
- Generally observed in chronic cholestasis and apparently due to the intracellular accumulation of retained bile acids
- The newly formed ductules retain the labyrinthic, anastomosing pattern of hepatocellular plates

- Ductular reaction type 2B
- Generally centrolobular
- Induced by hypoxia

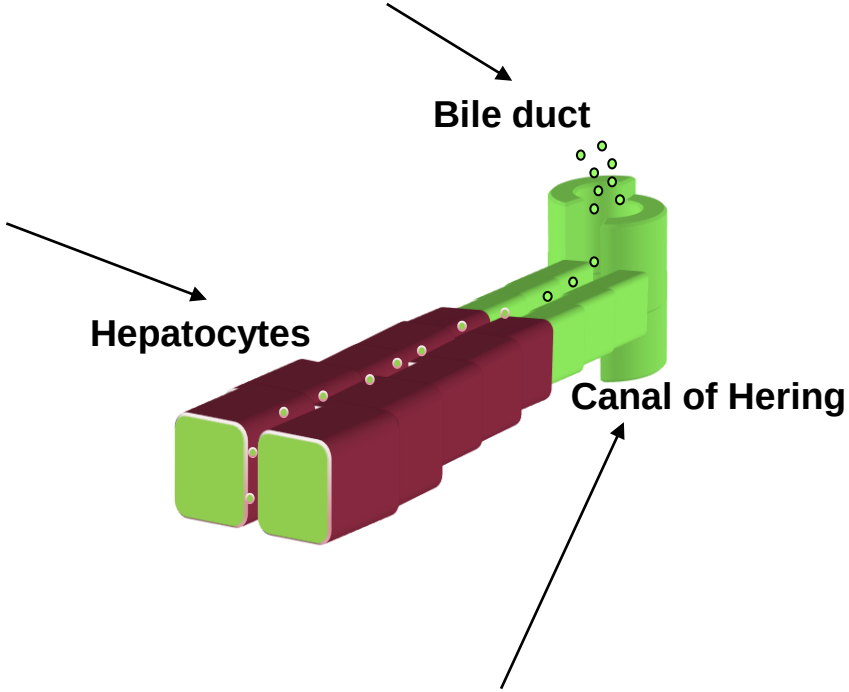

Bile duct regeneration driven by LPCs (liver progenitor cells – oval cells

- Ductular reaction type 3 (according with Desmet, 2011)
- Generally observed in case of massive loss of parenchymal cells

Discussion

- Not able to recognize primary cause
- Not able to differentiate among different DR types
  - Need of IHC
- Morphological features mostly suggestive (by me) of
  - Toxic disease
  - Acute viral disease

Case #5

- 8-year-old, male, Labrador dog
- Nodule on the gingiva

- FNCS of the lesion
- MGG stain

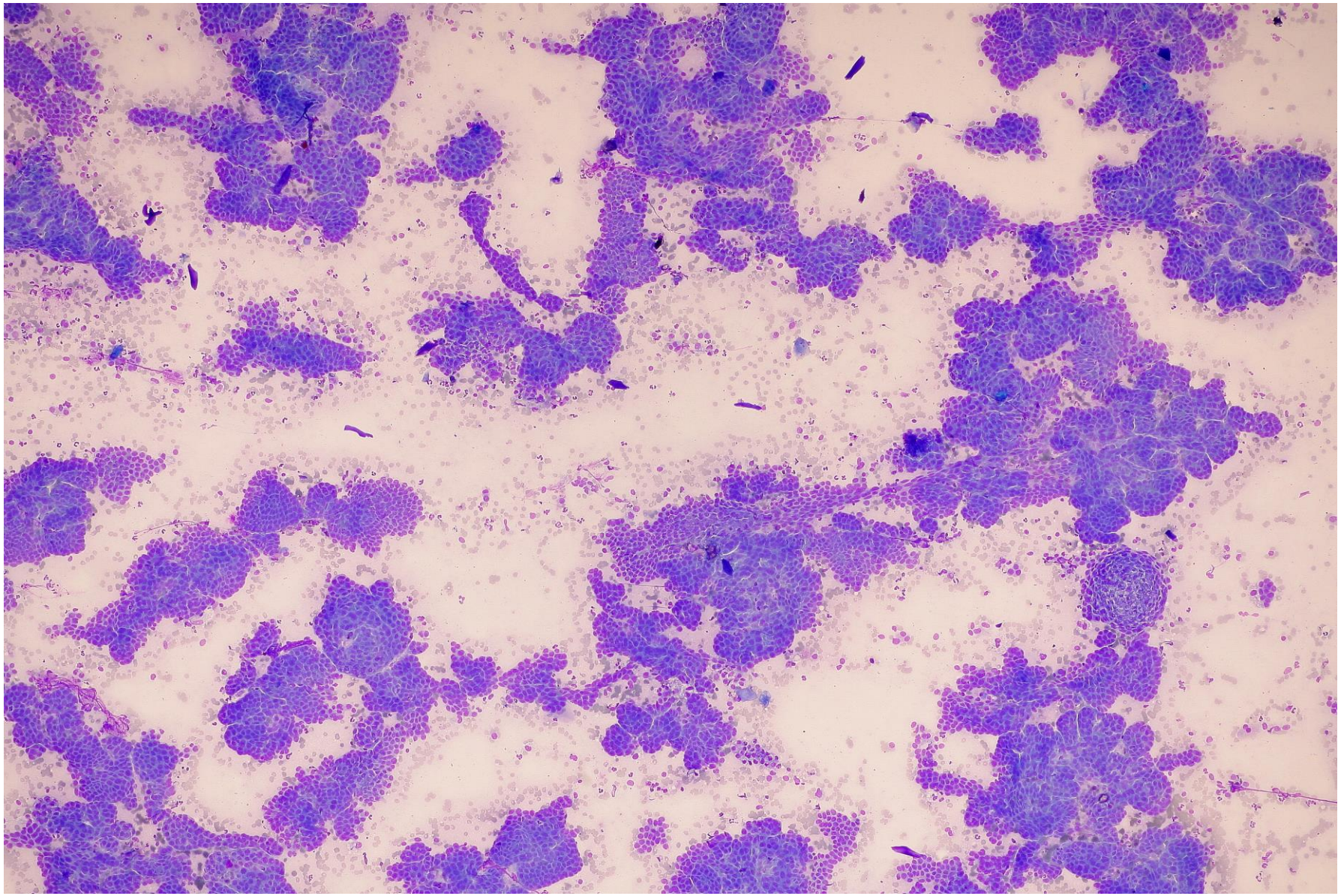

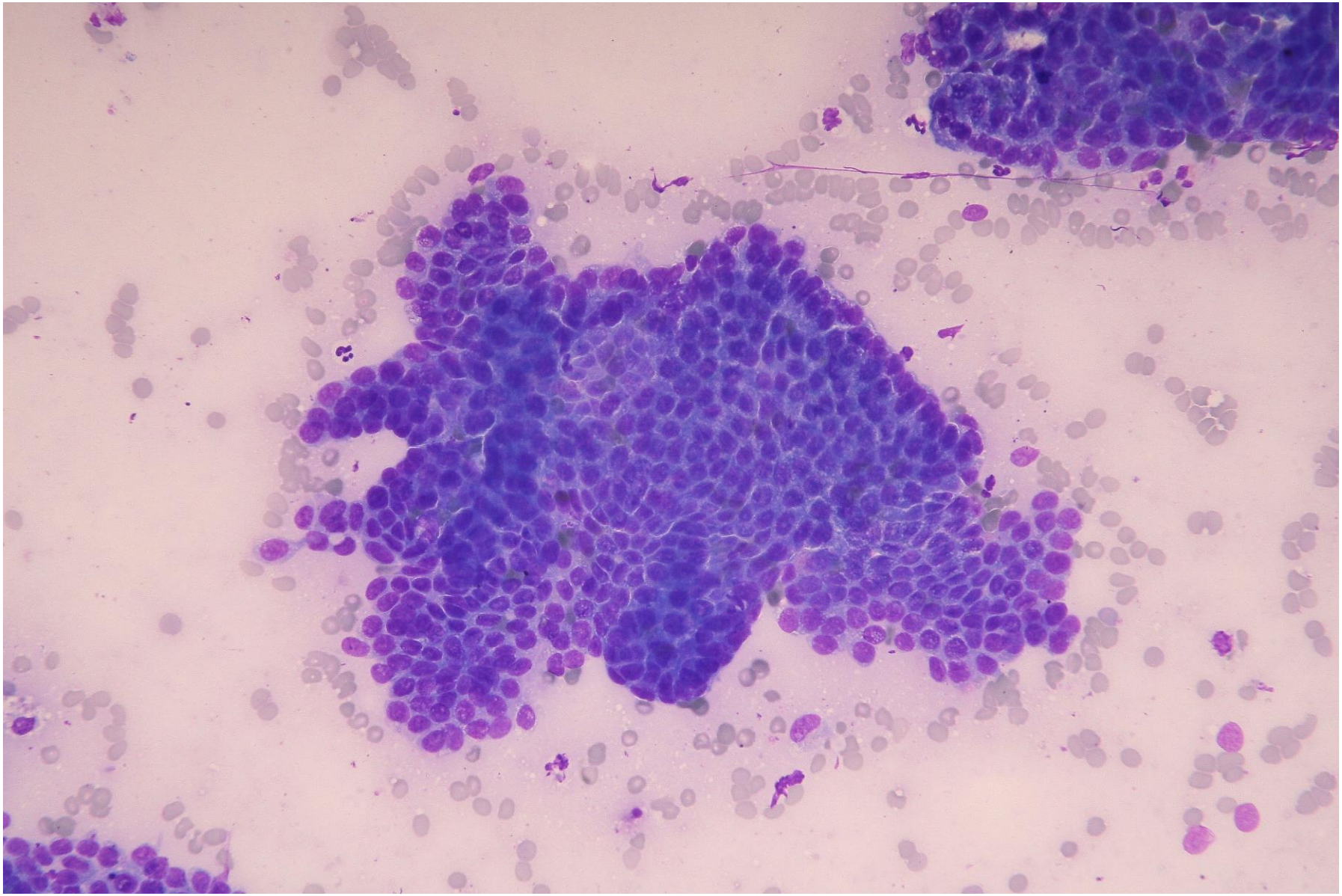

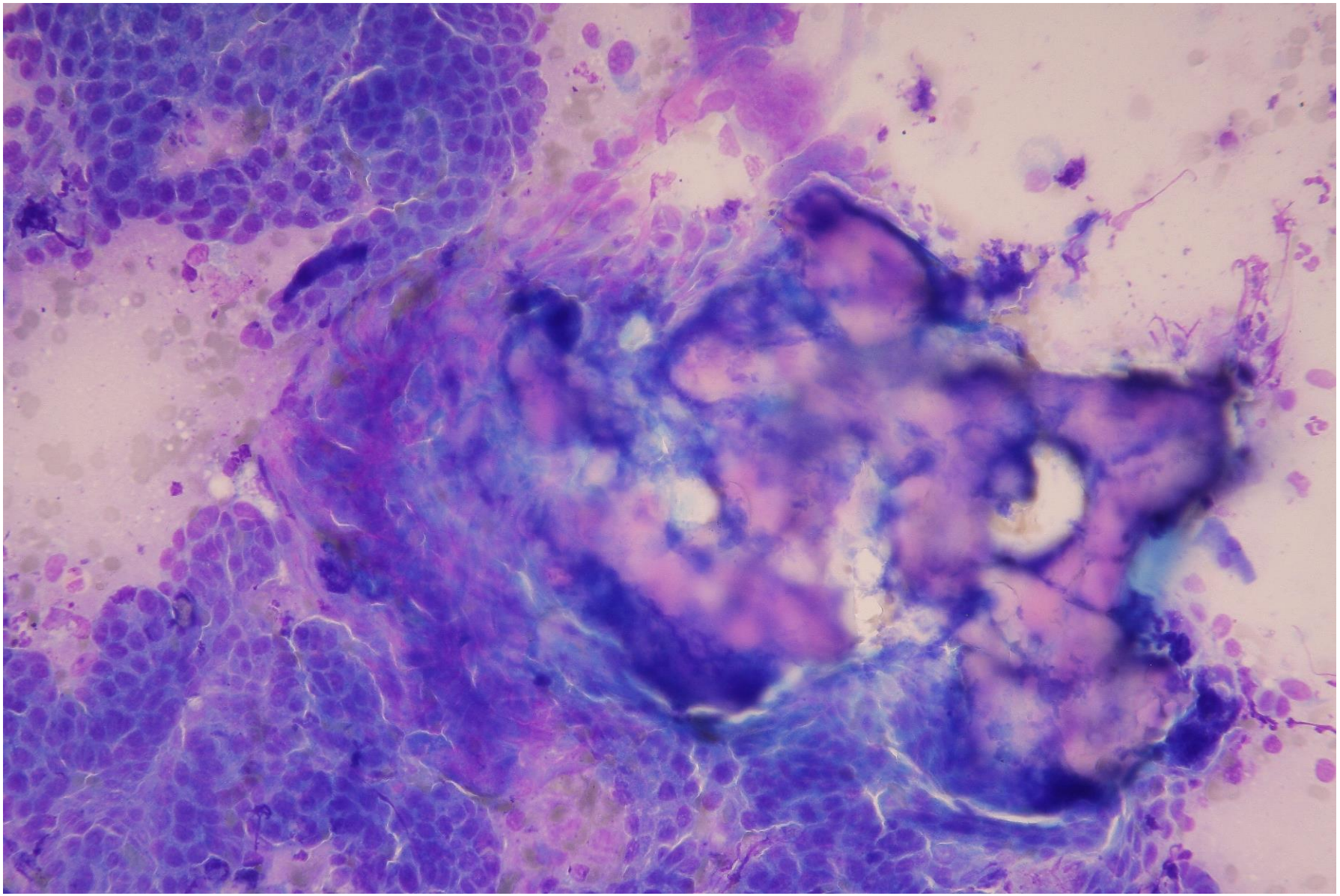

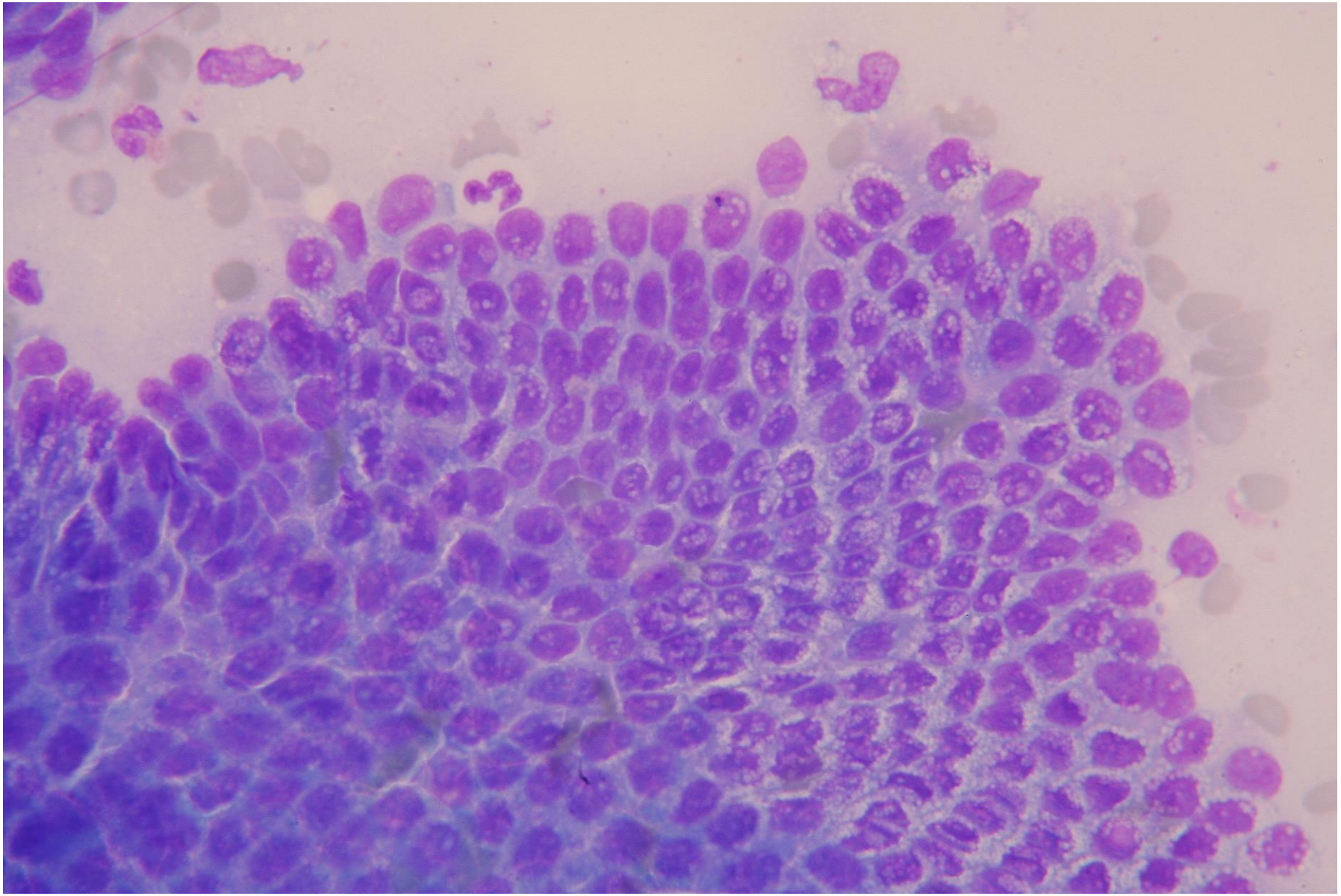

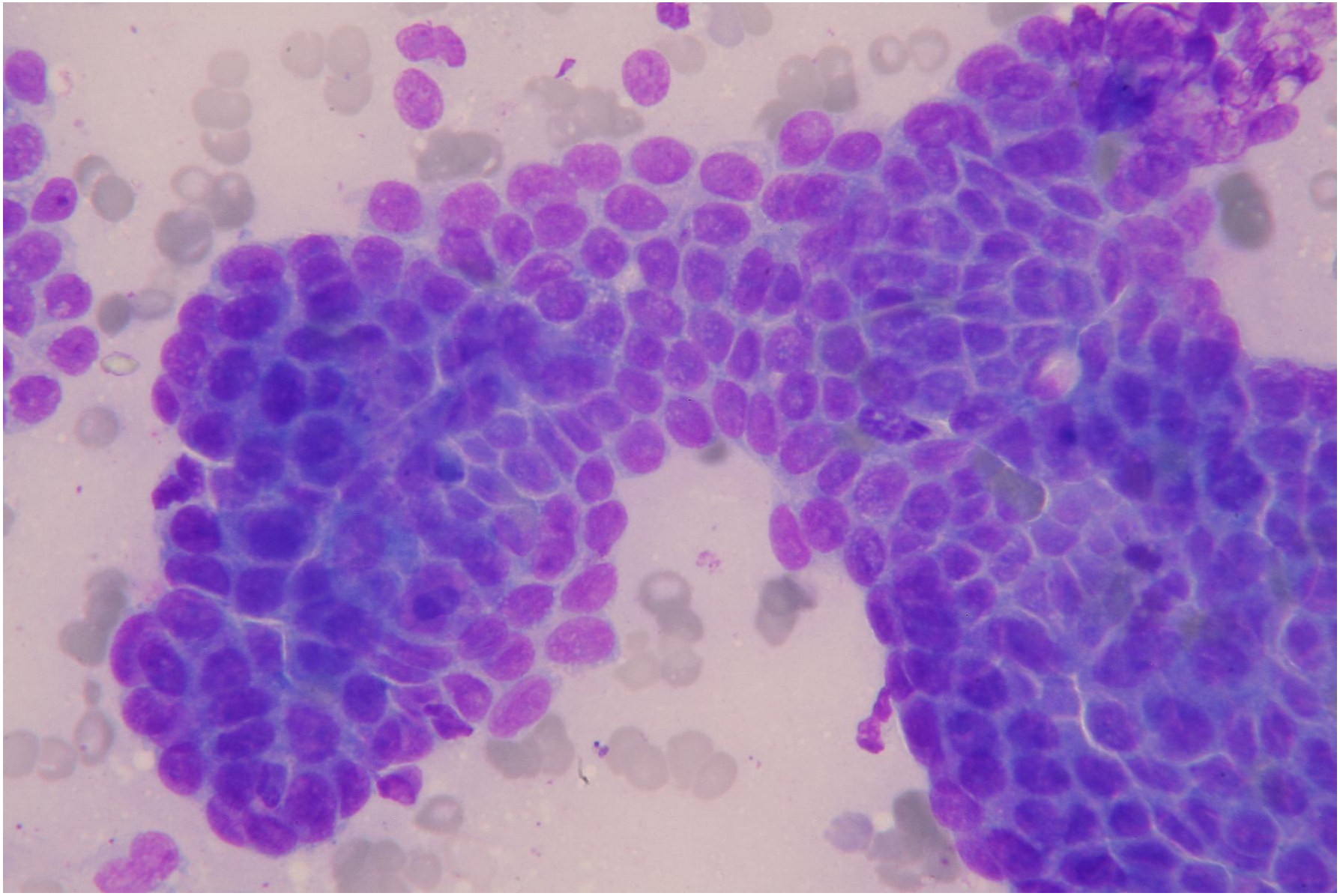

Cytologic findings

- High number of epithelial cells
  - Bluish, cuboidal cytoplasm
  - Small cytoplasmic globules
  - Round to ovoid nuclei
  - Anisokaryosis and aniscytosis are mild
- Trabecular arrangement
  - Peripheral palisading very frequent

Diagnosis

- Cytologic diagnosis
  - Benign epithelial neoplasia, morphologically suggestive of tumor of odontogenic origin (ameloblastoma most likely)
- Histological diagnosis
  - Ameloblastoma

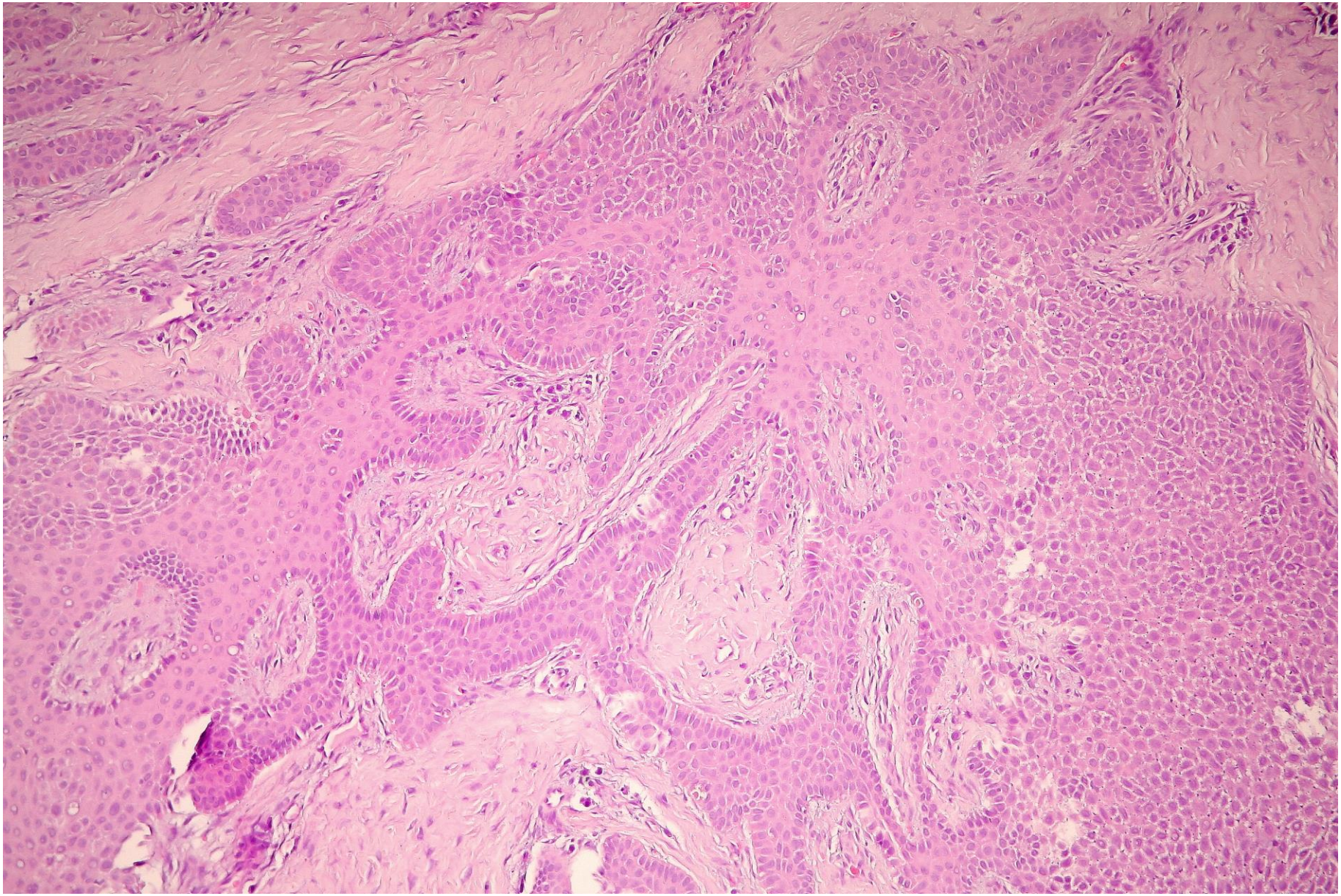

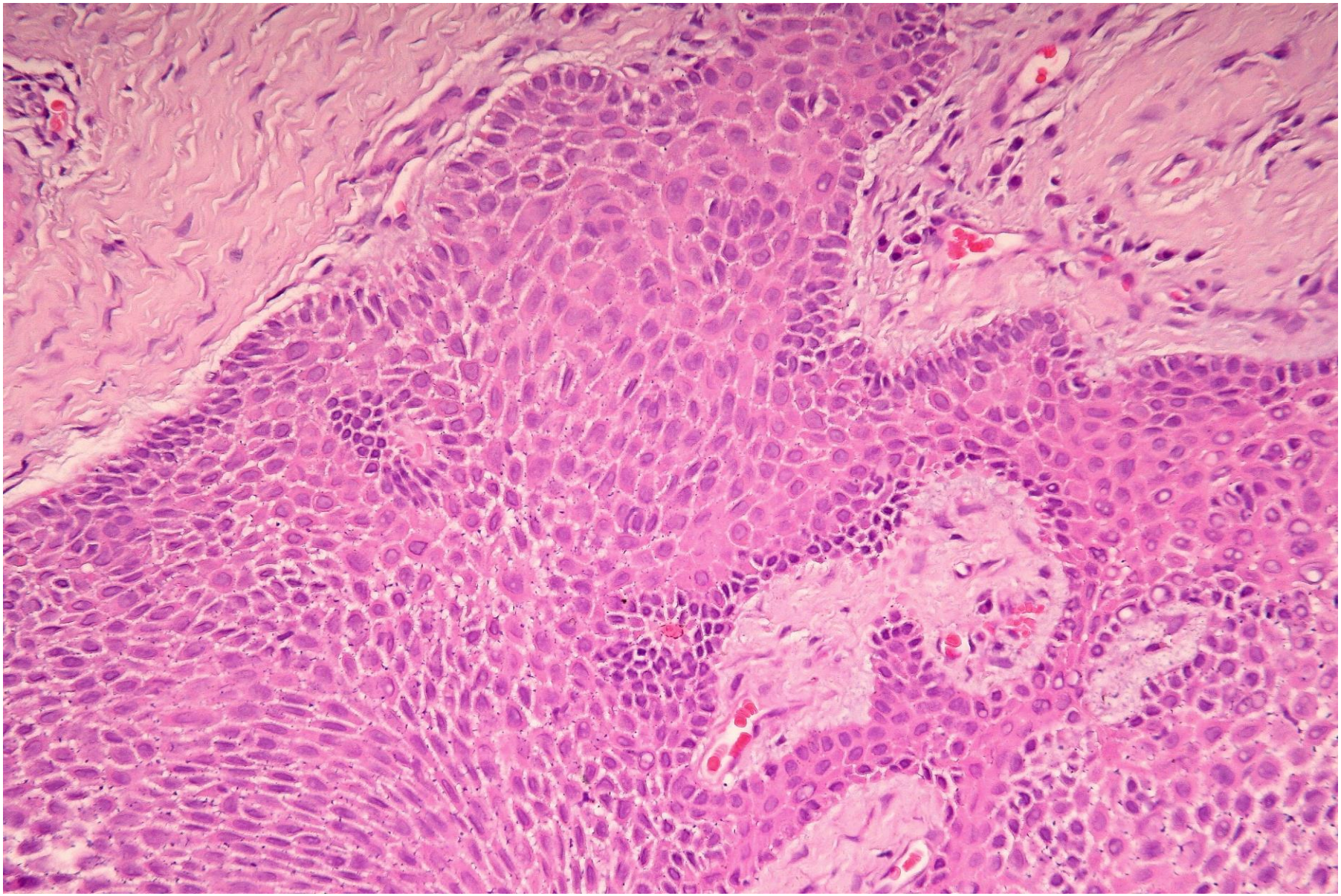

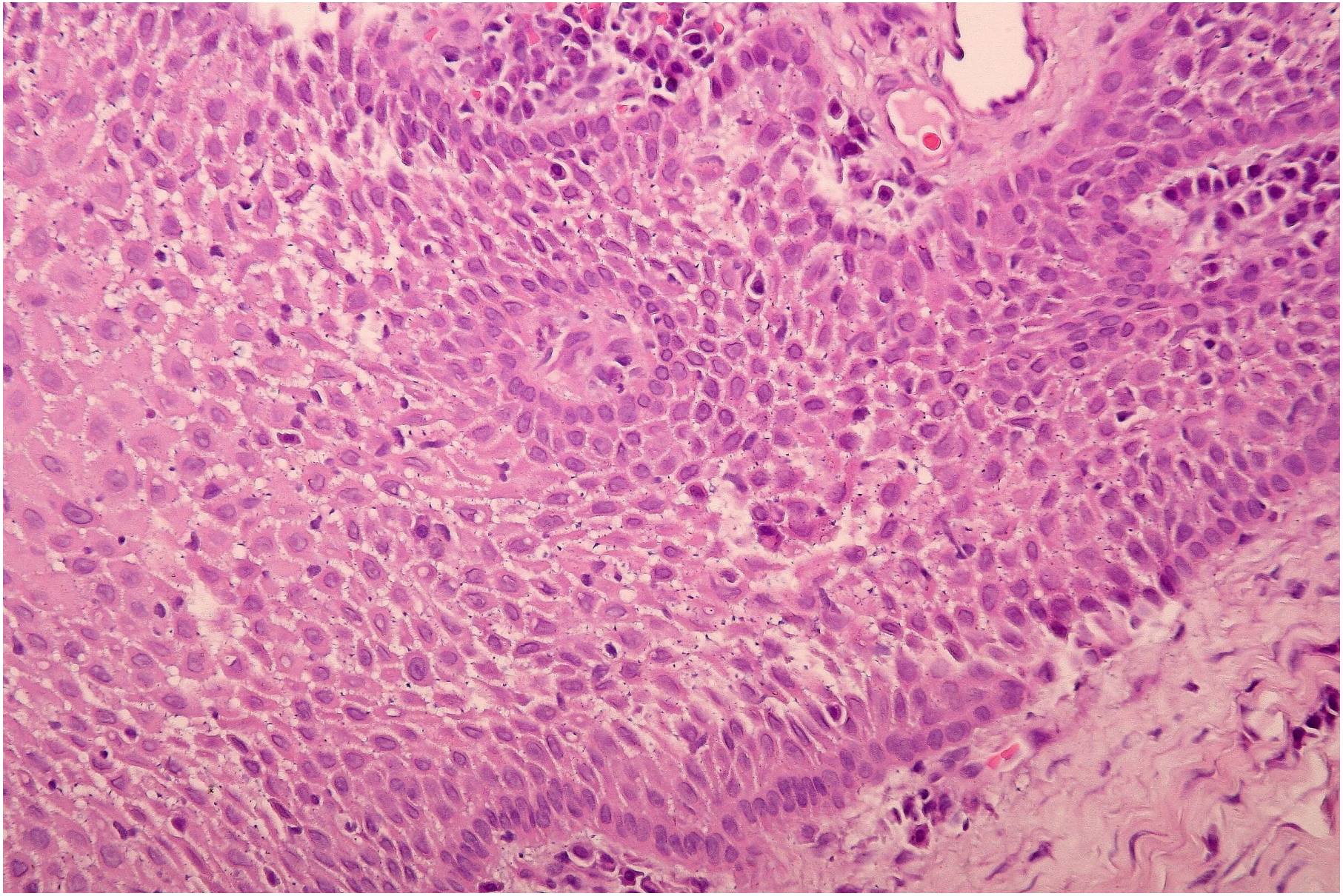

Discussion

- The cardinal features of odontogenic epithelium include:
  (according with Murphy BG, Bell CM, Soukup JW. Veterinary Oral and Maxillofacial Pathology, 2020, Wiley Blackwell)

  - Palisading of the basilar epithelium
  - The palisading epithelial cells have antibasilar nuclei (nuclei located at the apical pole)
  - Palisading cells can have a basilar clear zone within the cytoplasm
  - Centrally located cells of the differentiated enamel organ: the odontogenic islands are (should be, may be …) comprised of polygonal cells with long intercellular desmosomal bridges reminiscent of the stellate reticulum

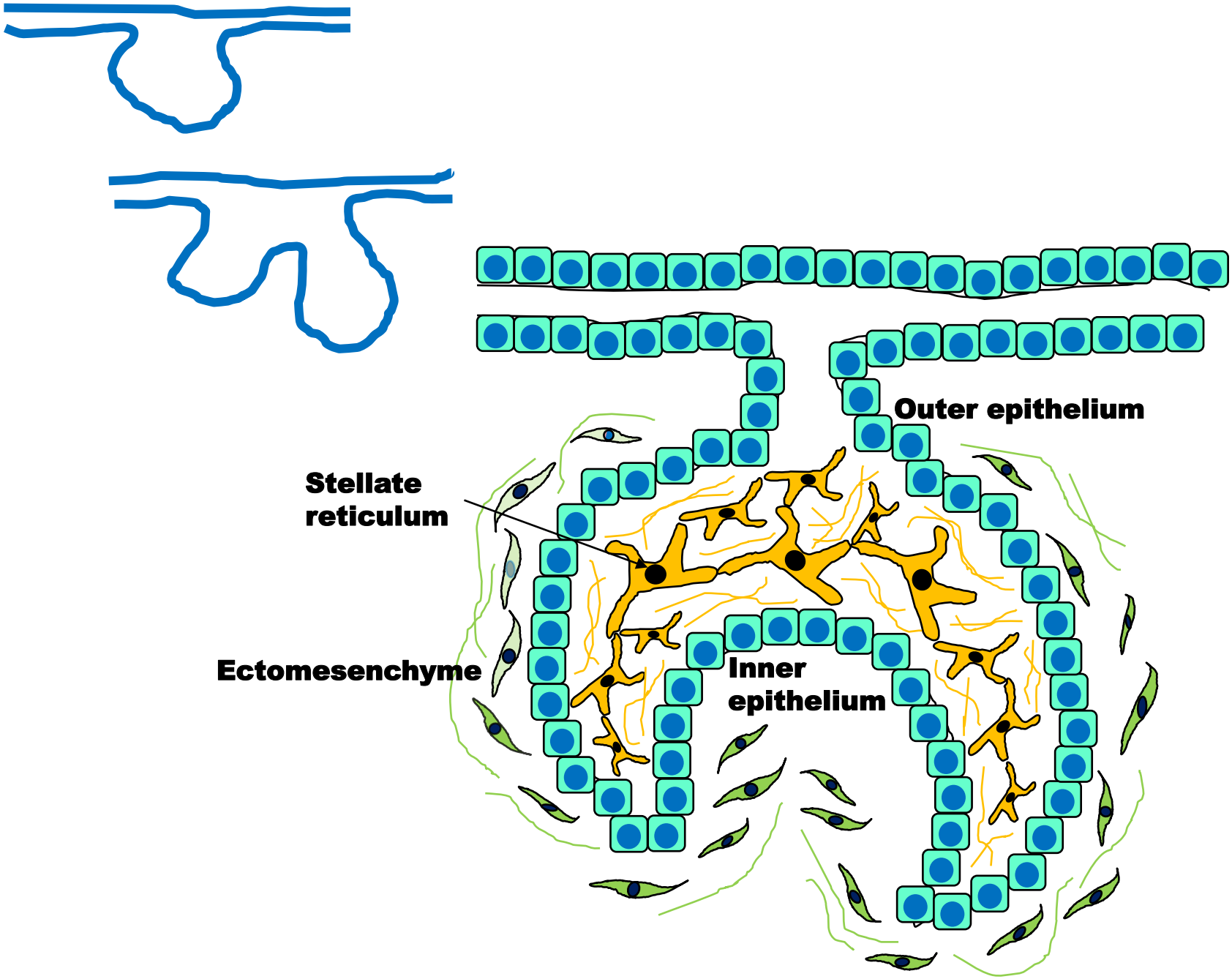
Outer epithelium
Stellate reticulum
Ectomesenchyme
Inner epithelium

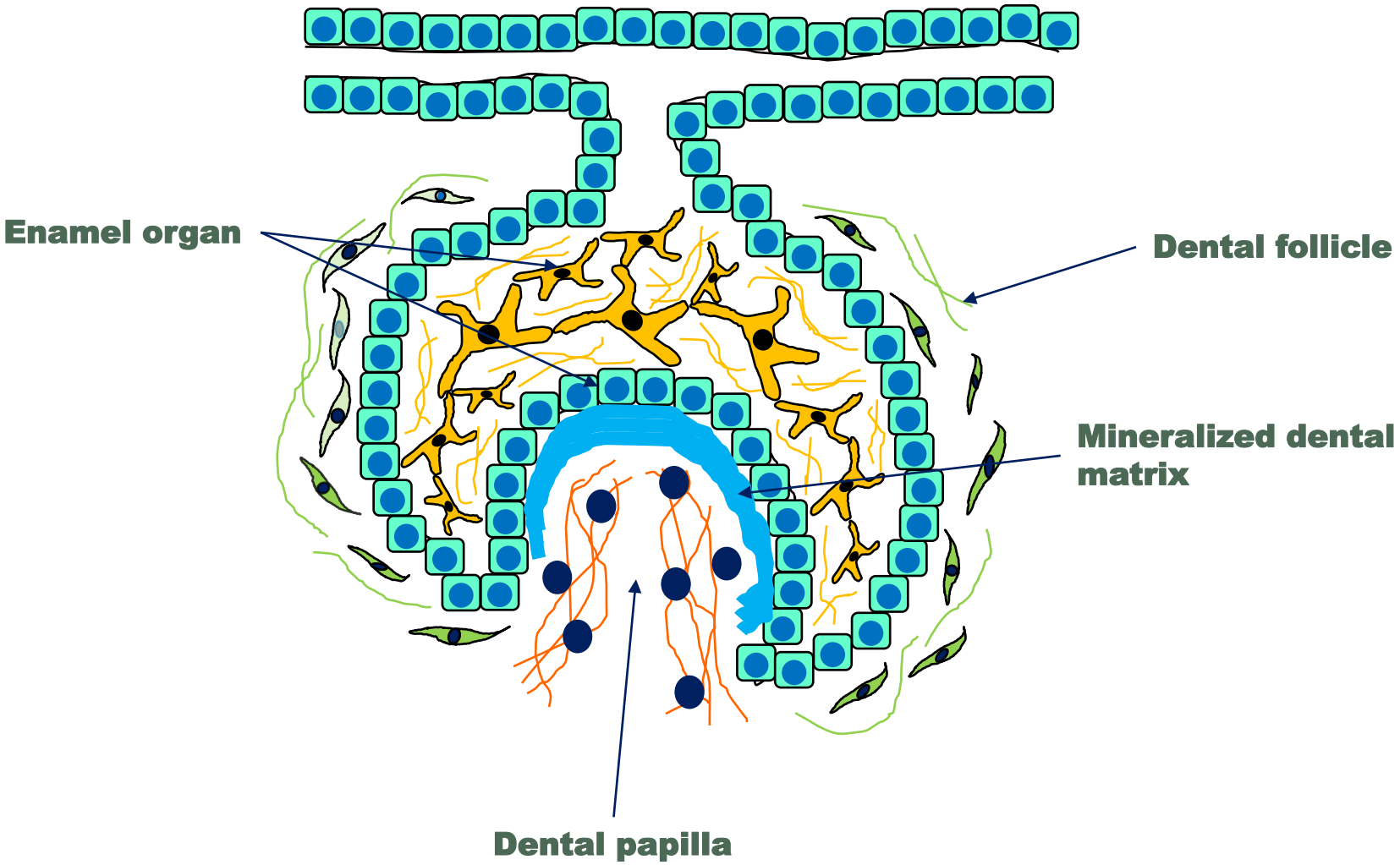
Enamel organ
Dental follicle
Mineralized dental matrix
Dental papilla

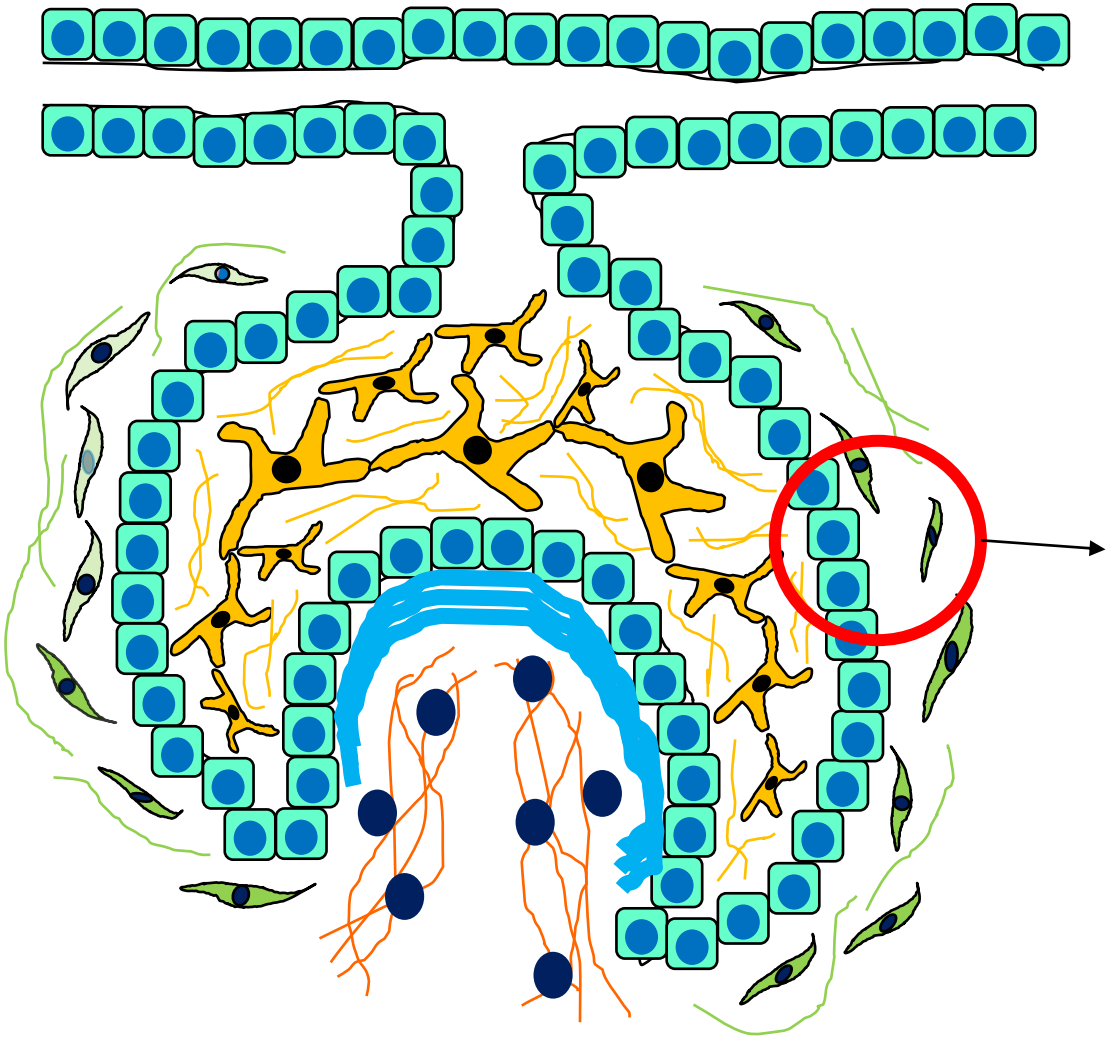

Ameloblastoma

Peripheral odontogenic fibroma

Case #6

- 6-year-old, female, Labrador dog
- Nodule on the nailbed

- FNCS of the nodule
- MGG stain

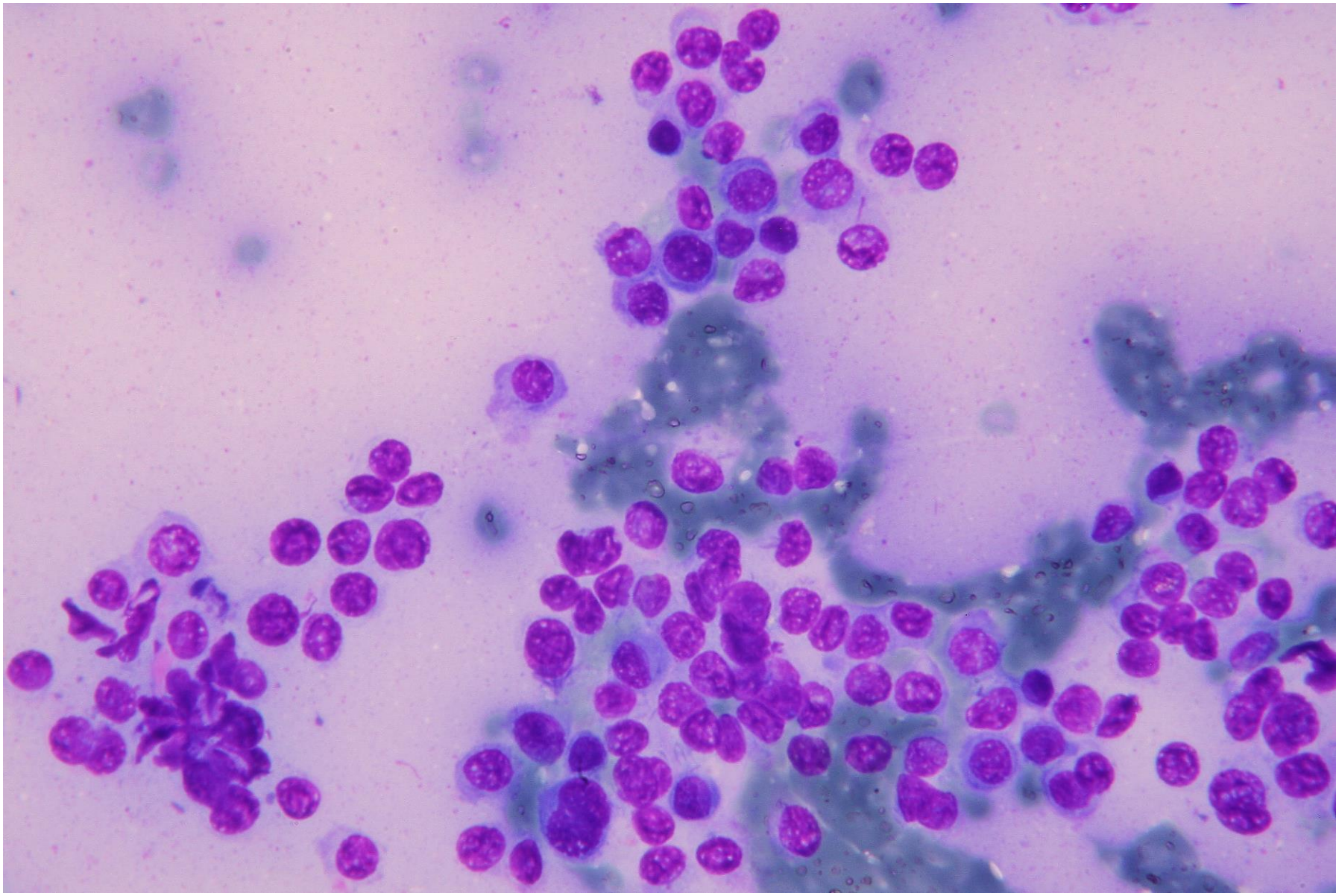

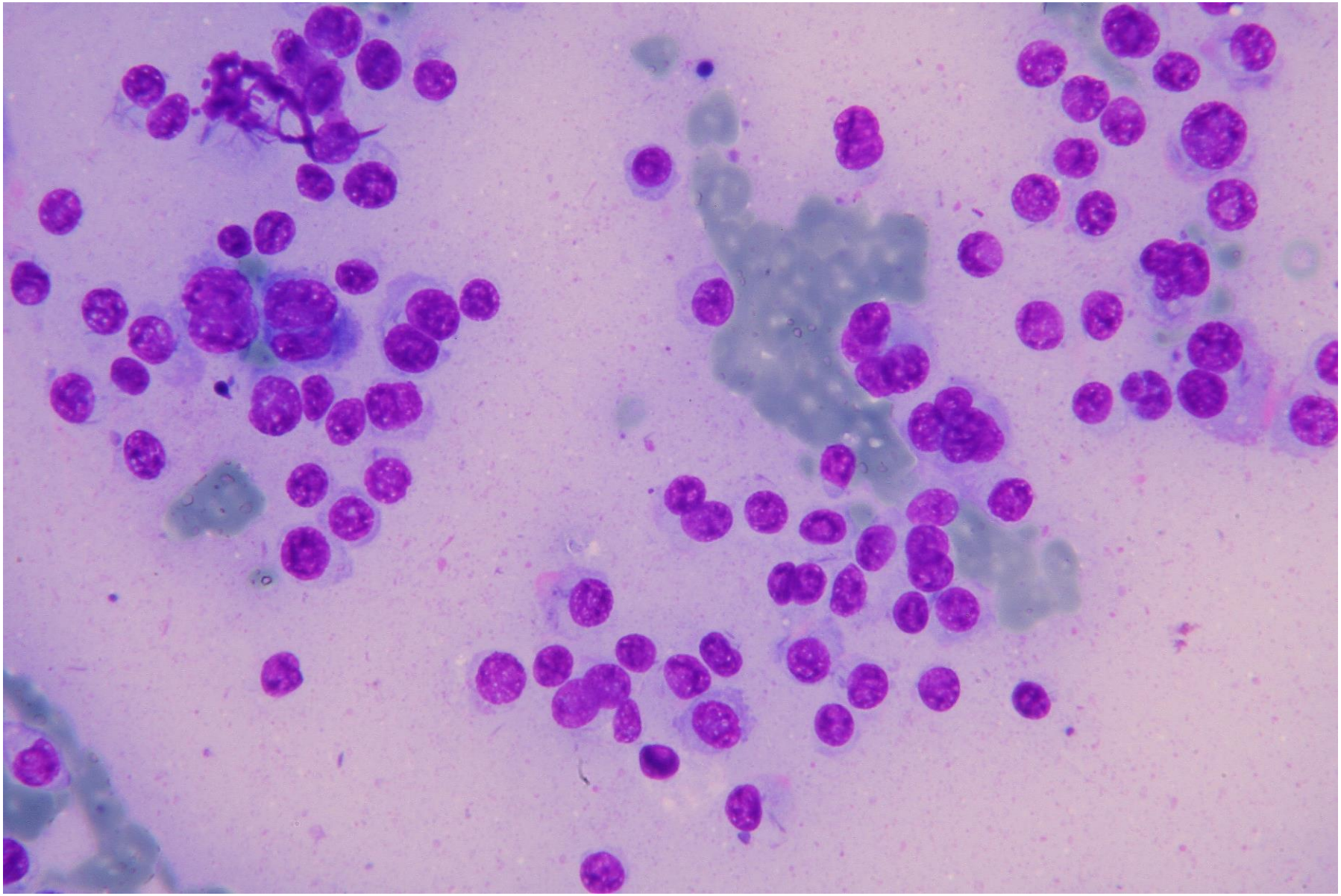

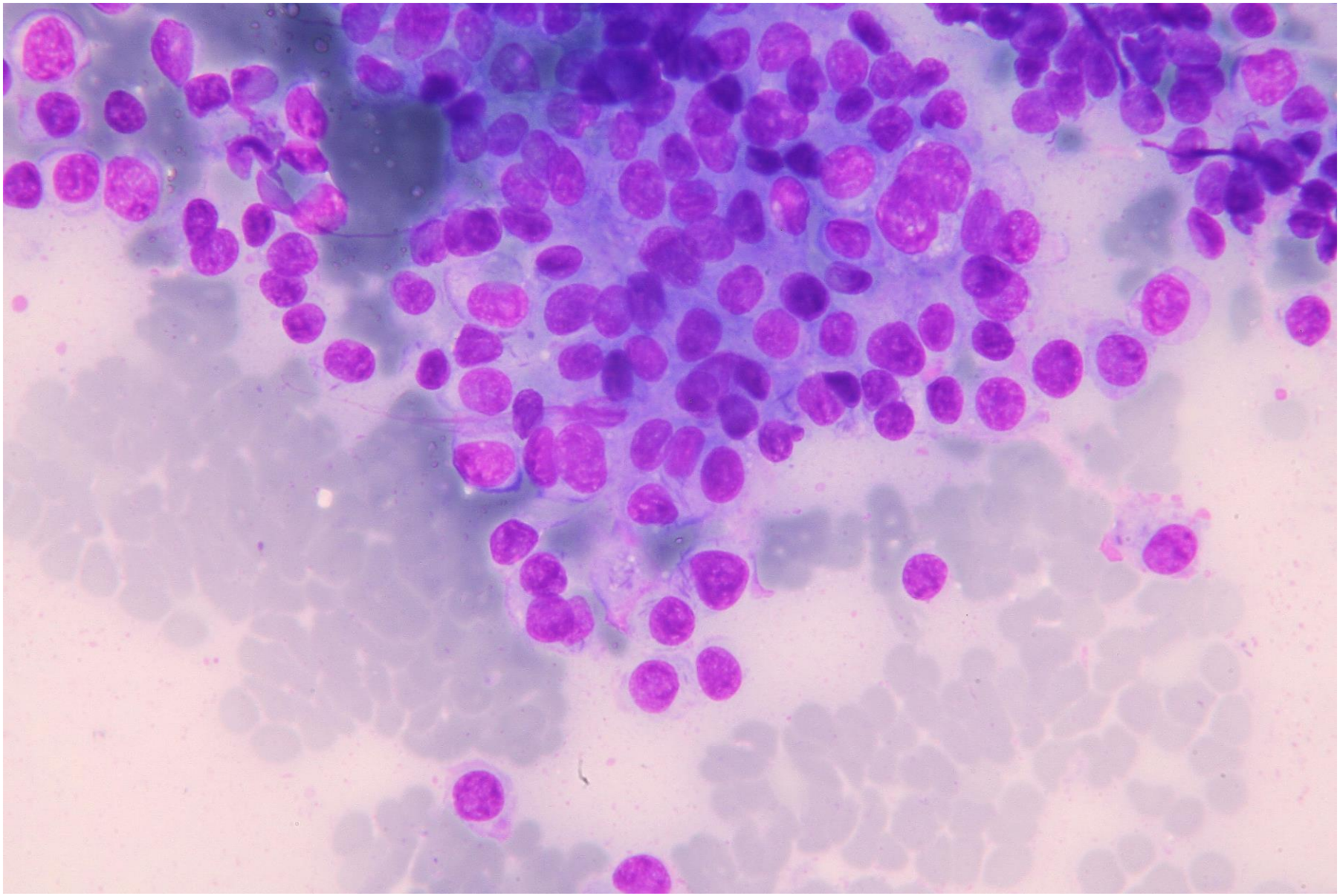

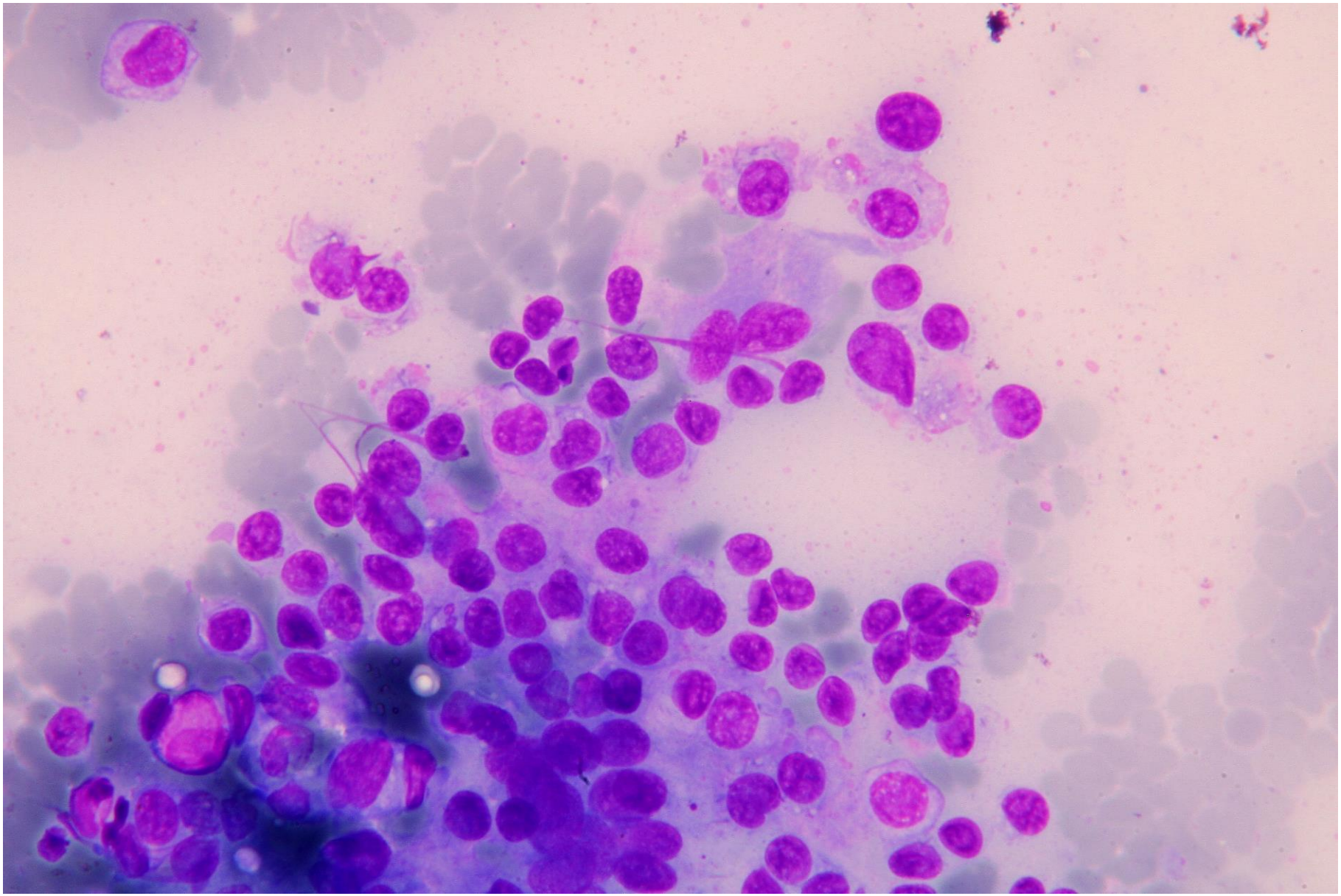

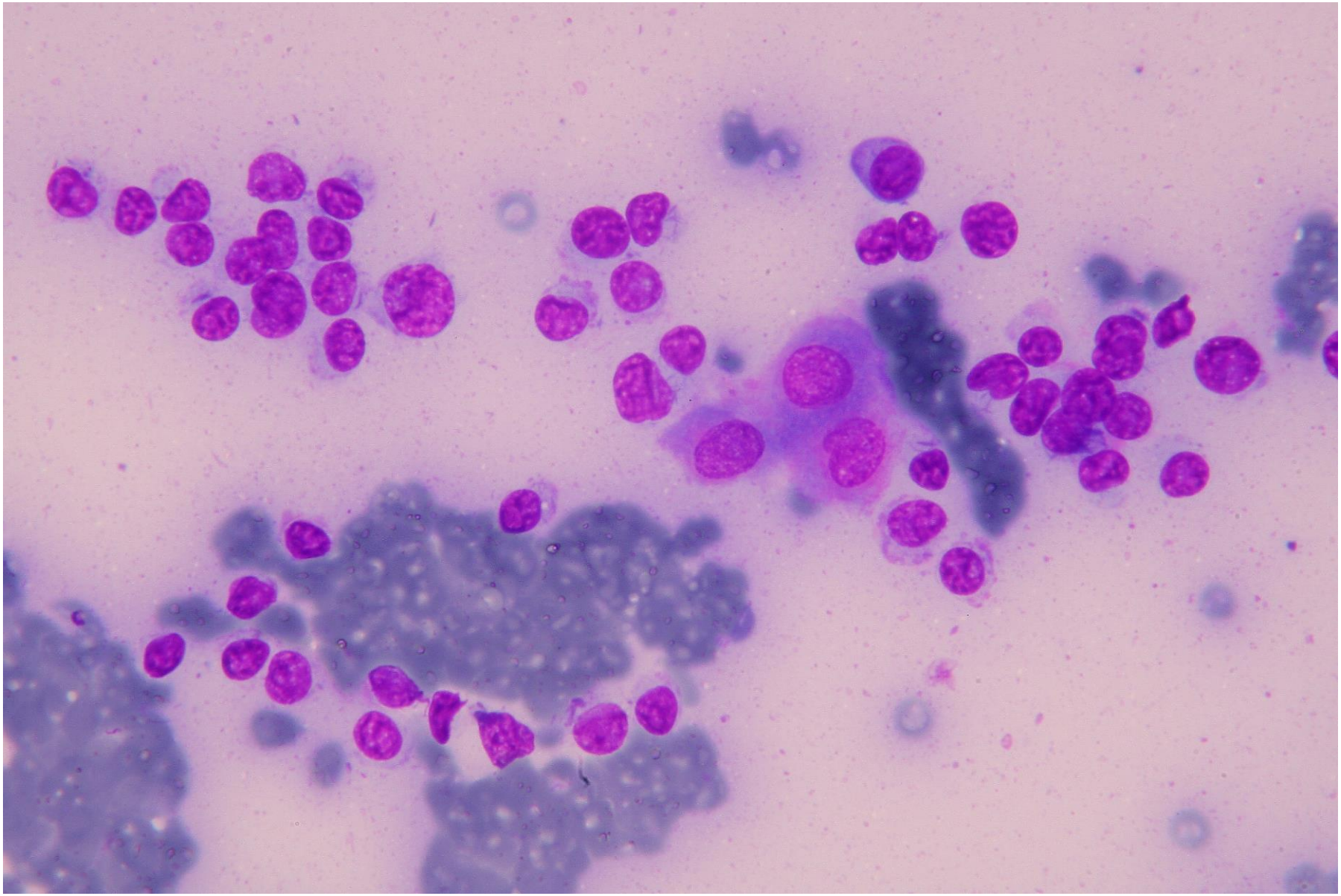

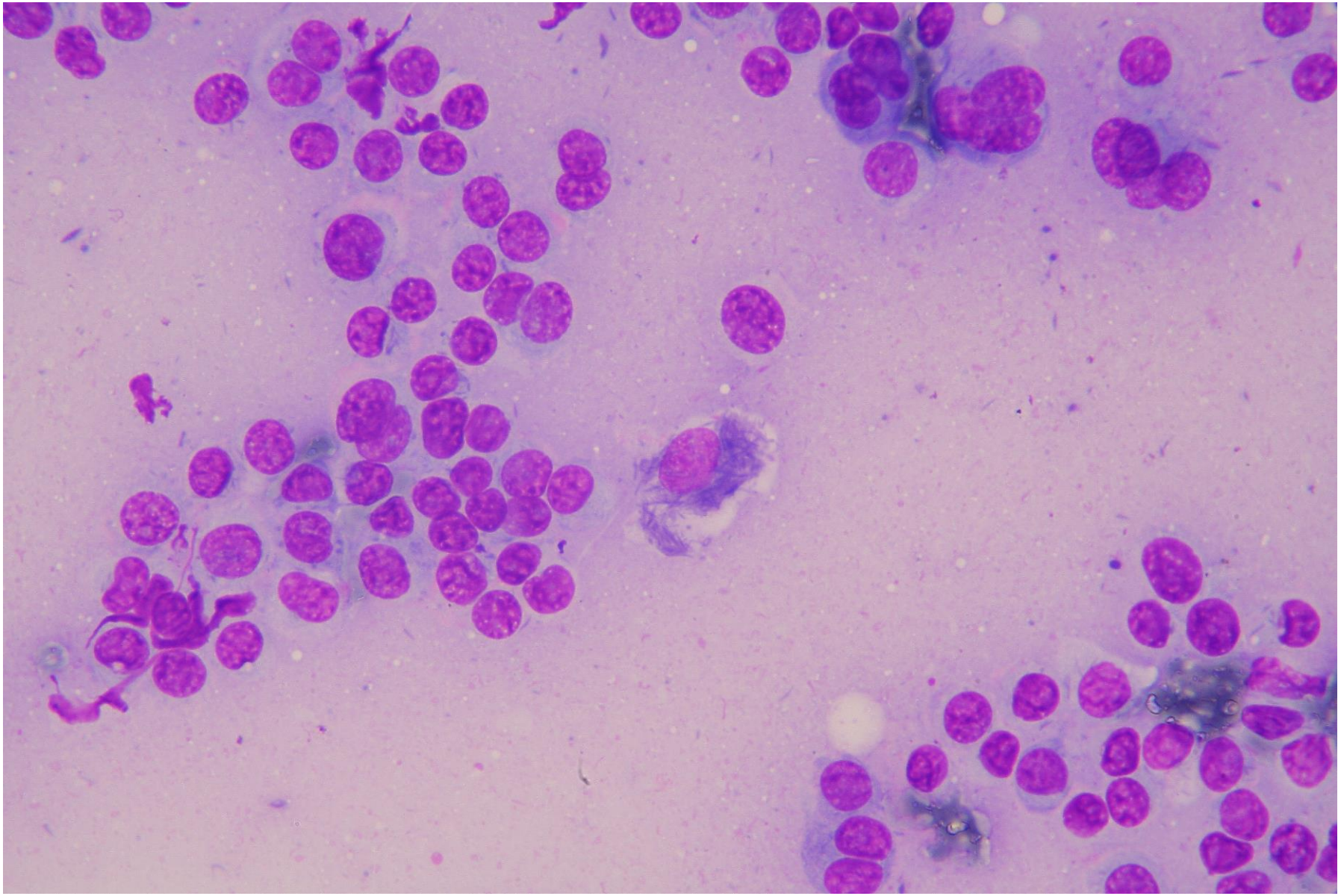

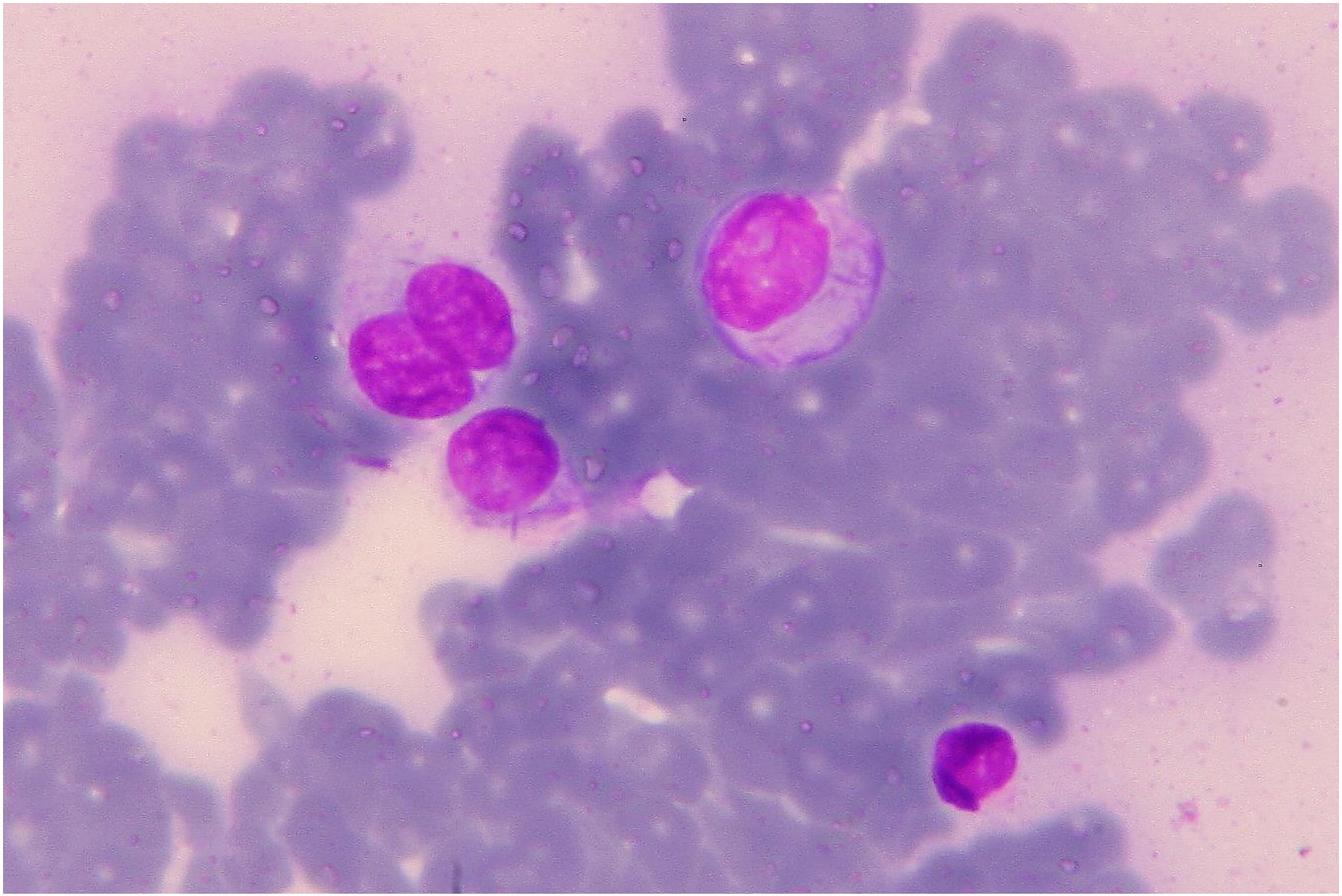

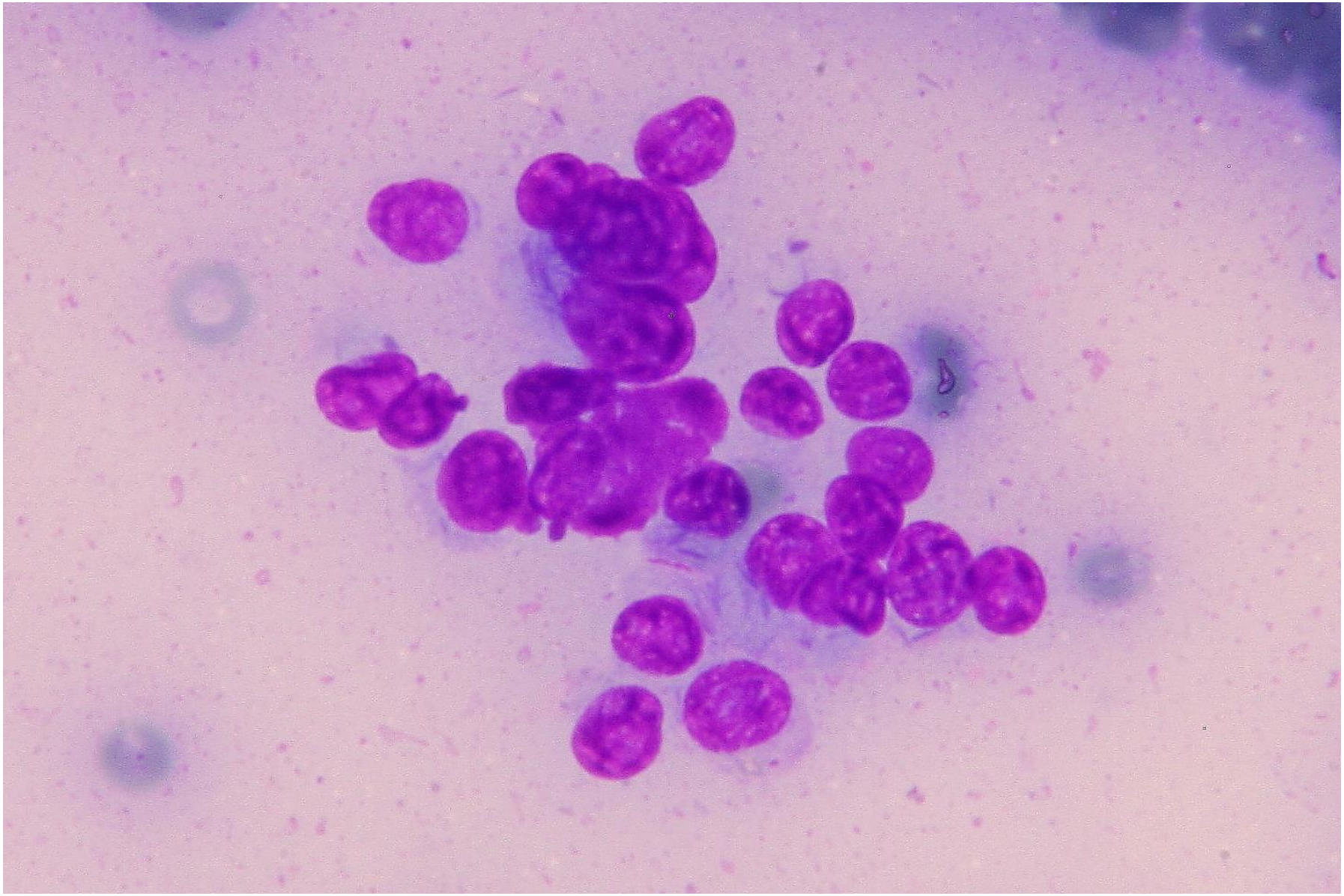

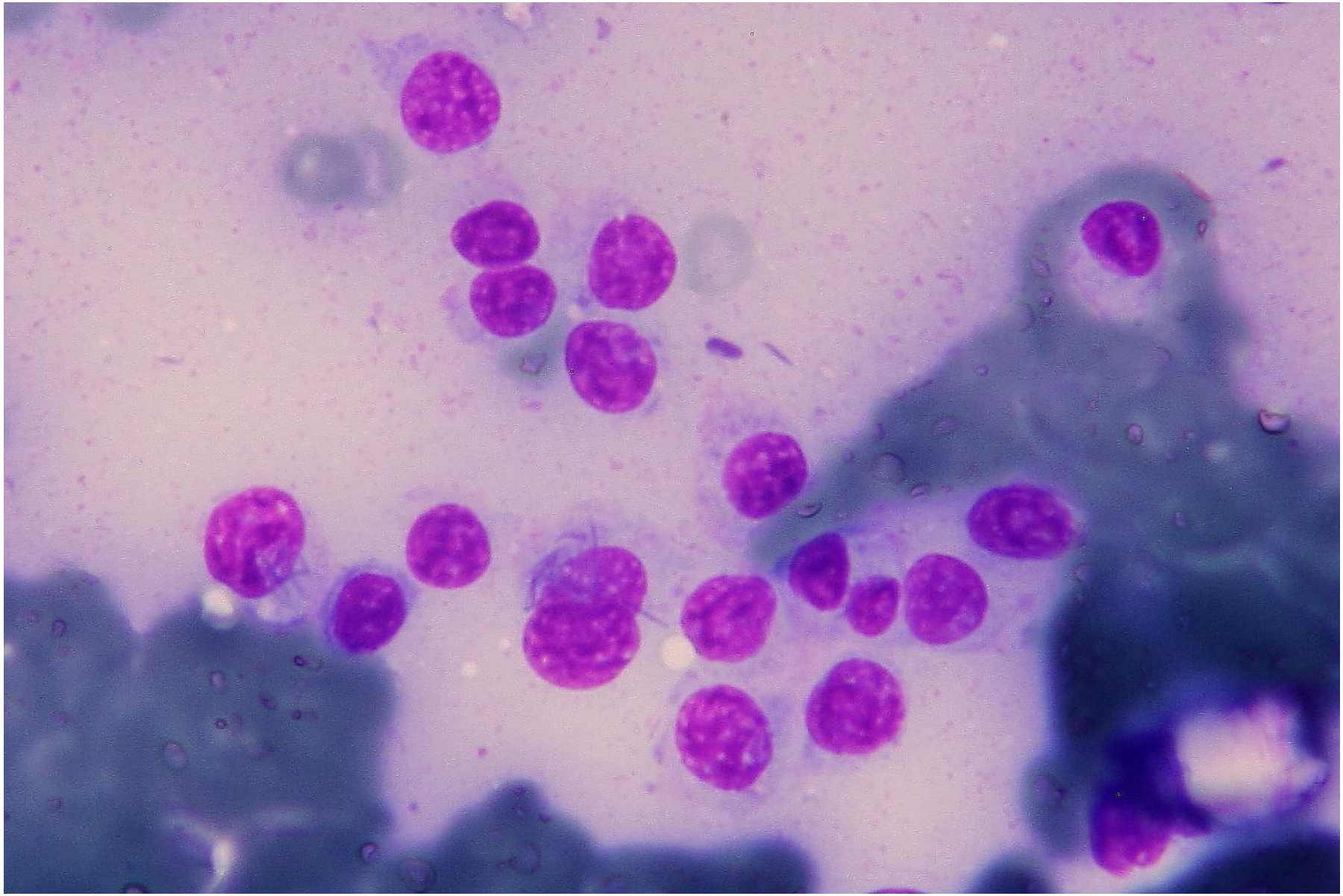

Cytologic findings

- Round cells
  - Plasmacytic appearance
  - Arcoplasma
  - Flame figures
  - Bluish, needle-shaped cytoplasmic structures
    - Cytoplasmic **Auer rods**
- Eccentric nuclei
  - Anisokaryosis
  - Frequent double nuclei

Diagnosis

- Cytologic diagnosis
  - Round cell neoplasia, more likely extramedullary plasmacytoma
- Histologic diagnosis
  - Round cell neoplasia, more likely extramedullary plasmacytoma
  - Focal involvement of phalanx bone
  - Lymph node: hyperplasia, no evidence of metastasis
    - IHC: MUM1 +++

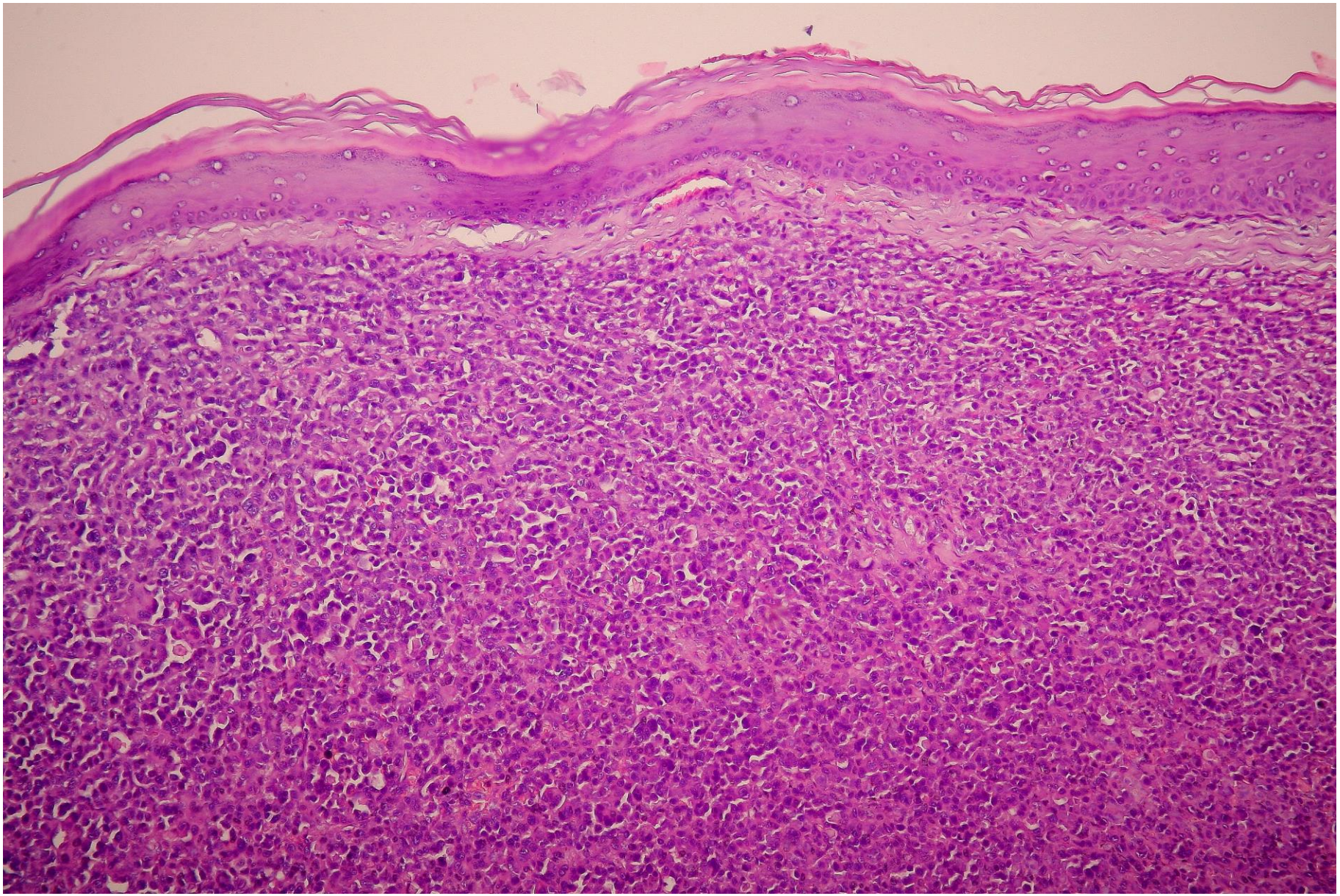

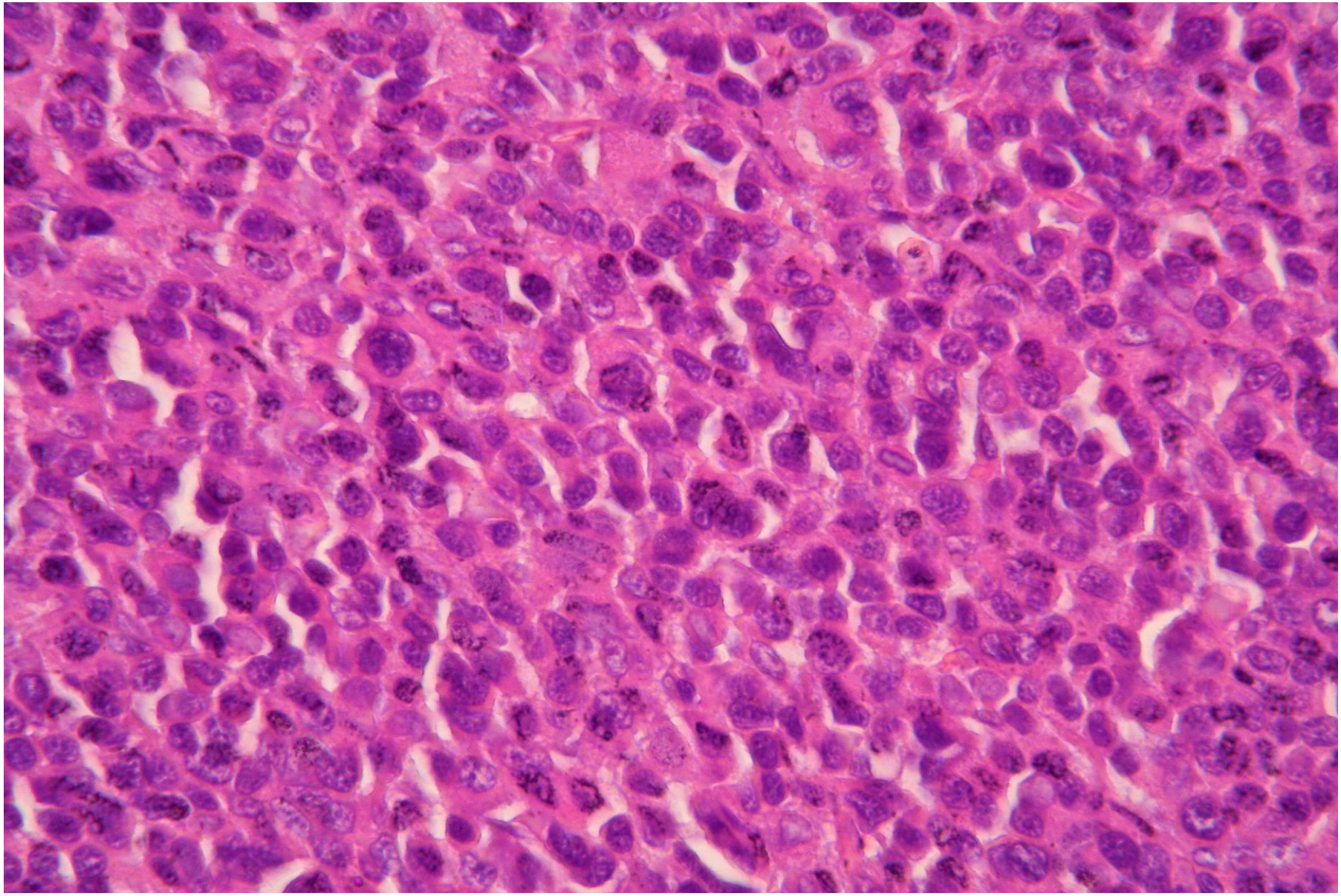

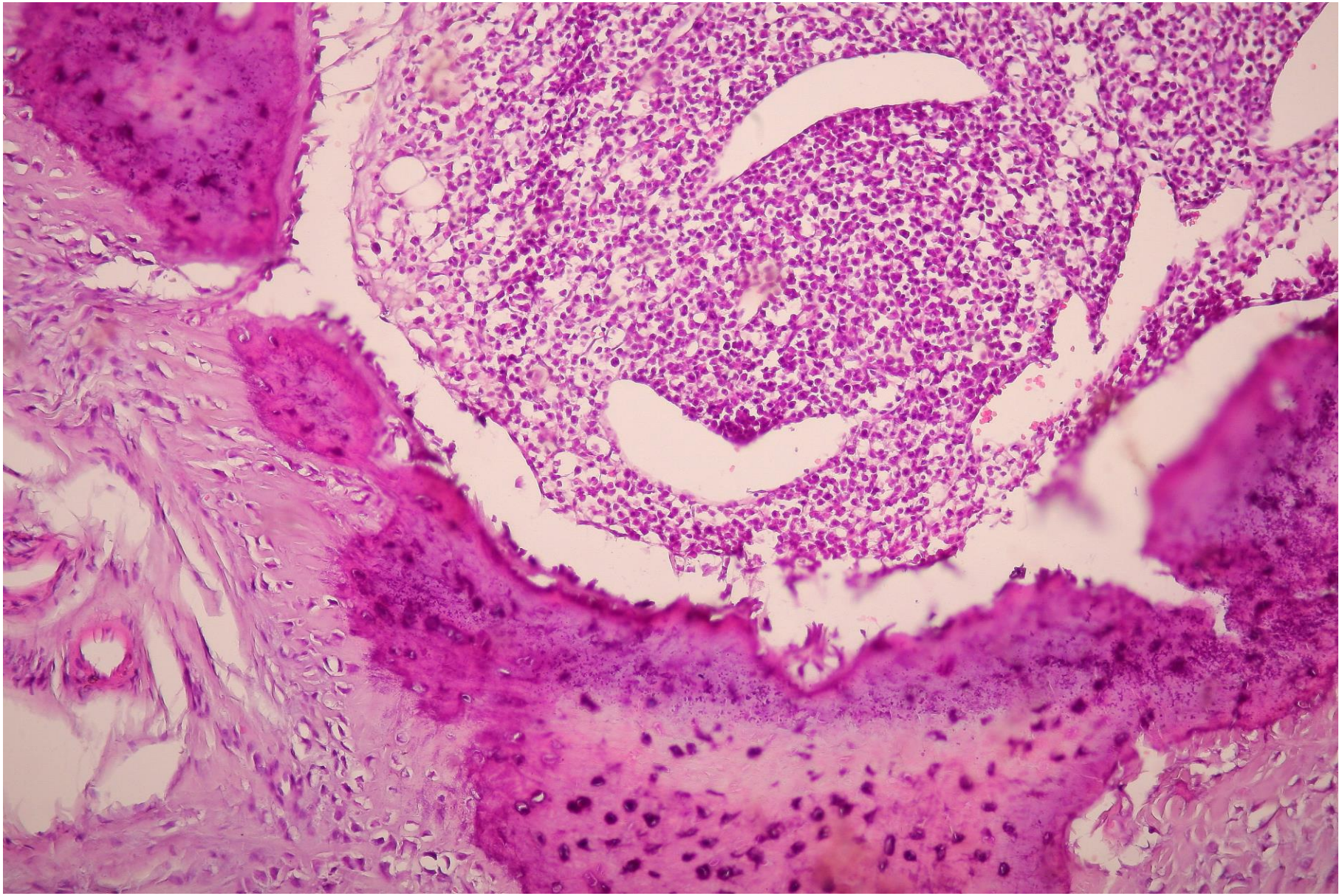

Discussion

- Auer rods are needle-shaped basophilic, cytoplasmic bodies
- In human being they are described in many lympho and plasmaproliferative disorders
  - Multiple myeloma
  - Chronic lymphocytic leukemia
  - Acute myeloid leukemia
- The composition of these inclusions is uncertain, some authors suggest a lysosomal origin (Zhanxi Gao, 2019), but others(Hristov, 2010; O'Peters 1984) hypothesize they are abnormal immunoglobulins which precipitate in the cytoplasm

Discussion

- Extramedullary plasma cell tumor is generally benign, despite the appearance of the cells
- Subclassification, based on the variable morphologic features: (according with Cangul et al. 2002)
  - Hyaline type
  - Mature type
  - Cleaved type
  - Asyncronous type
  - Polymorphous-blastic type
- No significant correlations were observed between the cell type and the location of the tumour, presence of amyloid or prognosis

Discussion

- In our dog staging of the neoplasia was negative
- The only malignant feature was a focal infiltration of phalangeal bone.
- After excision (5 months) no signs of recurrency or metastasis are been detected

- Should Auer bodies be indicative of aggressive behaviour in dog too?

Case #7

- 3-year-old, female, mixed-breed dog
- Abdominal effusion
  - Hemorrhagic appearance
    - TCC: $6{,}1 \times 10^6$
    - TP: 5,9 g/dl
- Flushing
- MGG stain

CBC (automated count) and biochemistry

RBC	**$4,8x10^6$**	5,70	7,90
HGB	**11,3g/dl**	12,0	18,0
HCT	**31,3%**	37,0	55,0
MCV	**65fL**	60,0	76,0
MCH	**23,5pg/L**	20,0	25,4
MCHC	**36,2g/dl**	32,0	39,0
RDW	12,5%	12,0	16,0

WBC	**$27,7x10^3$**	6	11
Neutrofili	91	2,5	7,0
Linfociti	1	1,3	5,5
Monociti	5	0,06	0,25
Eosinofili	1	0,07	0,8
Basofili	2	0	0,1

PLT	**$90x10^3$**	120	350
MPV	8fL	7,9	12,3
PDW	11.3%	10	27
STIMA	Not ad		

CPK	110 U/L	90	320
AST	**70 U/L**	15	35
ALT	**130 U/L**	32	87
ALP	**90 U/L**	19	70
GGT	**4 /L**	0,1	0,6
TBILI	**0,3 mg/dl**	0,14	0,26
TP	**5.1 g/dl**	6,3	7,8
ALB	**2,9 g/dl**	3	4
GLO	**2.2 g/dl**	3	4,5
A/G	1,3	0,72	1.25

CHO	140 mg/dl	95	210
TRIG	30 mg/dl	19	81
BUN	50 mg/dl	32	64
CRE	1,7 mg/dl	0,95	1,85
GLU	90 mg/dl	86	116
CA	9.1 mg/dl	9,3	11,2
P	4,1 mg/dl	3,5	6,6
Cl	110 mg/dl	112	119
Na^+	150 meq/L	145	152
K^+	4,5 meq/L	3,5	4,7

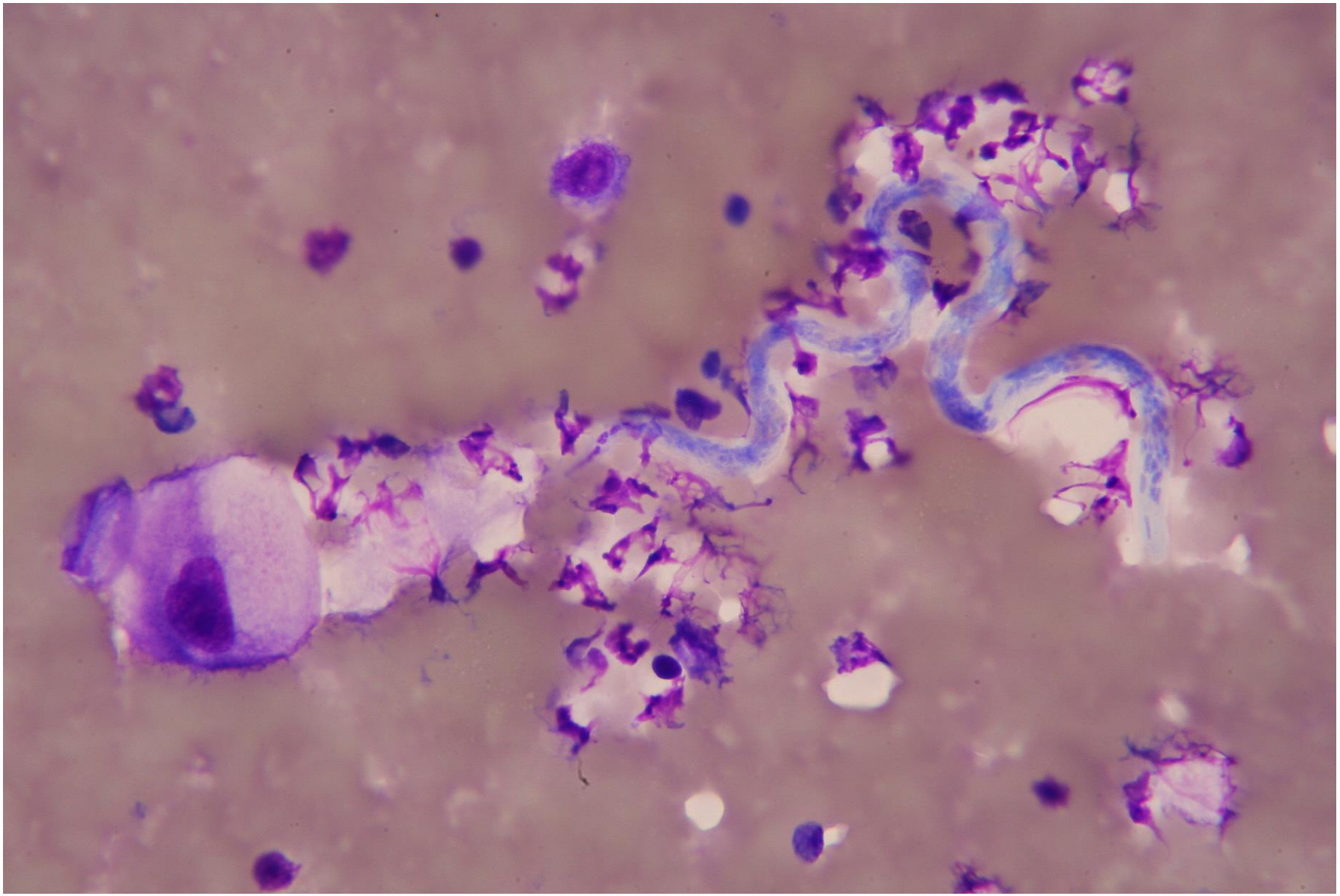

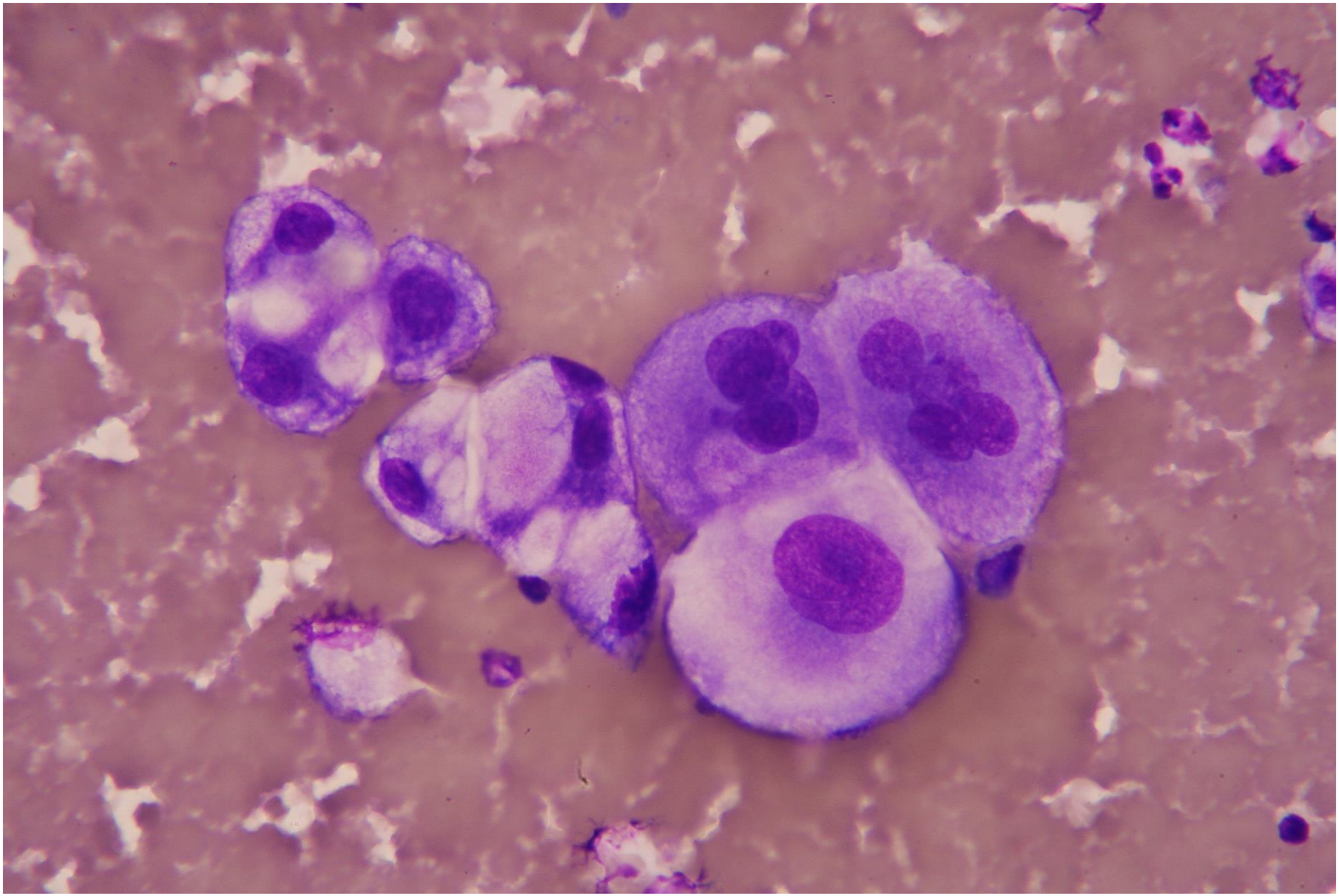

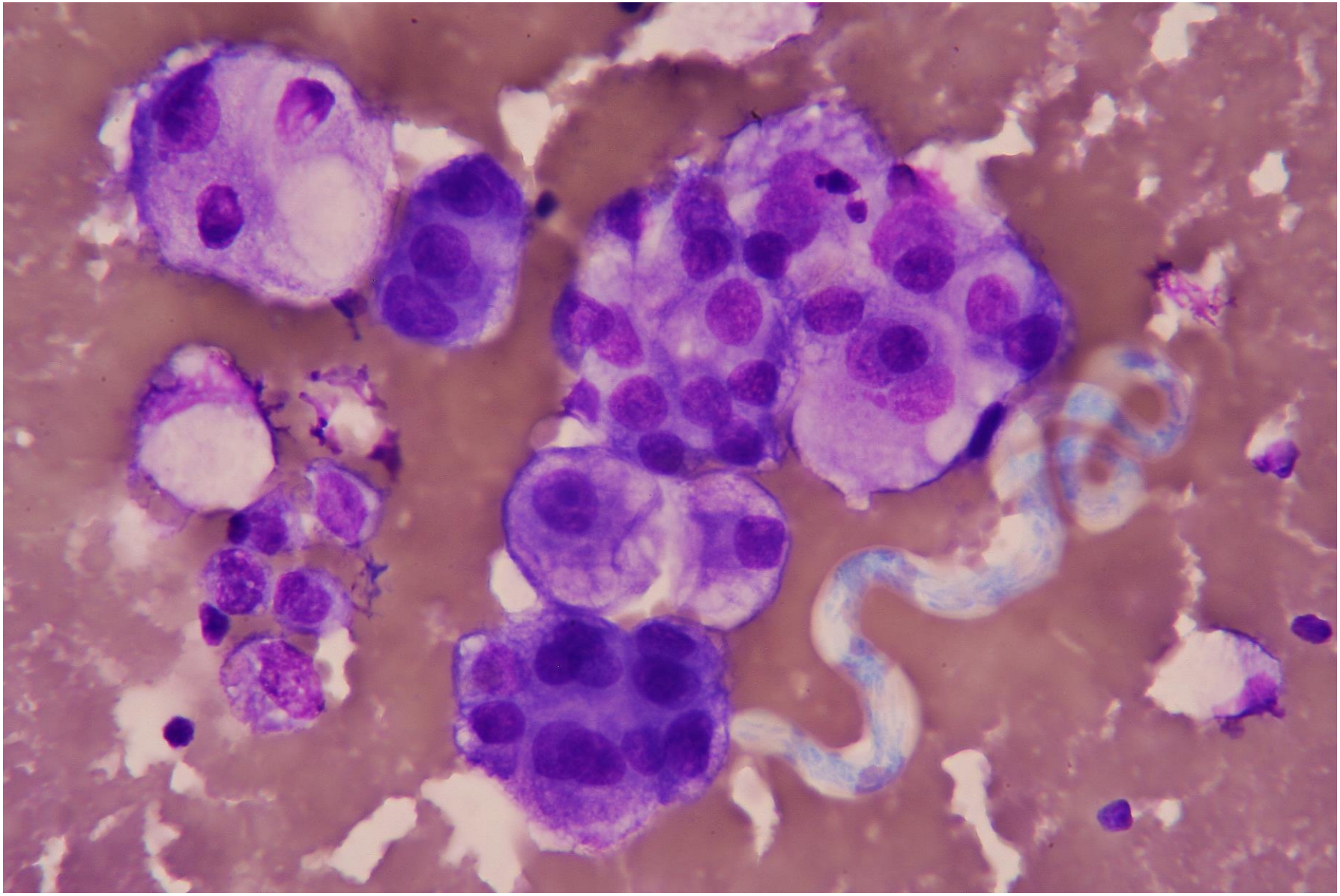

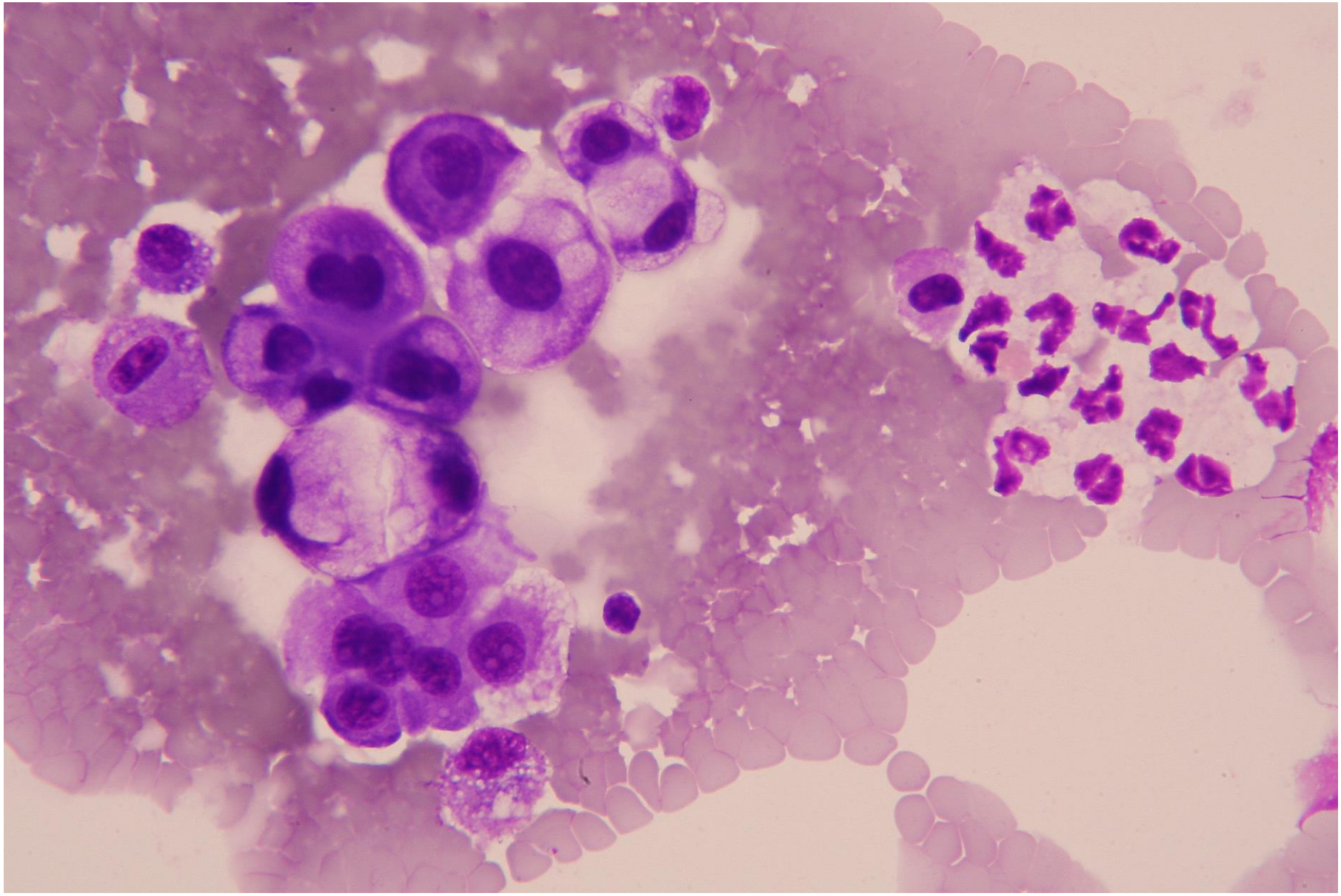

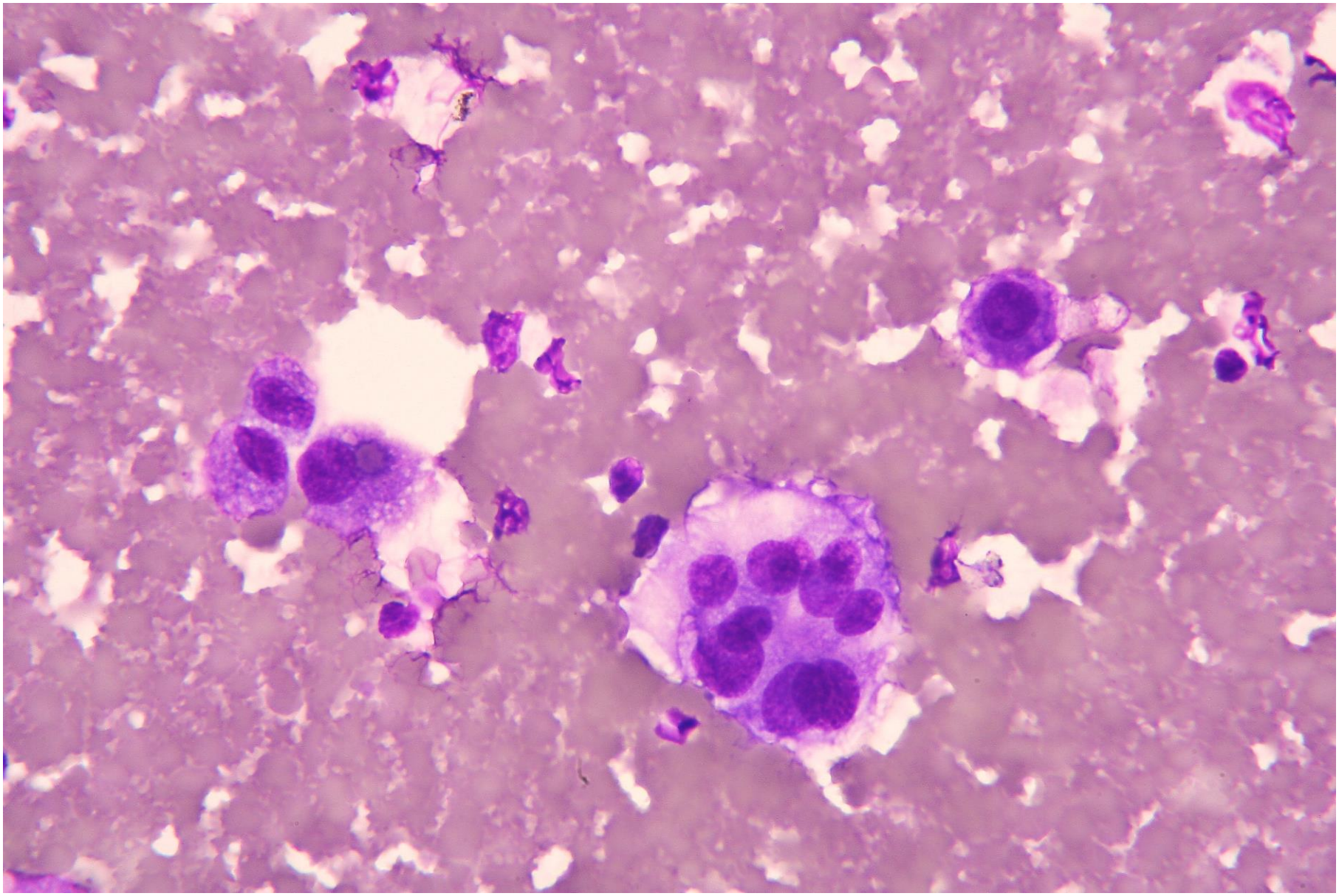

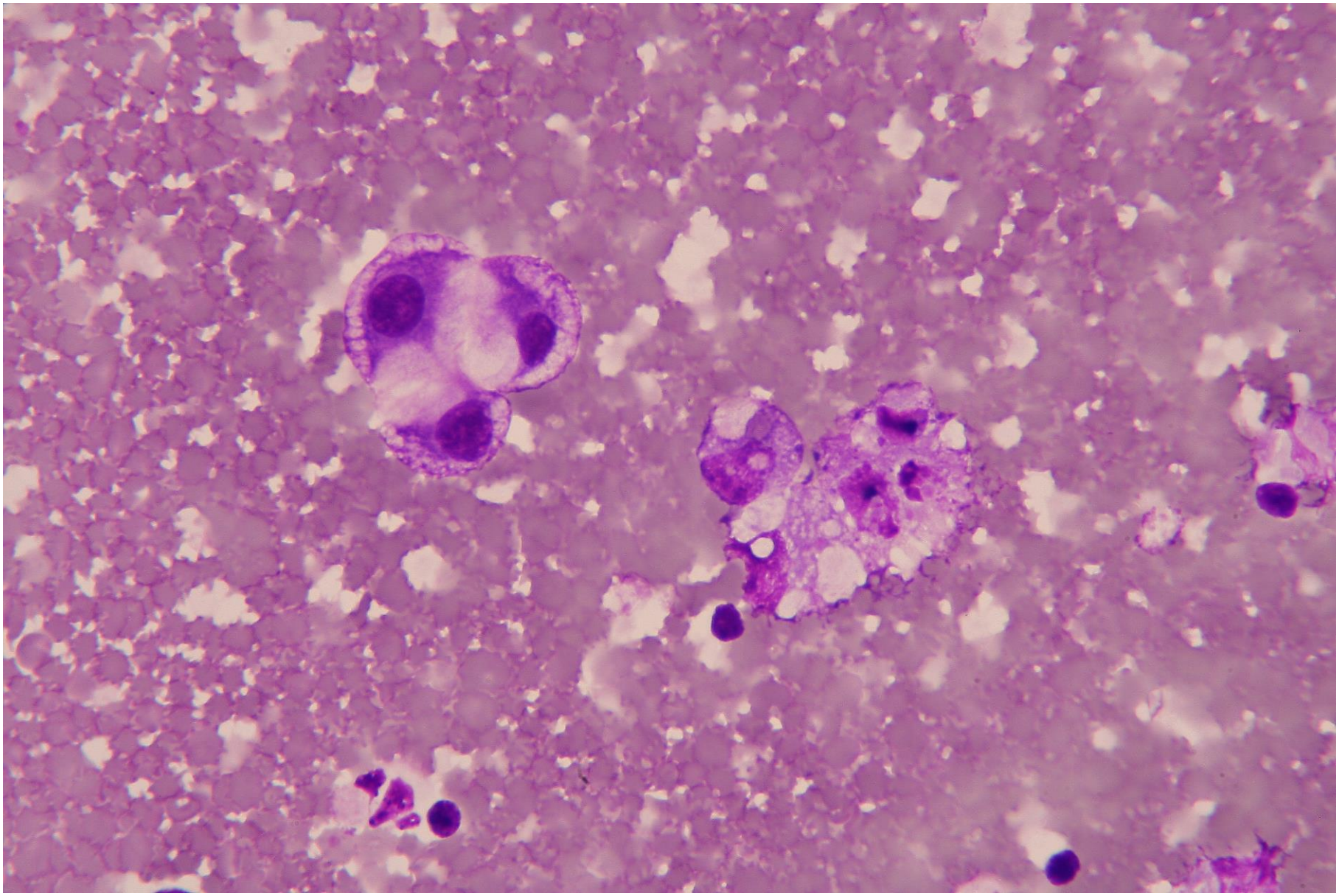

Cytologic findings

- Bloody background
  - Macrophagic erythrophagocytosis
- Reactive mesothelial cells
- Many leukocytes (may we call this “inflammatory cells”?)
- Microfilariae

Diagnosis

- Hemorrhagic effusion with heartworm infection
  - Suggested subacute (or chronic) peritoneal hemorrhage
  - No cytological evidence of platelet
  - Presence of macrophagic erythrophagocytosis
  - No evidence of phagocytosis of heme-breakdown pigments

- SNAP Heartworm RT test: **positive**
  - The SNAP® Heartworm RT Test is an in vitro test for the detection of **Dirofilaria immitis** antigen in canine serum, plasma, or anticoagulated whole blood.
    - Sensitivity: 84%
    - Sensibility: 97%
    - Accuracy: 86%

Comments

J Parasit Dis (July-Sept 2017) 41(3):805–808
DOI 10.1007/s12639-017-0892-8

CrossMark

ORIGINAL ARTICLE

JPD

Microfilaruria by *Dirofilaria immitis* in a dog: a rare clinical pathological finding

Marina Mitie Monobe[1] · Rodrigo Costa da Silva[1] · João Pessoa Araujo Junior[2] · Regina Kiomi Takahira[3]

- “The obstruction of blood flow by the parasite leads to congestive right heart failure, which cause abdominal effusion”.
- “Moreover, microfilariae may occlude and rupture small vessels. In this way, the microfilariae are released in atypical places, i.e., peritoneal and abdominal effusion and, even, lower urinary tract”

Comments

- No others published data about microfilariae in effusions of dog with D.immitis infection (better: not able to retrieve it...)
- Description of microfilariae in ascitic fluid in **D. Repens** infection
  - Katarzyna Pasdzior-Czapulaet al. Dirofilaria repens-An etiological factor or an incidental finding in cytologic and histopathologic biopsies from dogs. Vet Clin Pathol, 2018 Jun;47(2):307-311
- Hemorrhagic effusion described in cat:
  - Biasato et al. Pulmonary artery dissection causing hemothorax in a cat: potential role of Dirofilaria immitis infection and literature. J Vet Cardiol, 2017(19):82-87
    - Investigation of the effusion not performed
- «Hemorrhagic effusion may be seen with... Heartworm infection»
  - Valenciano AC, Arndt TP and Rizzi TE, in Cowell and Tyler's Diagnostic Cytology and Hematology of the Dog and Cat, IVth ed, 2014(260):

Comments

- This dog was not protected with heartworm prophylaxis and lived in heartworm endemic areas
- Which pathological process leads to the presence of microfilariae in the effusion of our dog?
  - Cavitary hemorrhage due to others causes?
  - Active penetration of larvae through the pleura?
  - Mild thrombocytopenia may concur?

Case #8

- 7-year-old, male, Newfoundland dog
- Subcutaneous nodule on the thorax

- FNCS of the lesion
- MGG stain

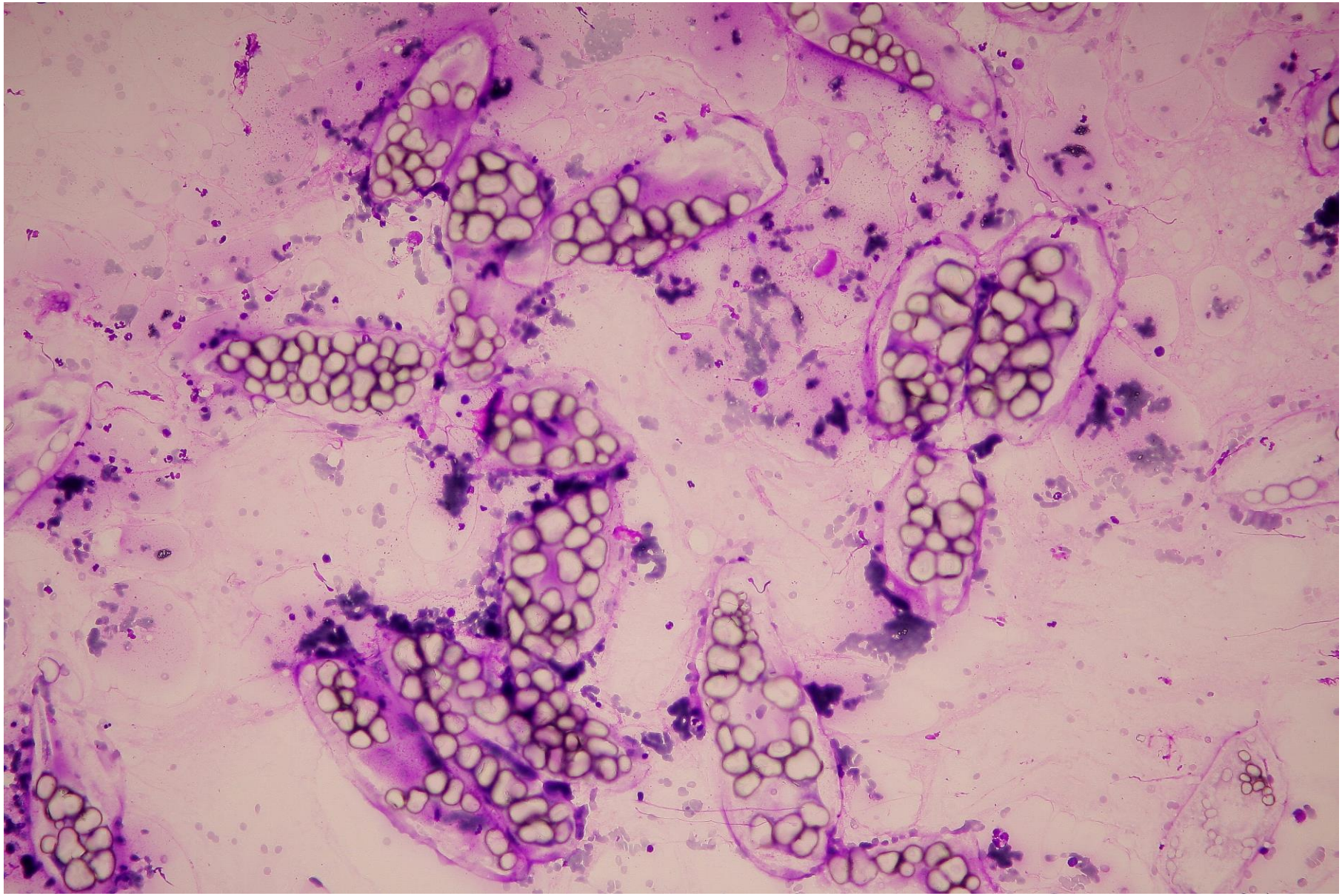

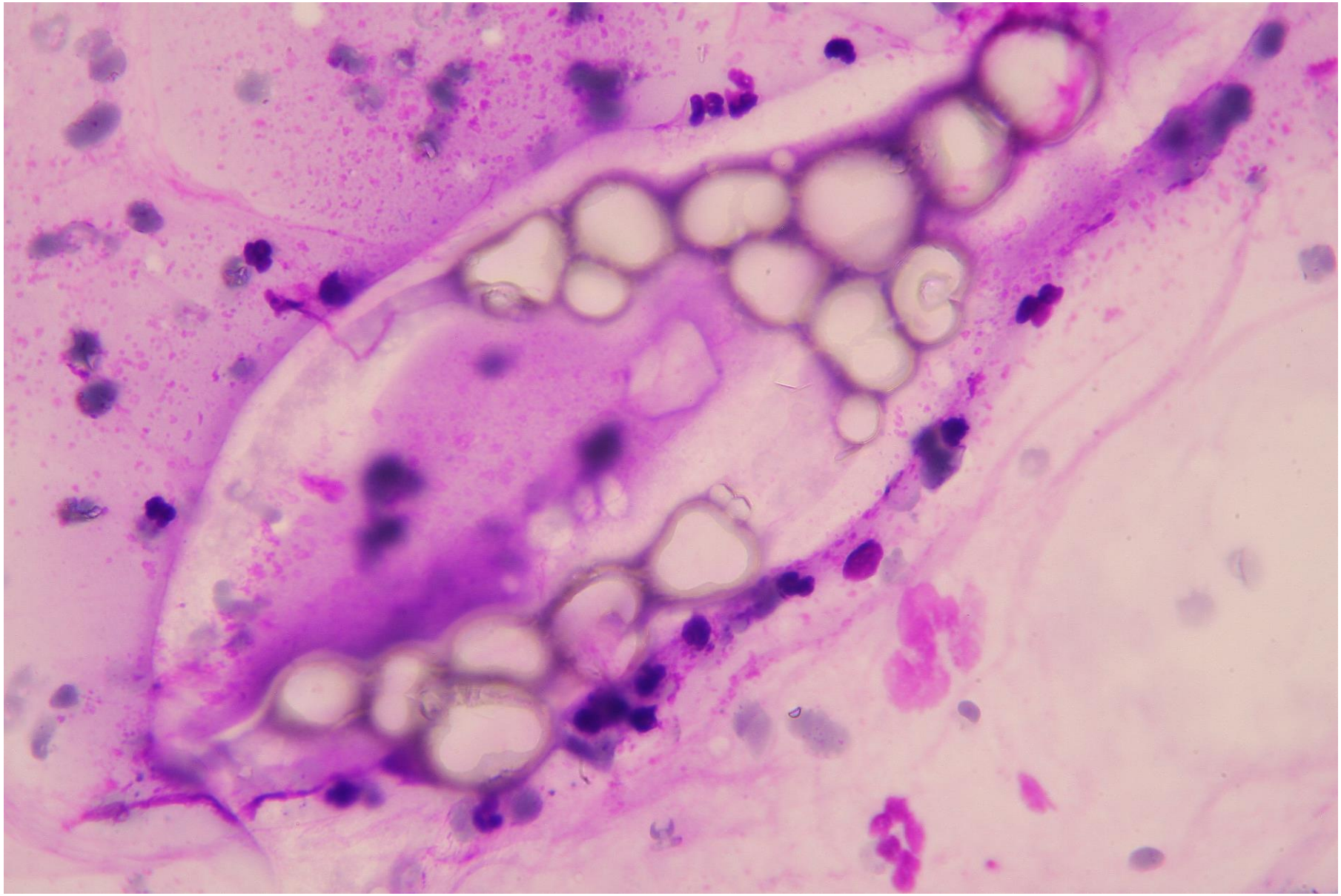

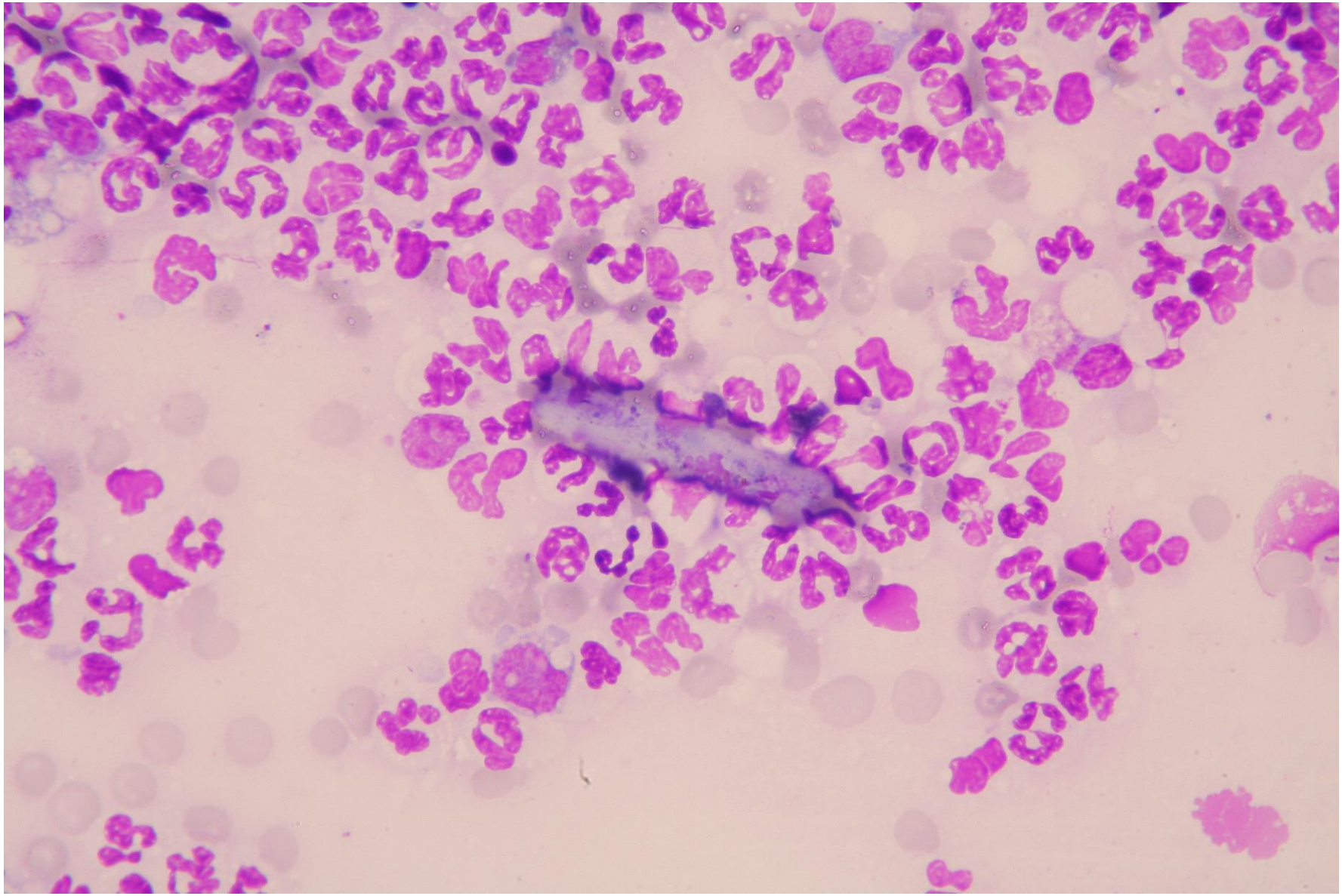

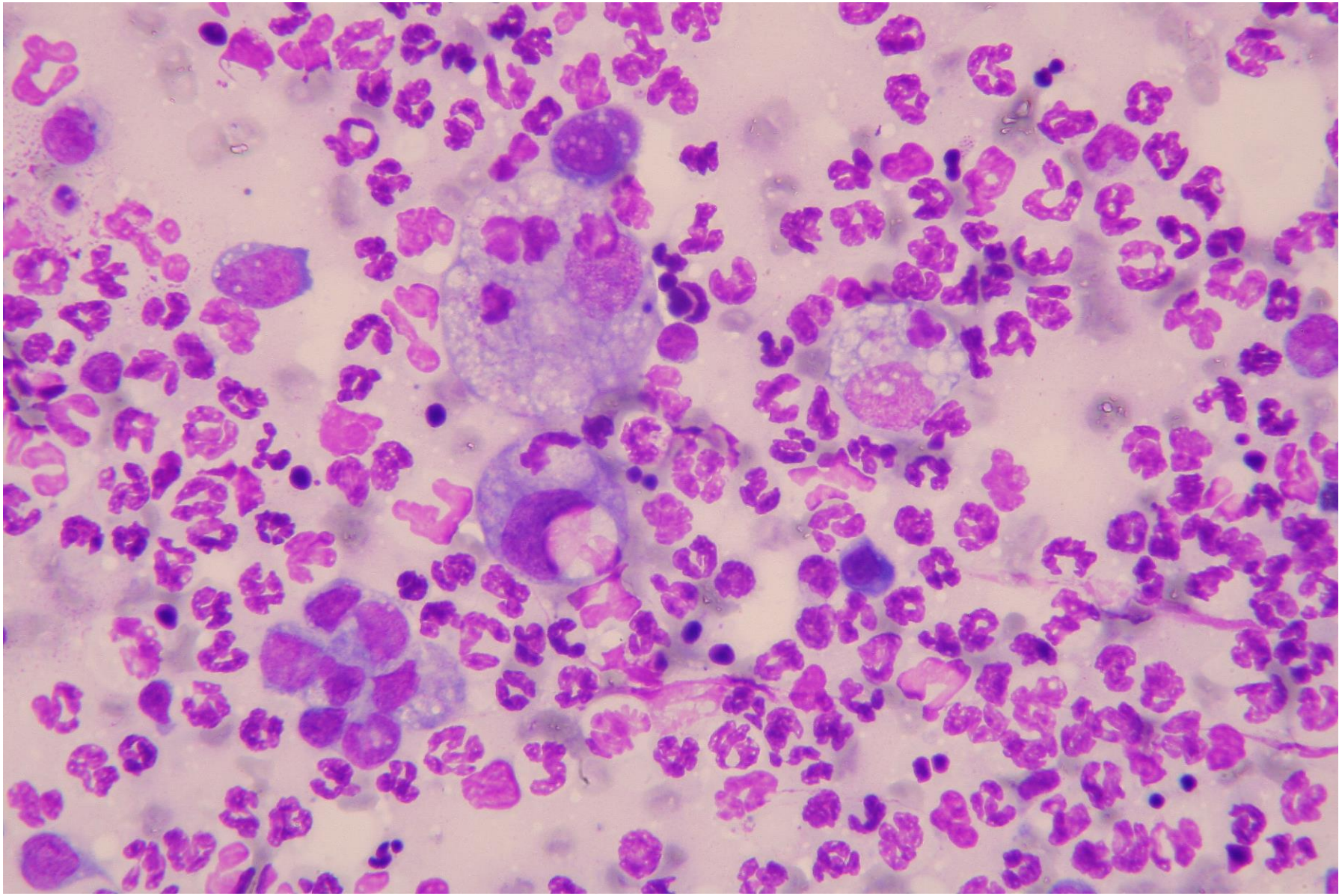

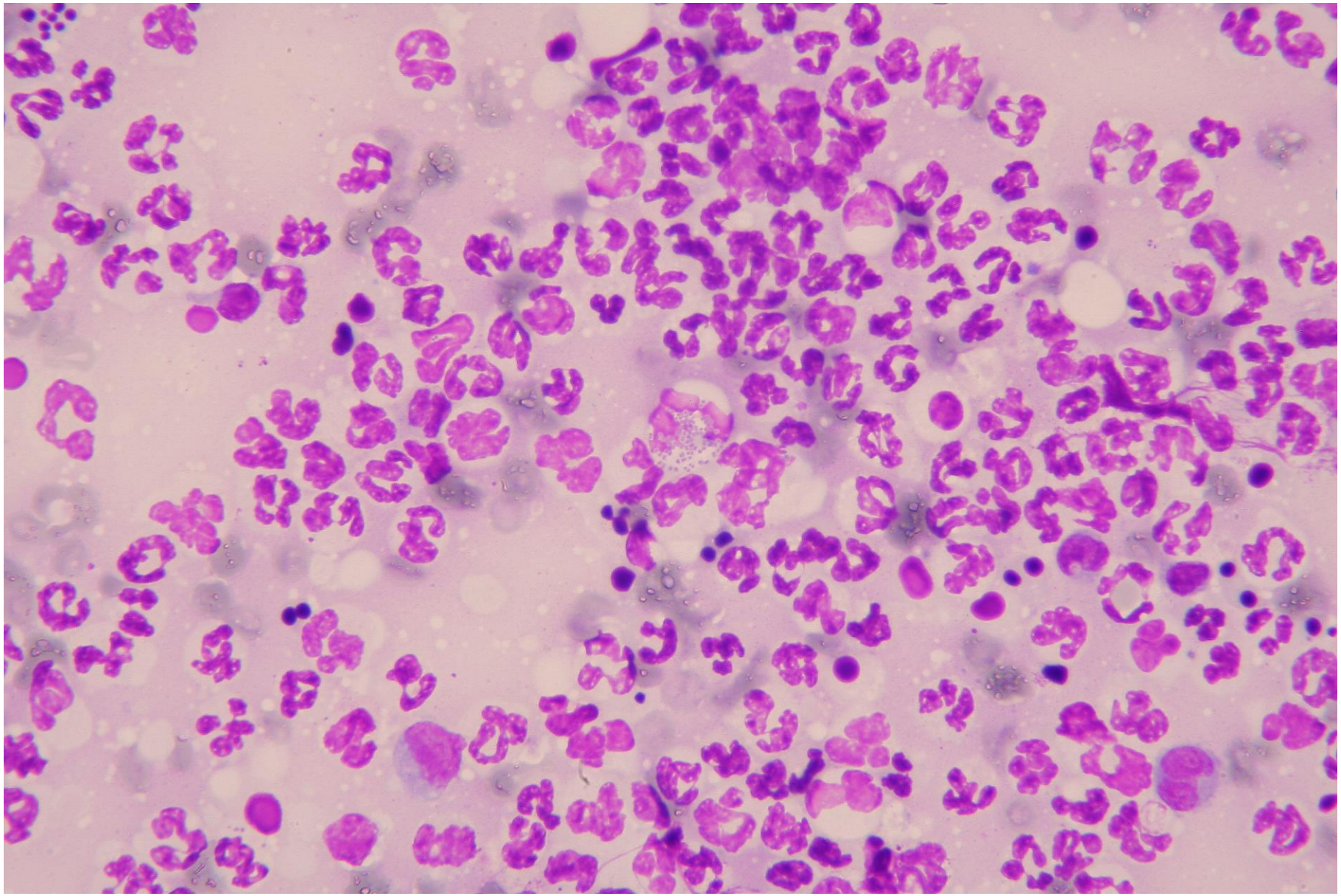

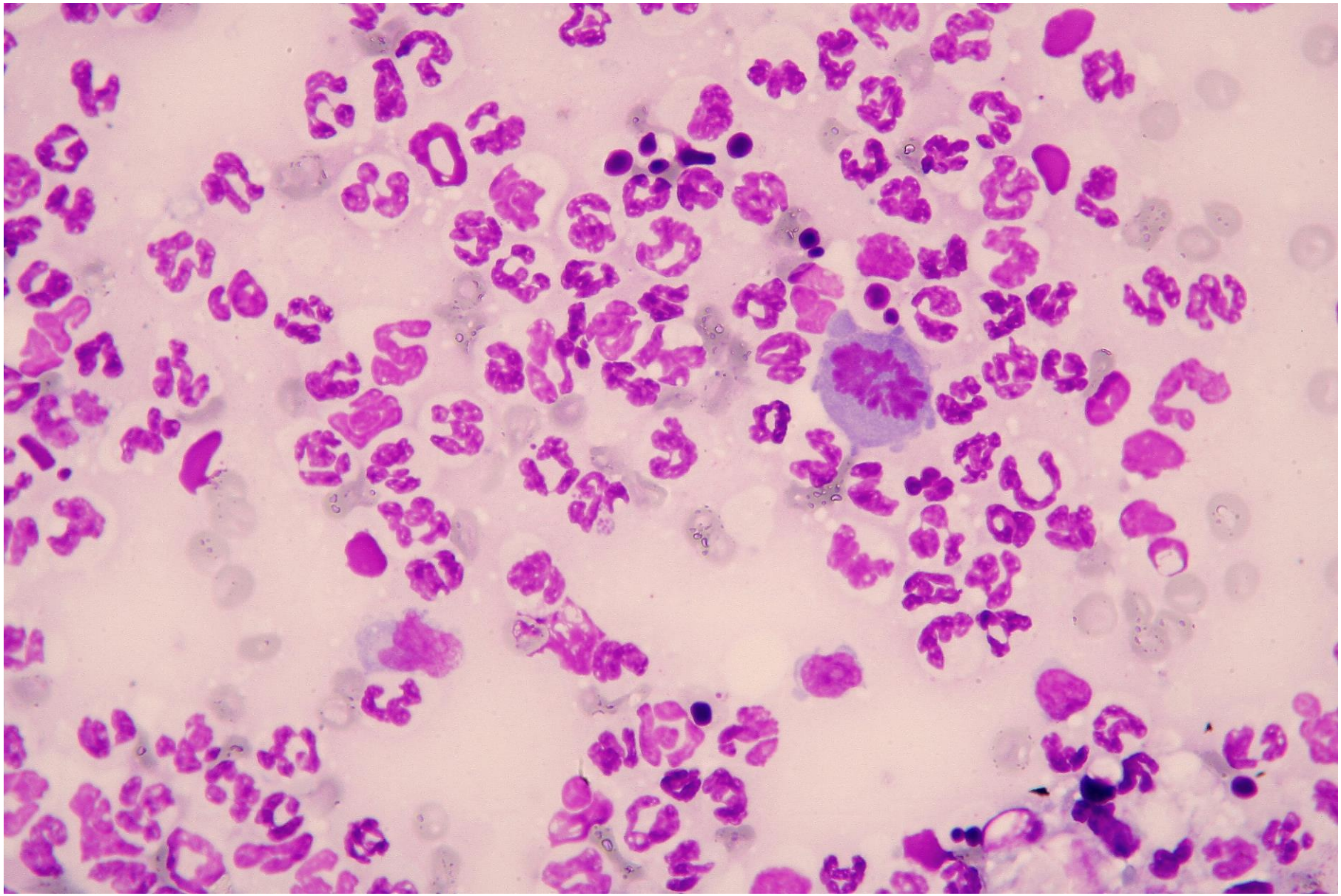

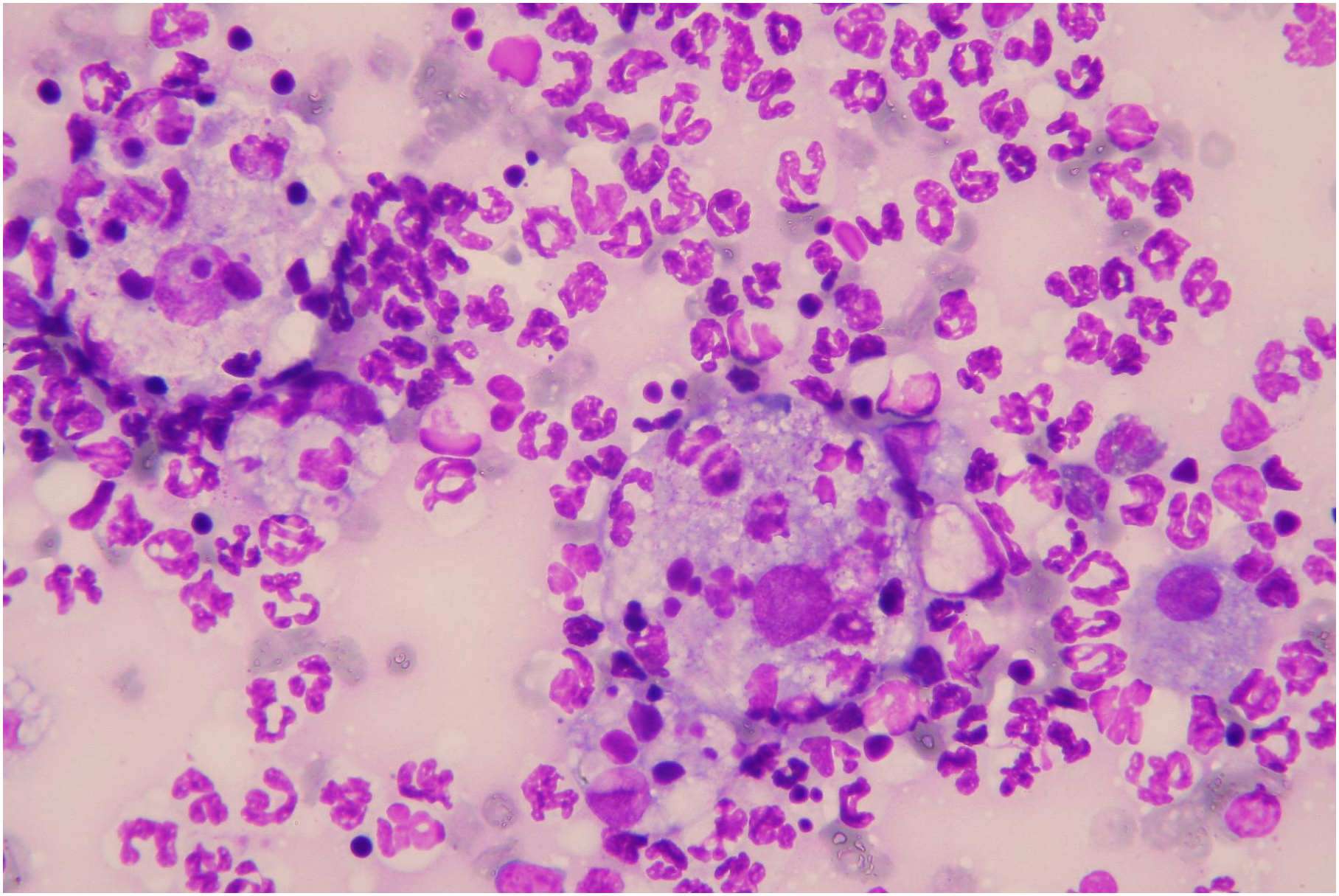

Cytologic findings

- Large birifrangent bodies with small spherules inside
  - Vegetal components?
- Suppurative and macrophagic septic inflammation
  - Occasional neutrophilic phagocytosis of coccoid bacteria

Diagnosis

- Cytologic diagnosis
  - Mixed septic inflammation; vegetal foreign body
- Histologic diagnosis
  - The nodule was surgically removed and submitted for histopathologic examination:
    - Mixed inflammation with large vegetale foreign body

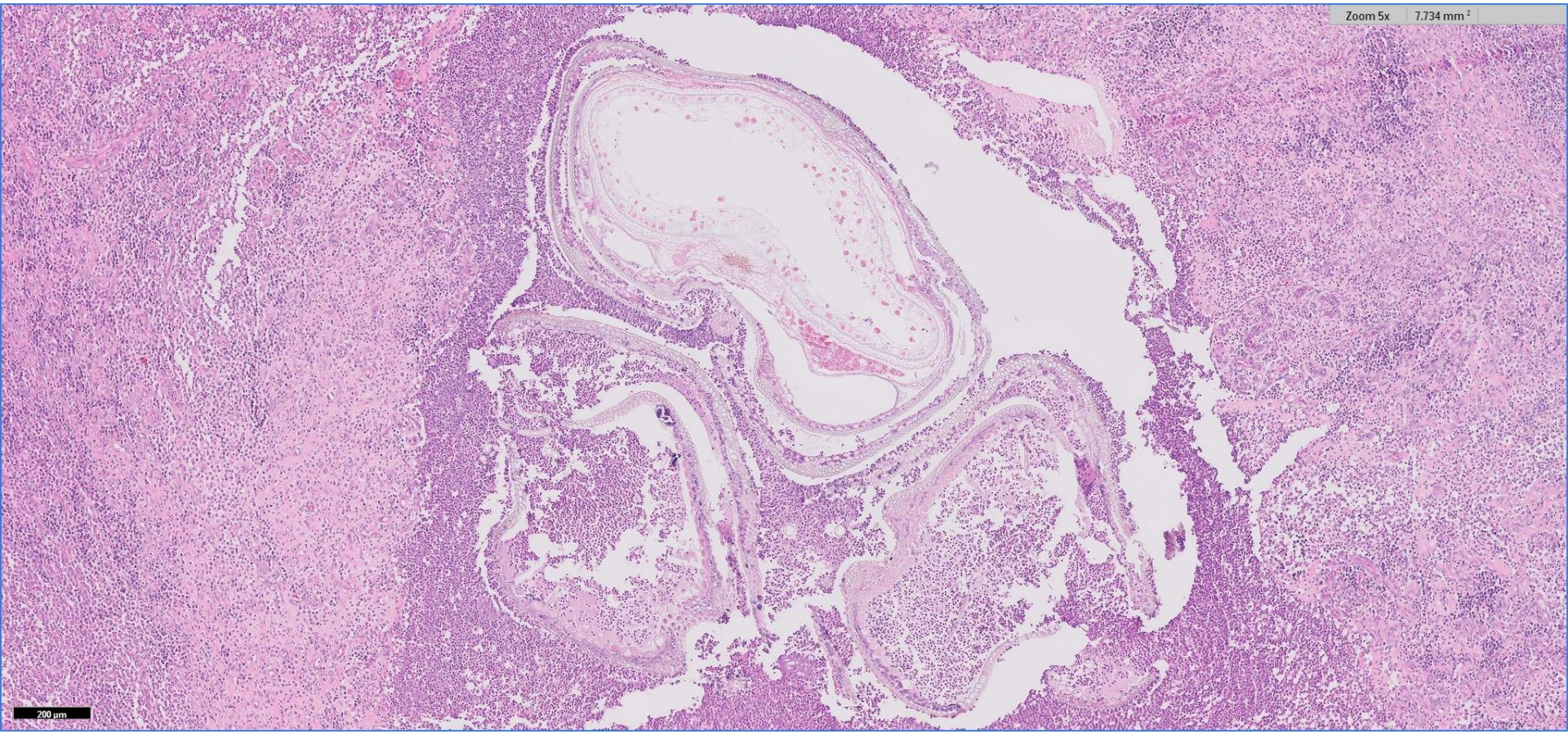
Zoom 5x
7.734 mm ²
200 µm

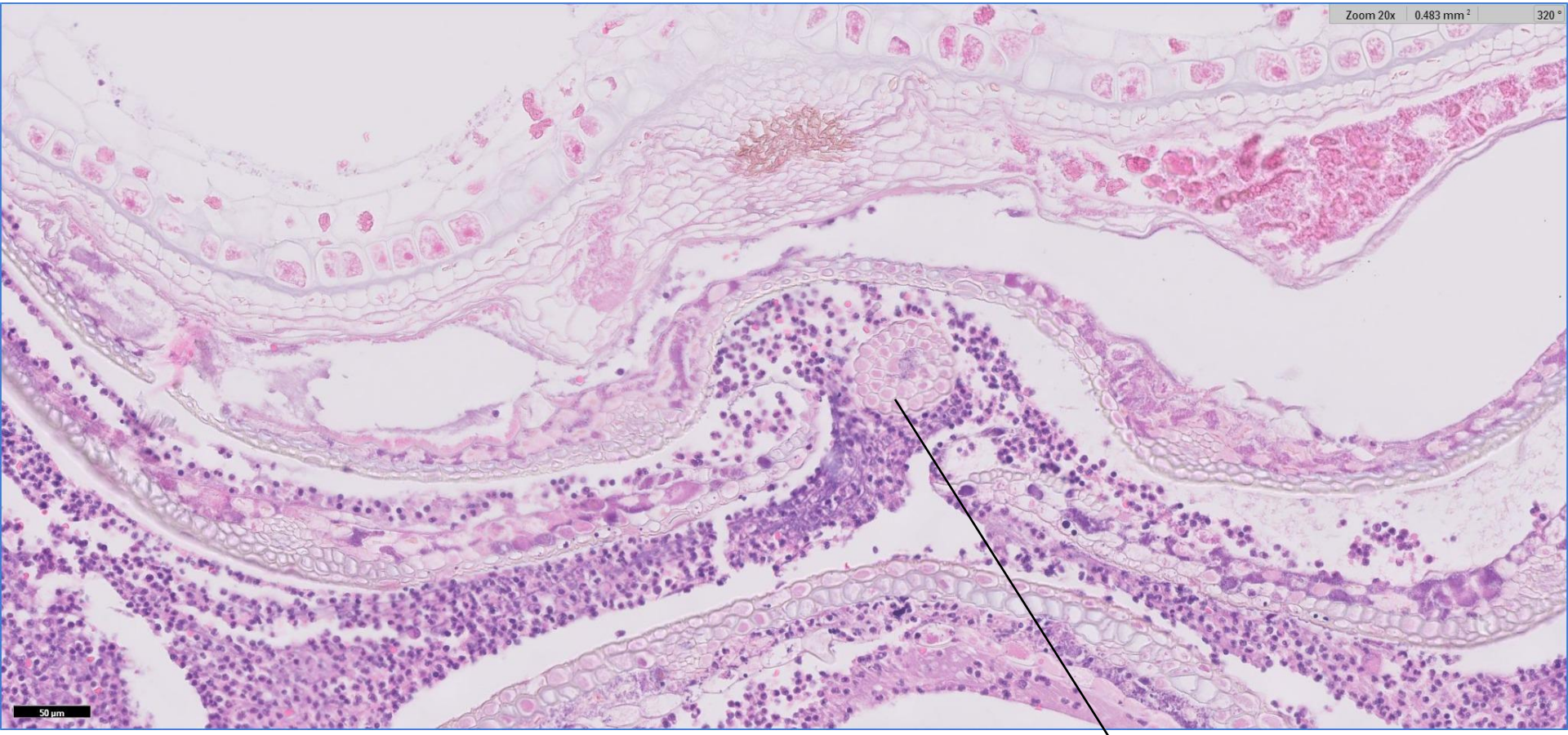
Zoom 20x
0.483 mm²
320 °
50 µm

?

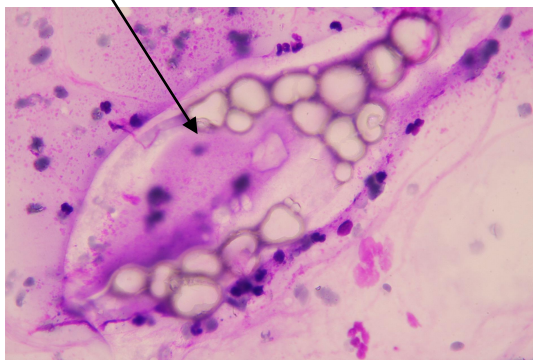

Comment

- Are the large birifrangent bodies observed in cytologic sample recognizable as selected part of the vegetal foreign body?
- Which clinical way to investigate the presence of a foreign body are know and used?
- What is not clear to me:
  - Very slow number of bacteria
  - Mixed inflammation instead that pyogranulomatous inflammation (strange to me!!!)

Case #9

- 2-year-old, DSH, neutered male cat
- FeLV +
- Cutaneous nodules on the thorax and abdomen

- FNCS of the lesions
- MGG stain

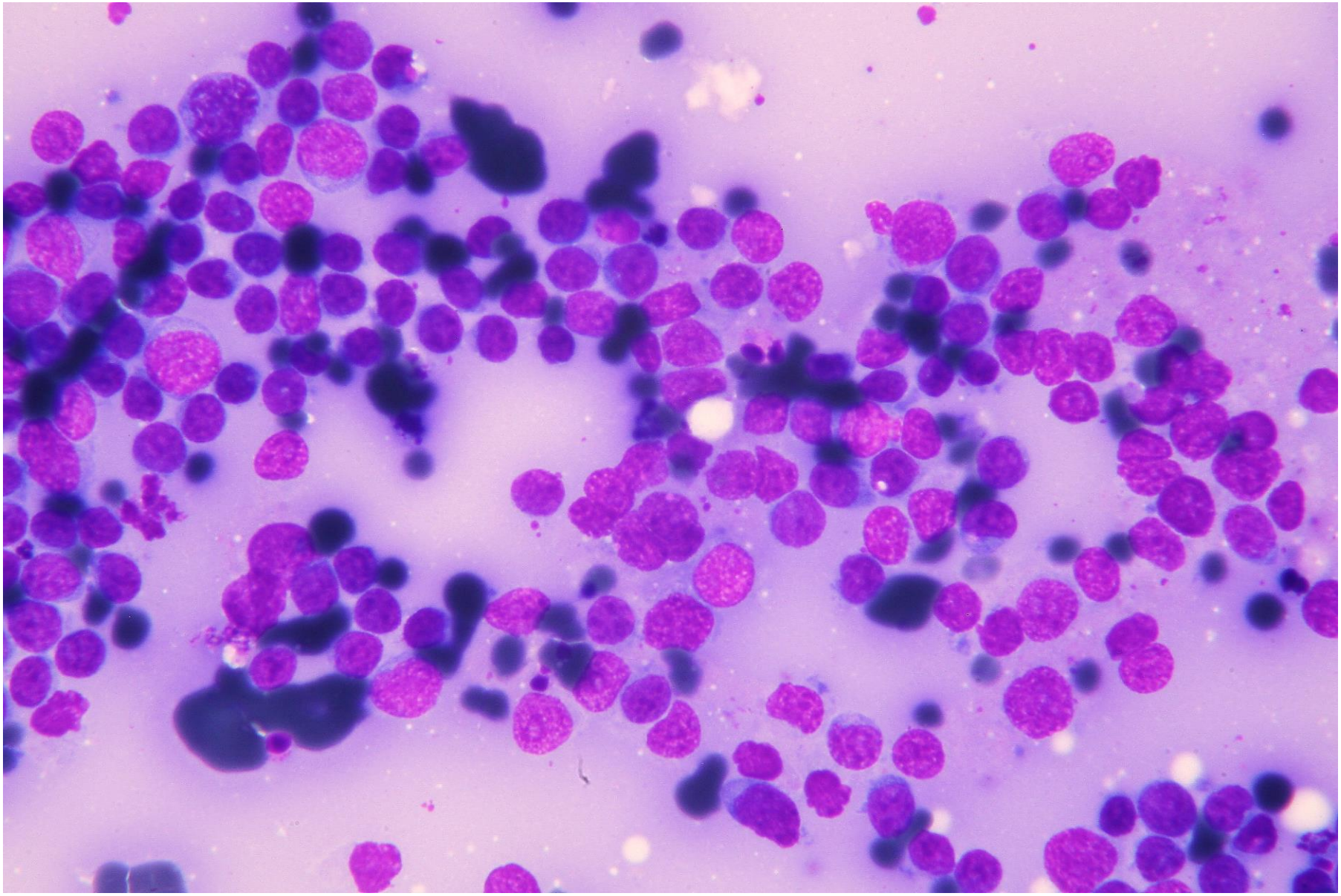

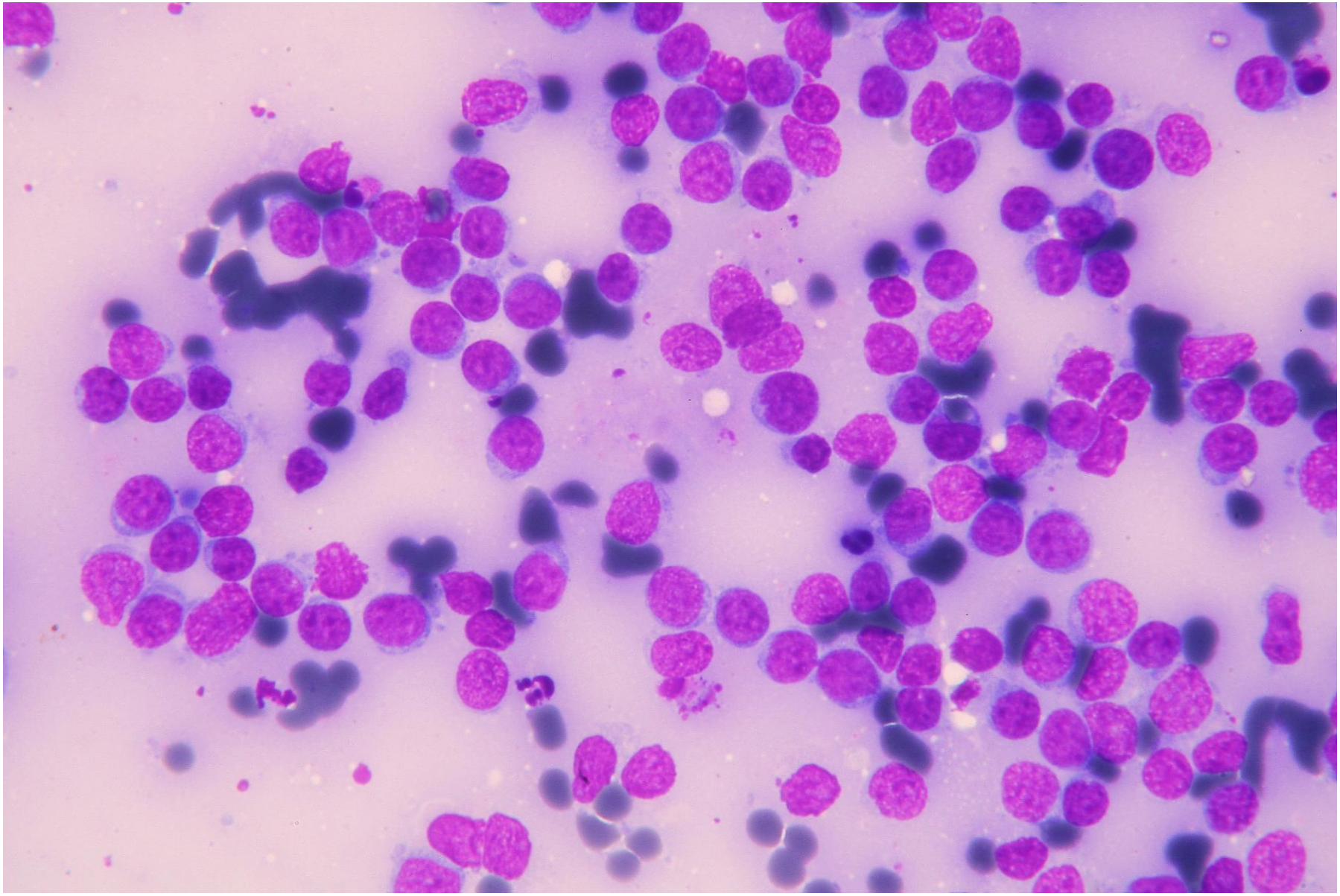

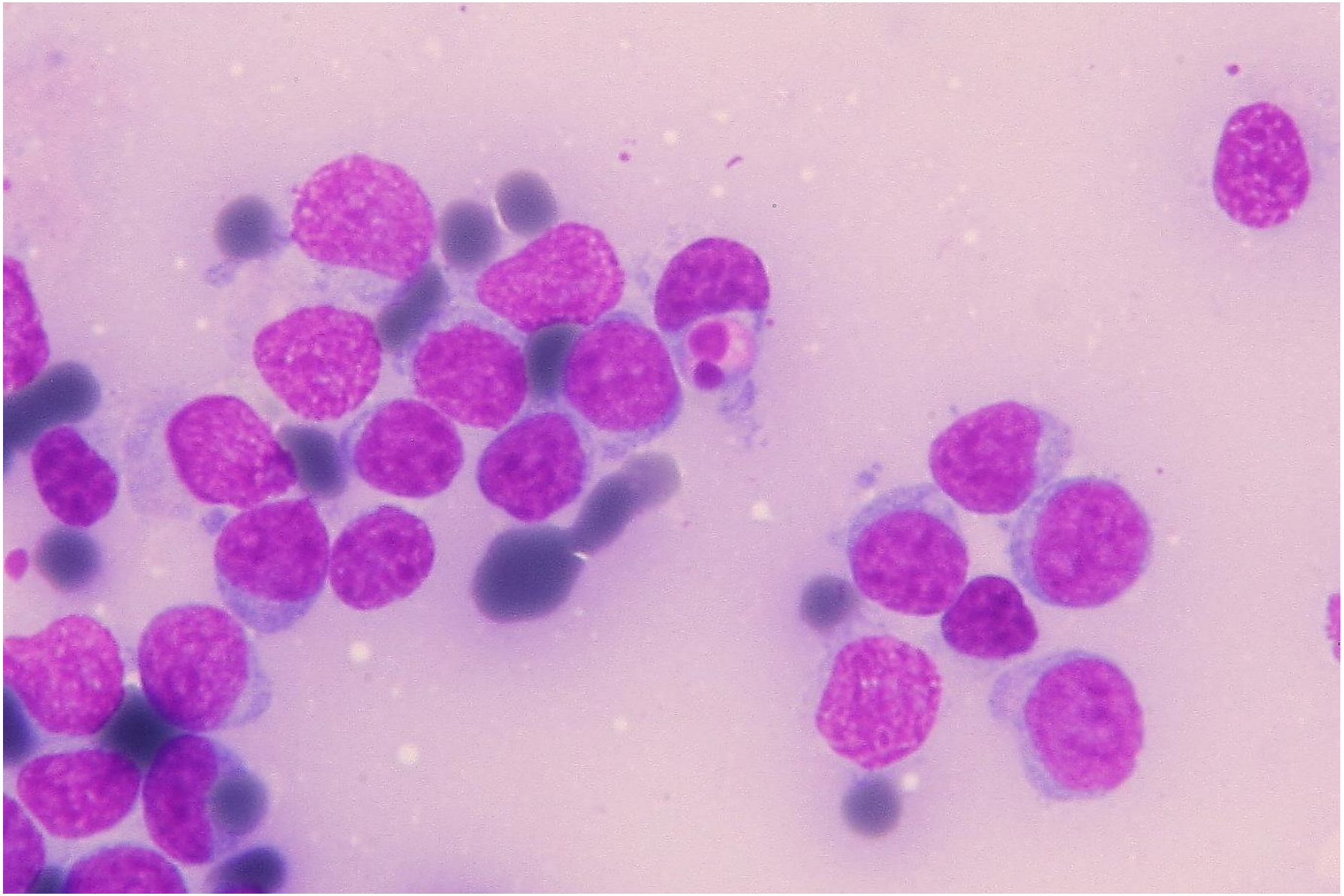

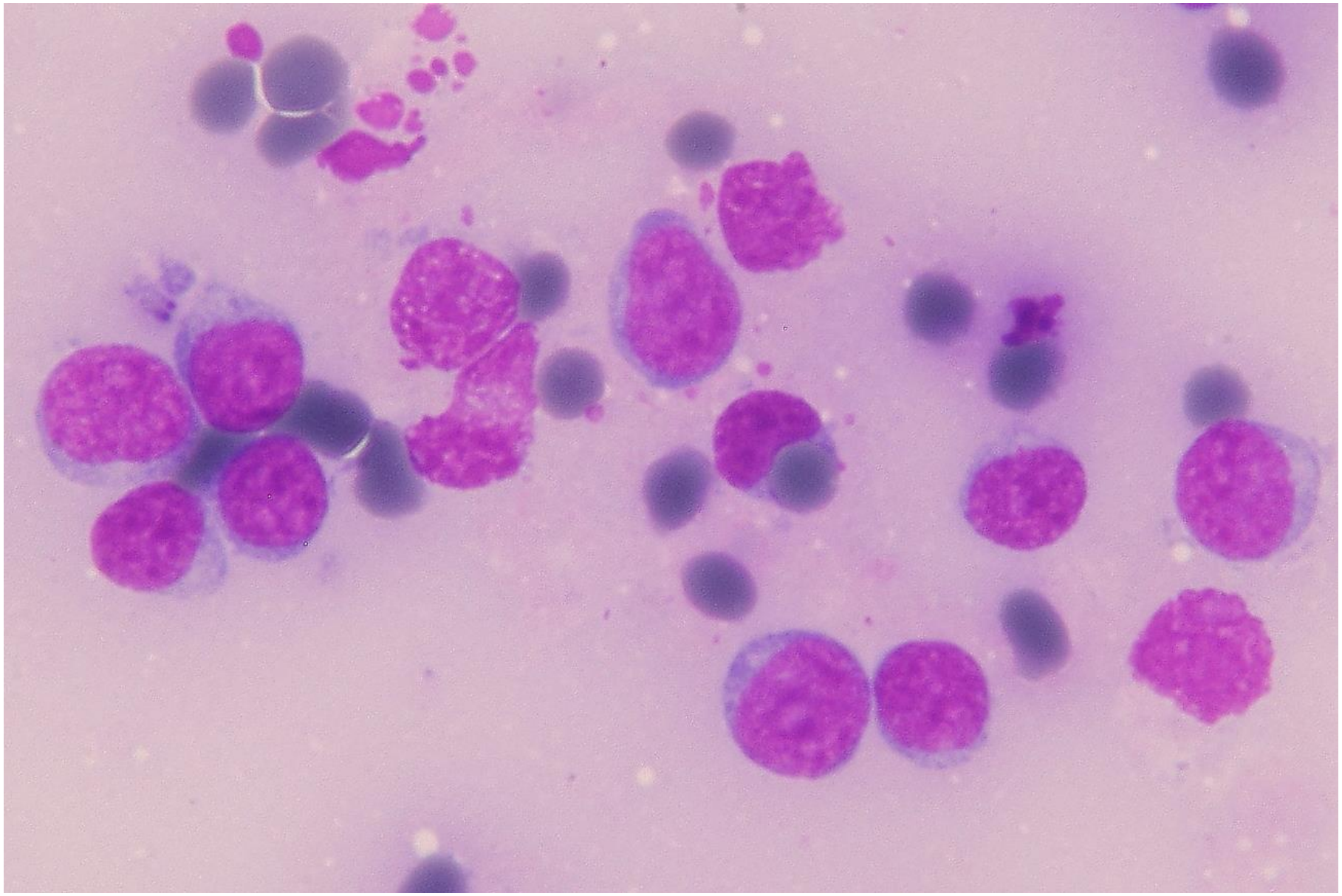

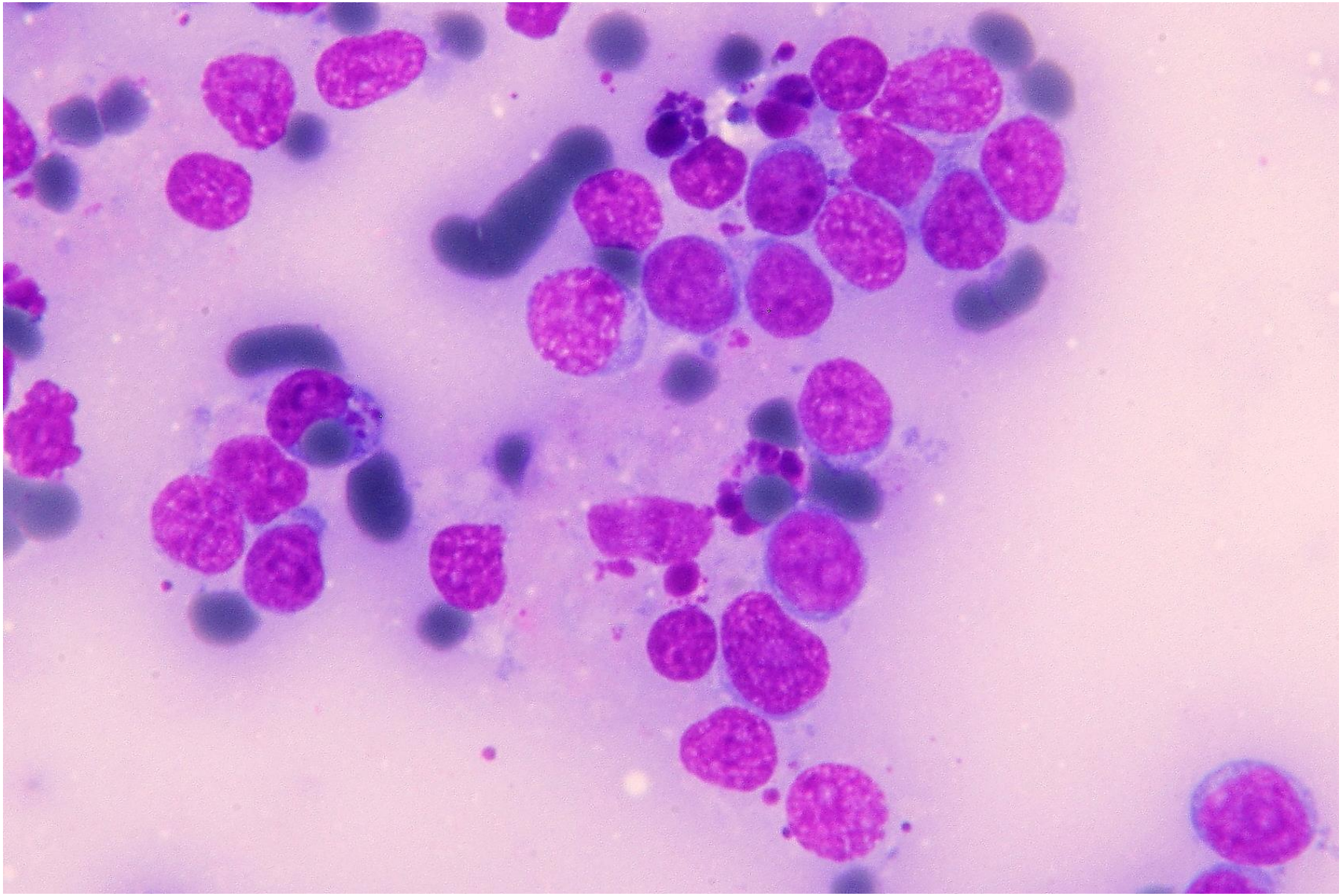

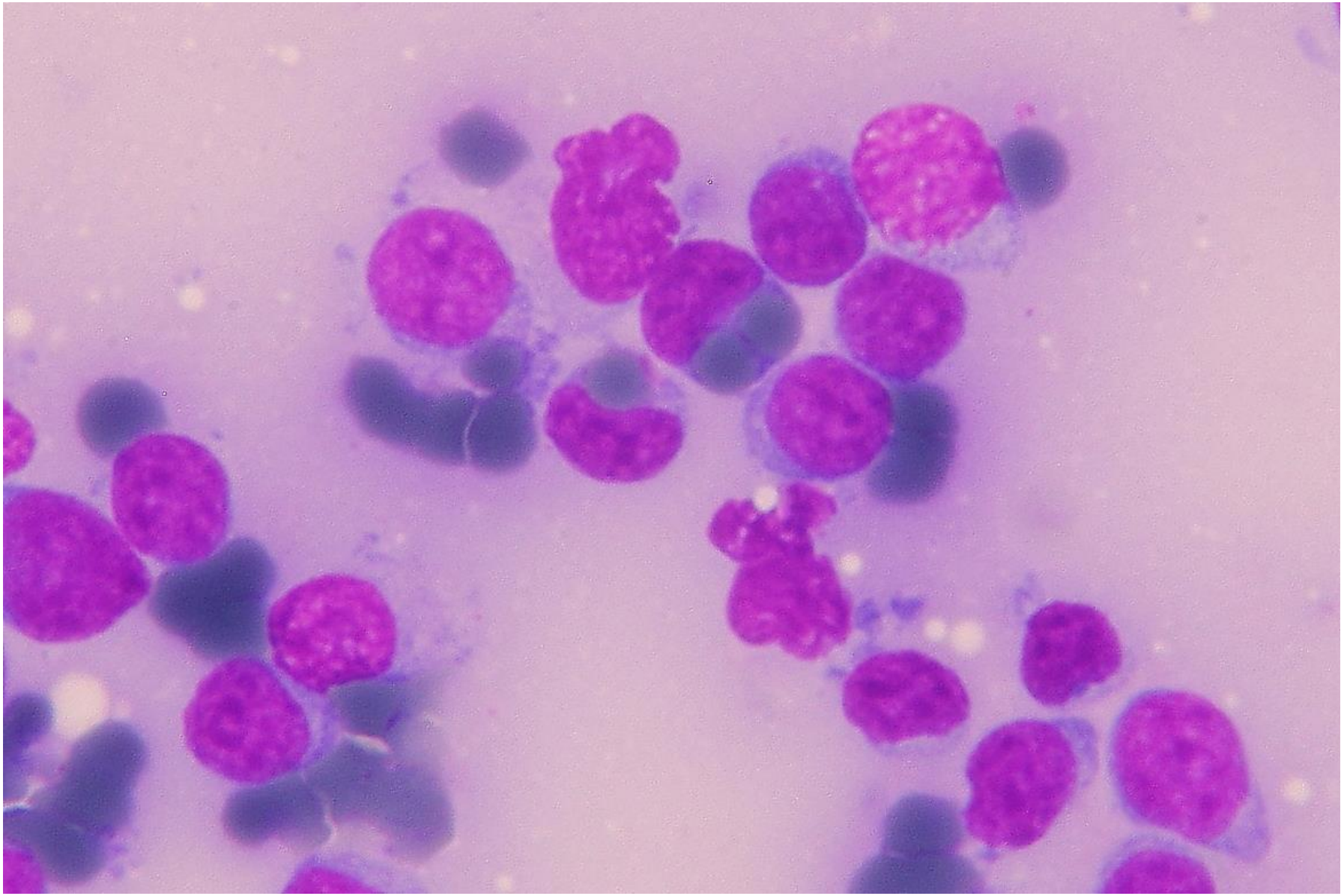

Cytologic findings

- Round cell with lymphoid appearance
  - Medium size
  - Erythrophagocytosis
  - Sometimes cytophagocytosis

Diagnosis

- Cytologic diagnosis
  - Lymphoma with erythrophagocytosis
  - Suspicion of cutaneous involvement in γ-δ T cell lymphoma

Comments

- The day after the cytological diagnosis, before any others investigations, the cat died
  - Necropsy was not performed
  - No final diagnosis was obtained
  - So sorry...
- Hypothesis???
  - Cutaneous (subcutaneous) localization of hepatosplenic lymphoma???
  - A specific form of cutaneous lymphoma??

Case #10

- 6 years old, neutered female cat
- 2 weeks history of anemia/leukopenia
- Cutaneous nodules and papules
- FeLV – FIV negative (PCR)
  - Biochemistry unremarkable
  - No treatment
- Blood and bone marrow

Catherine Trumel, DVM, PhD, ECVCP Dipl., ENV Toulouse France
Delphine Rivière, DVM, DU Cyto-Hematology, InovieVet Montpellier France

Additional tests

- **Skin lesion biopsies**
  - ✓Histiocytic infiltration suggestive of a progressive feline histiocytosis
    - ✓Weak to moderate atypia
  - ✓Immunohistochemistry: Iba1+++, CD204+, CD117 (cKit) –
    - ✓In agreement with histiocytic proliferation

CBC data

Variables	Values	Reference intervals
Ht %	**21,5**	30,3 – 52,3
Hb g/dL	**6,2**	9,8 – 16,2
MCV fL	**79,3**	35,9-53,1
MCMH g/dL	26,8	28,2 – 35,8
Retic 10^9/L	**129,8**	3,0-50,0
Leucocytes 10^9/L	**2,51**	2,87 – 17,02
- Neutrophils	0,75	2,30 – 10,29
- Lymphocytes	0,91	0,92 – 6,88
- Eosinophils	0,05	0,17 – 1,57
- Basophils	0,02	0,01 – 0,26
Platelets 10^9/L	10	151 – 600

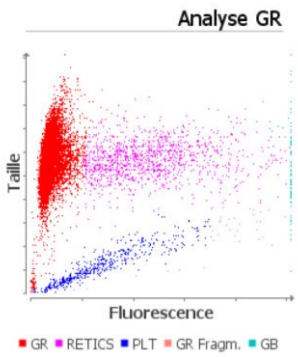

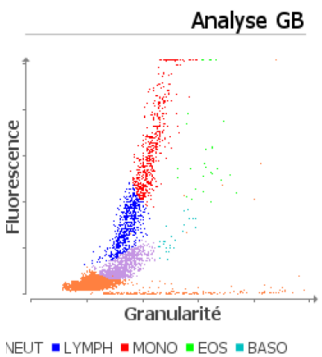

(ProCyte Dx Idexx)

Variables	Procyte	Manual count
Neutro %	21,5	47
Lympho %	6,2	24
Mono %	31,1	17
Eosino %	28,8	0
Baso %	0	2
Blasts %	0	10
nRBC /100WBC		21

Blood film

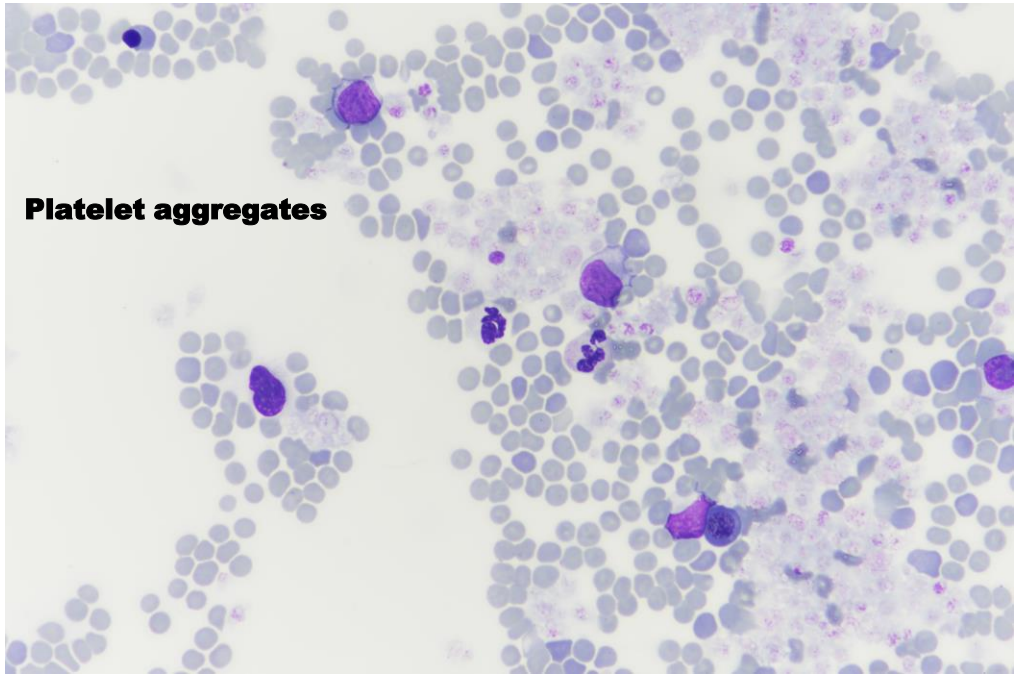

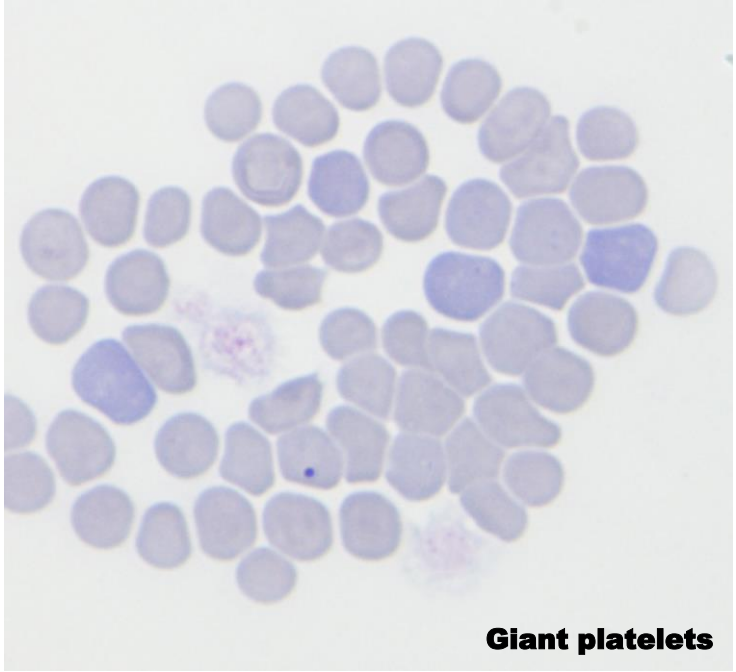

Blood film

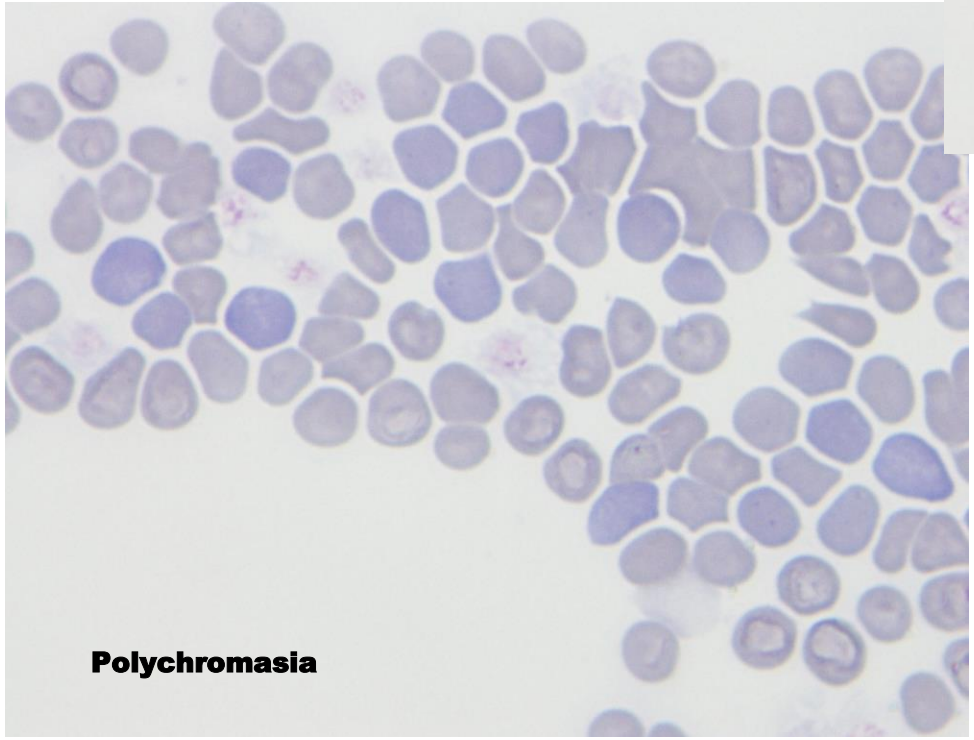

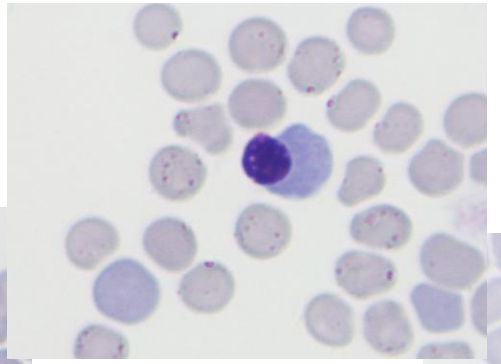

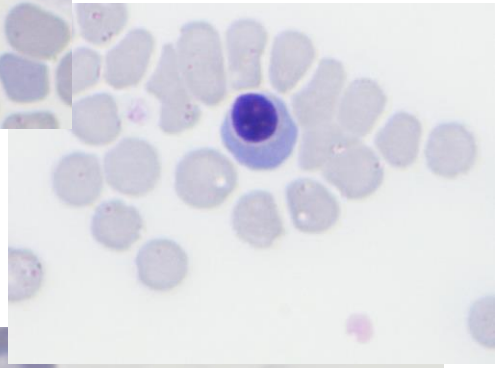

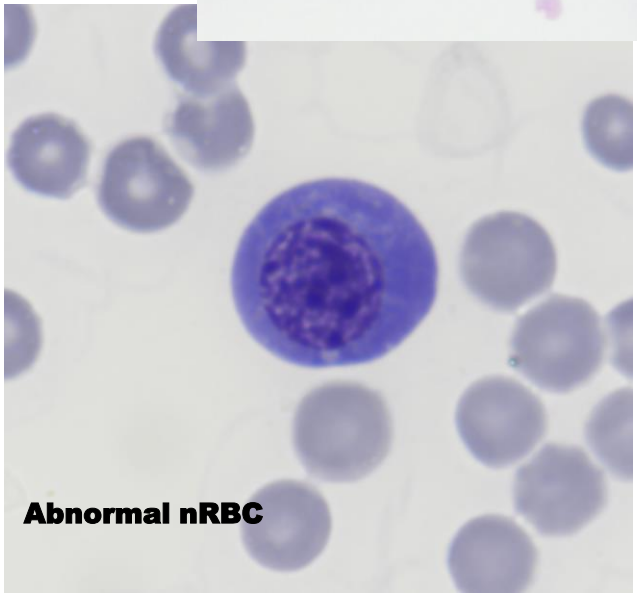

Blood film

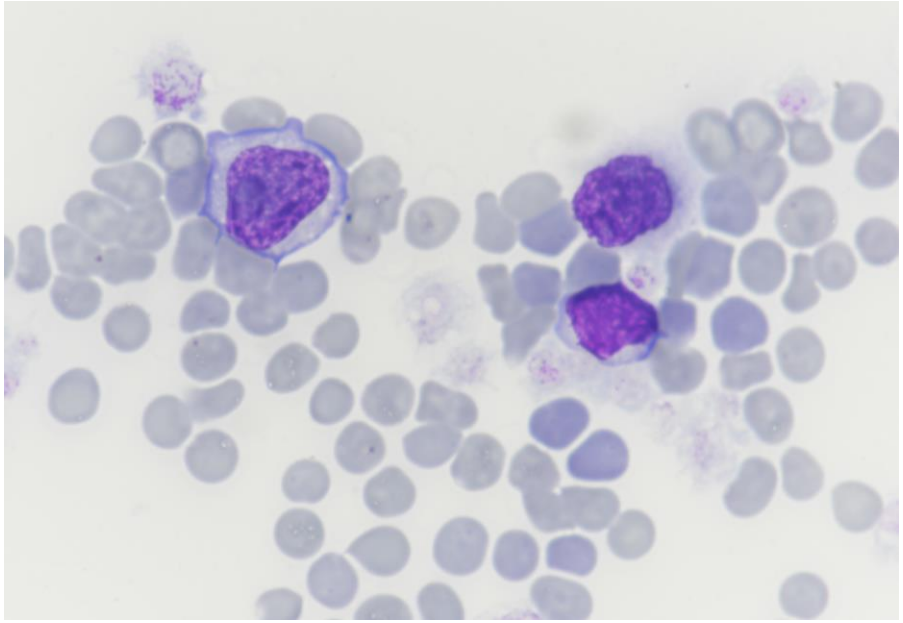

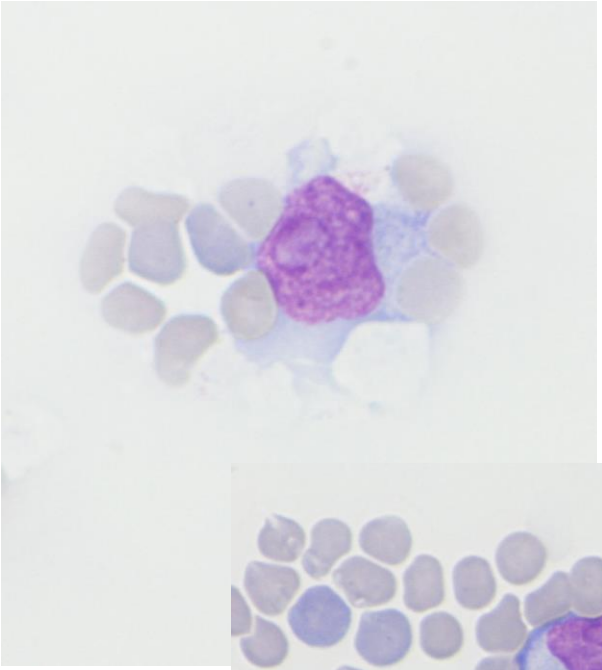

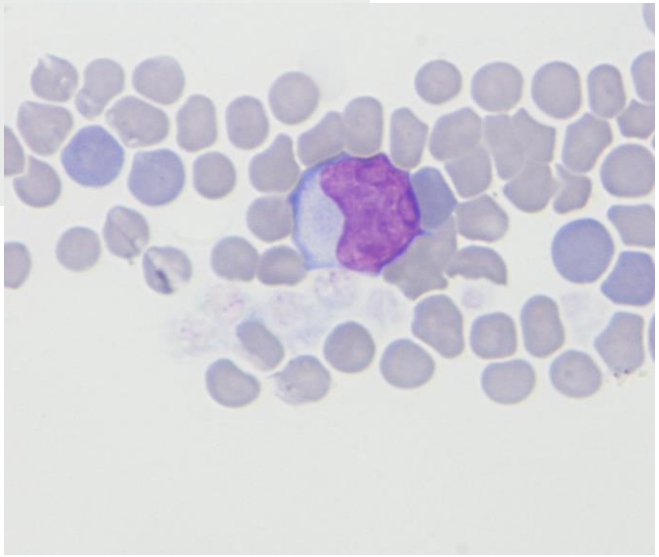

Blasts

Blood film

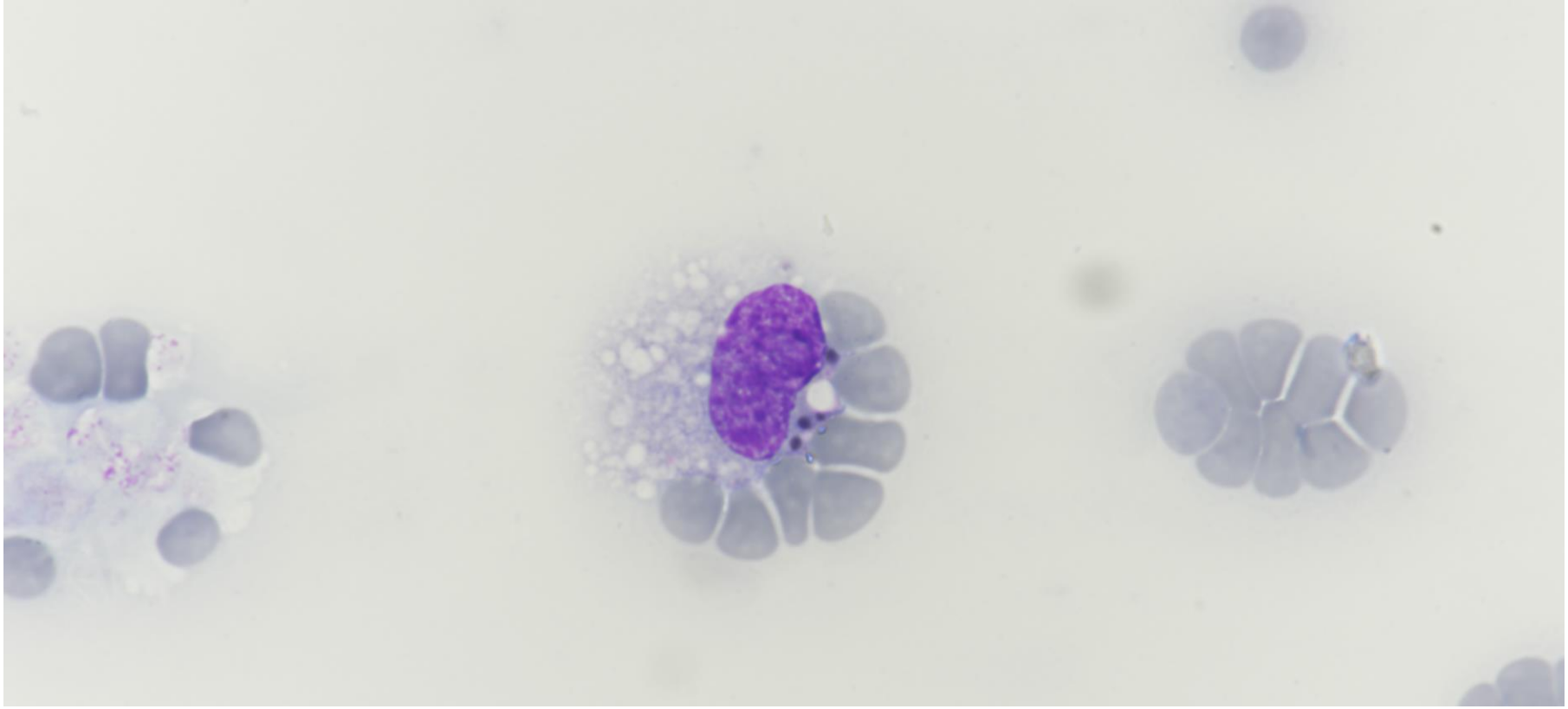

Macrophage with black granules highly suggestive of hemosiderin

CBC and blood film examination

- **Quantitative and qualitative abnormalities**
  - ✓Macrocytic regenerative anemia with dyserythropoiesis
  - ✓Leukopenia with neutropenia and blasts cells
  - ✓Presence of macrophages with a probable siderophagic activity
  - ✓Underestimation of platelet concentration (clumps)

Bone marrow evaluation

- Quality 4/4
- High cellular BM spicules
- Megakaryocytes 2/4

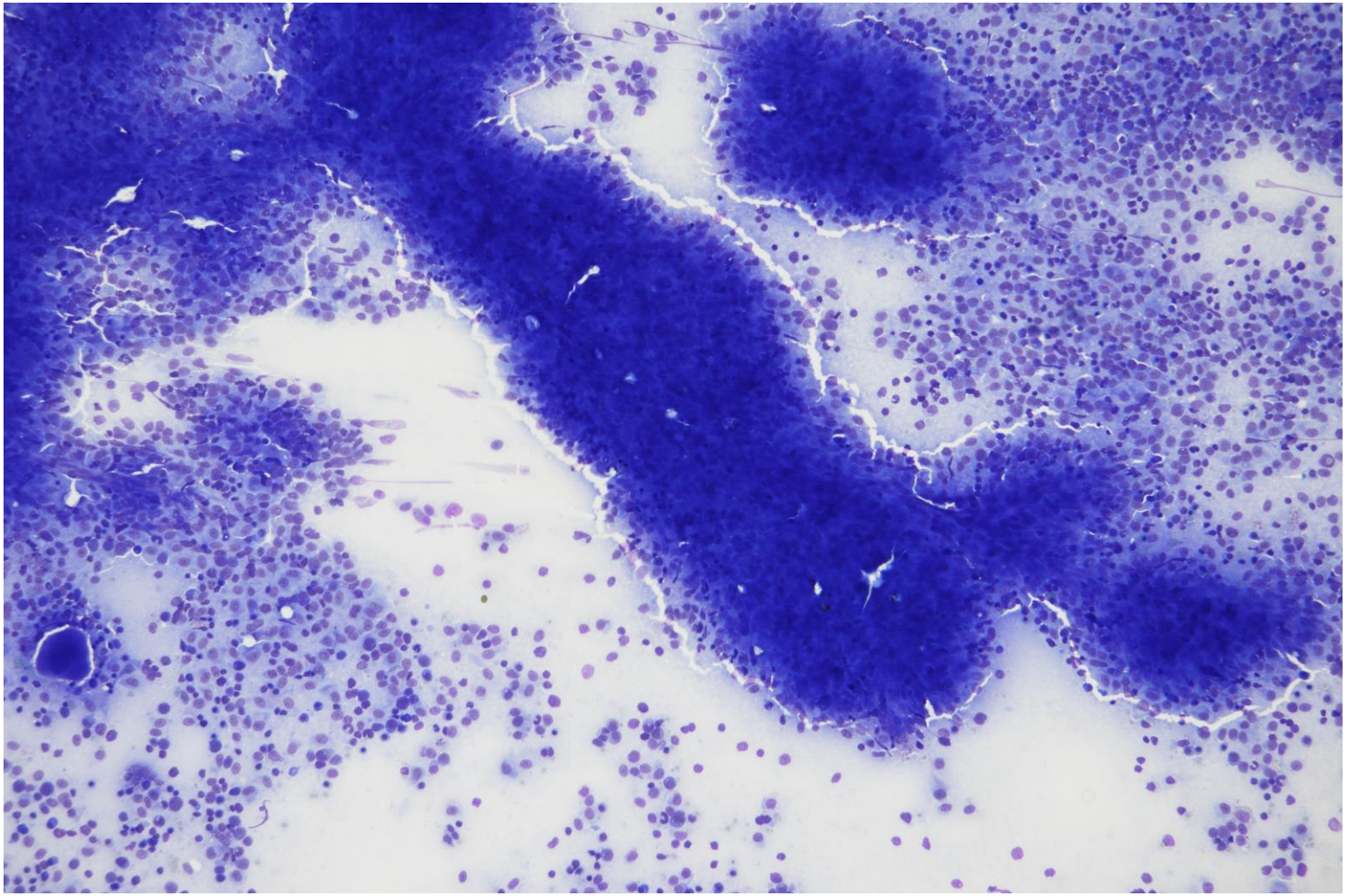

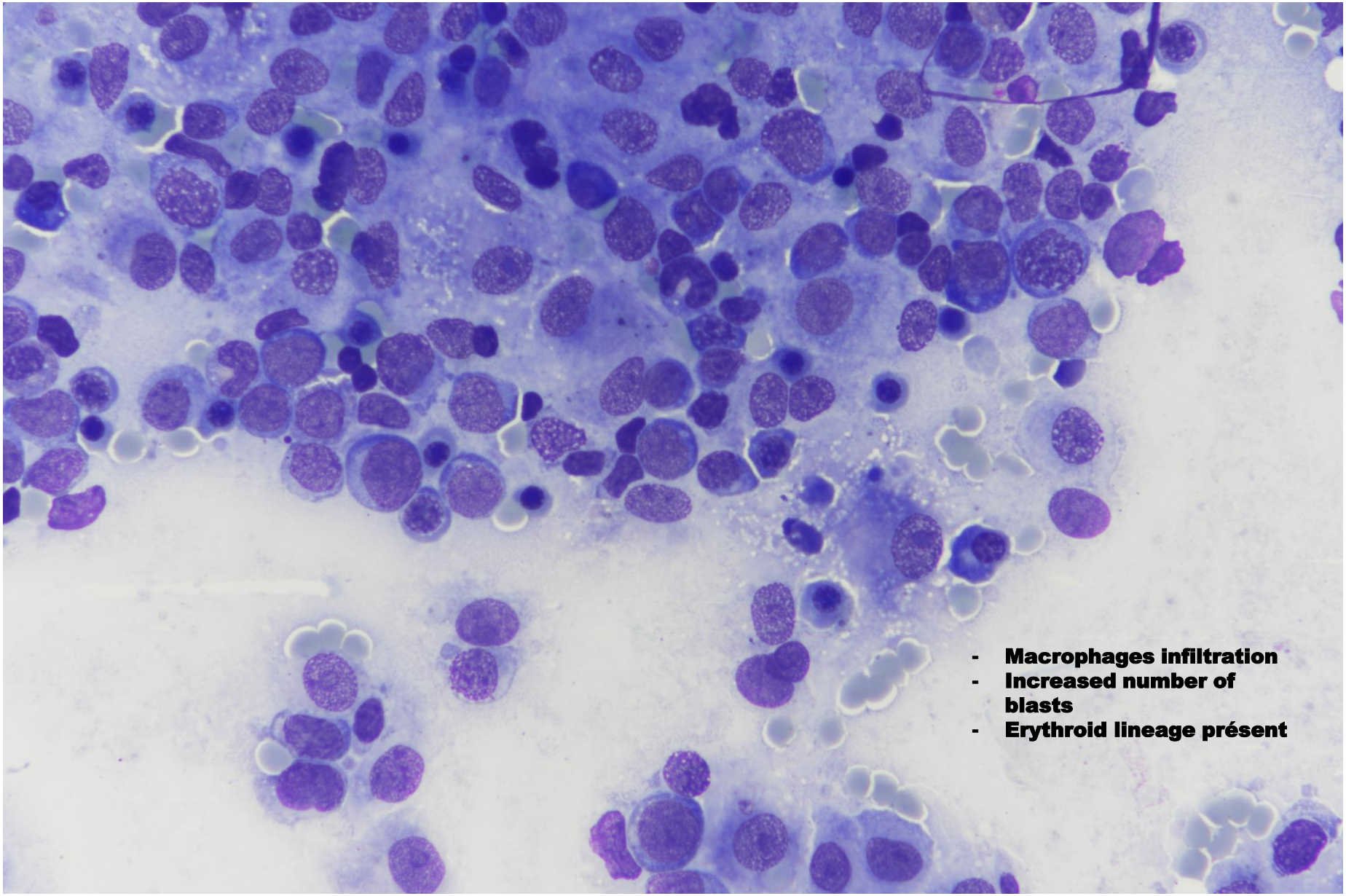
- Macrophages infiltration
- Increased number of blasts
- Erythroid lineage présent

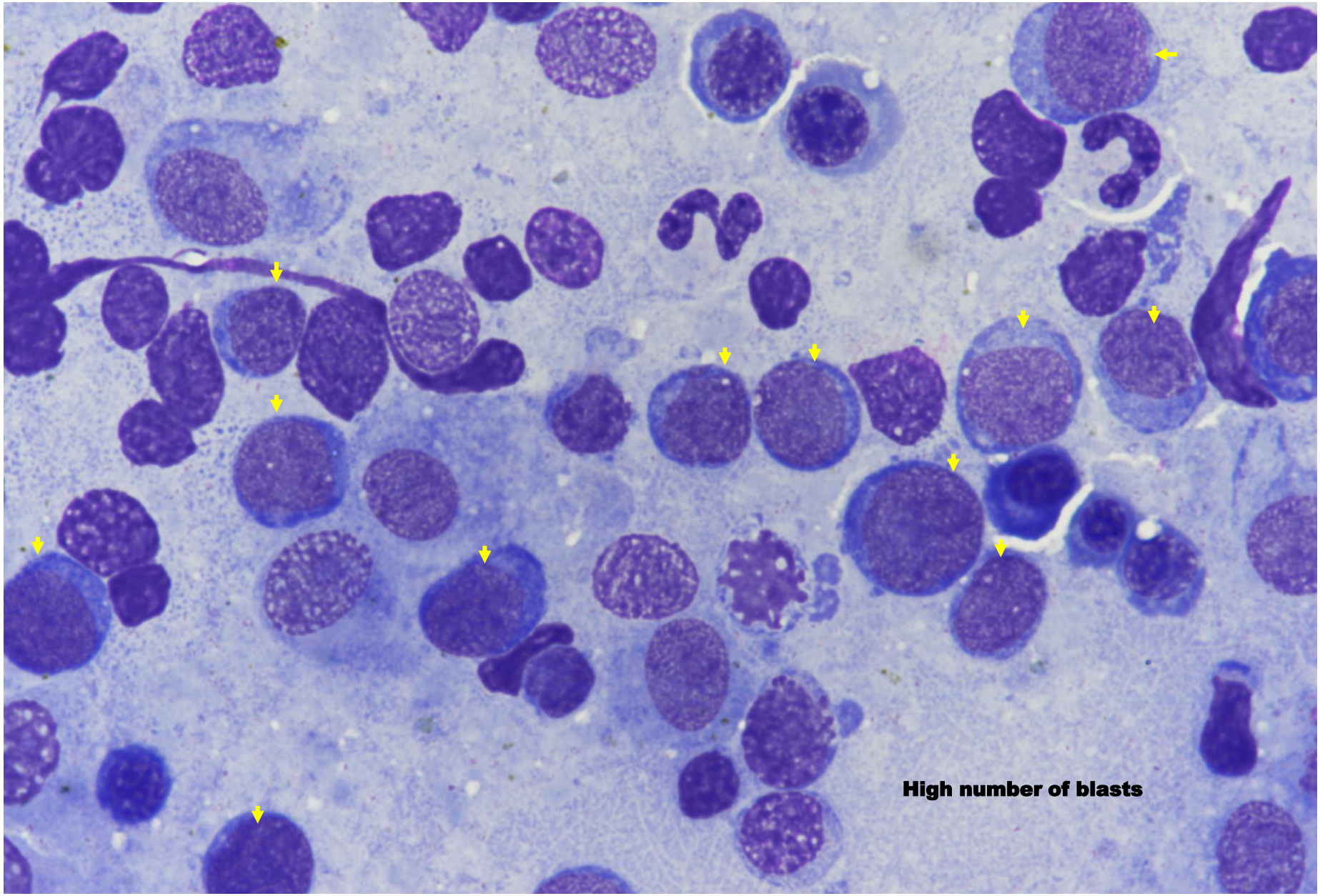
High number of blasts

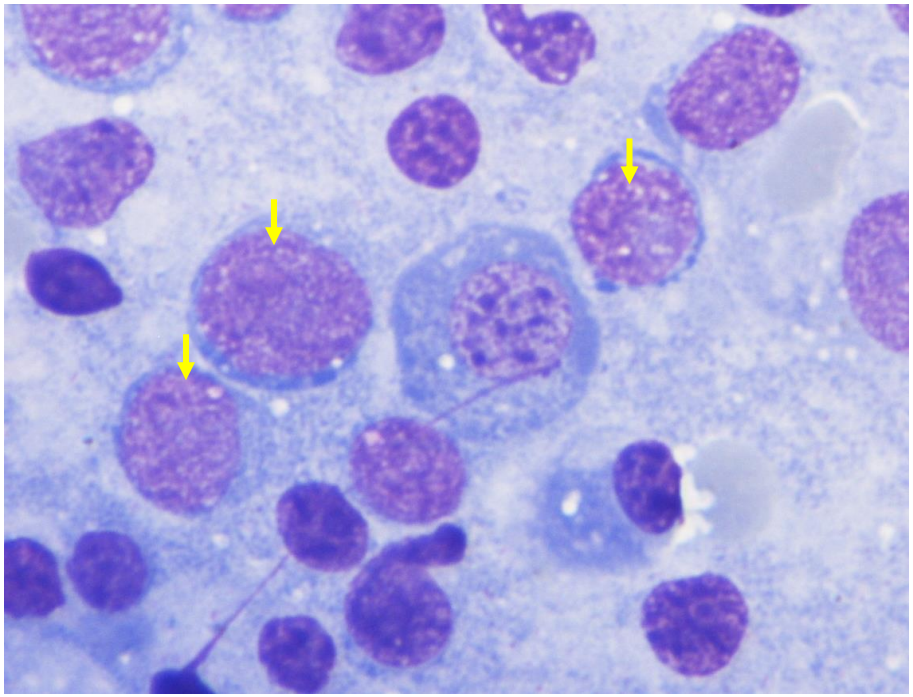

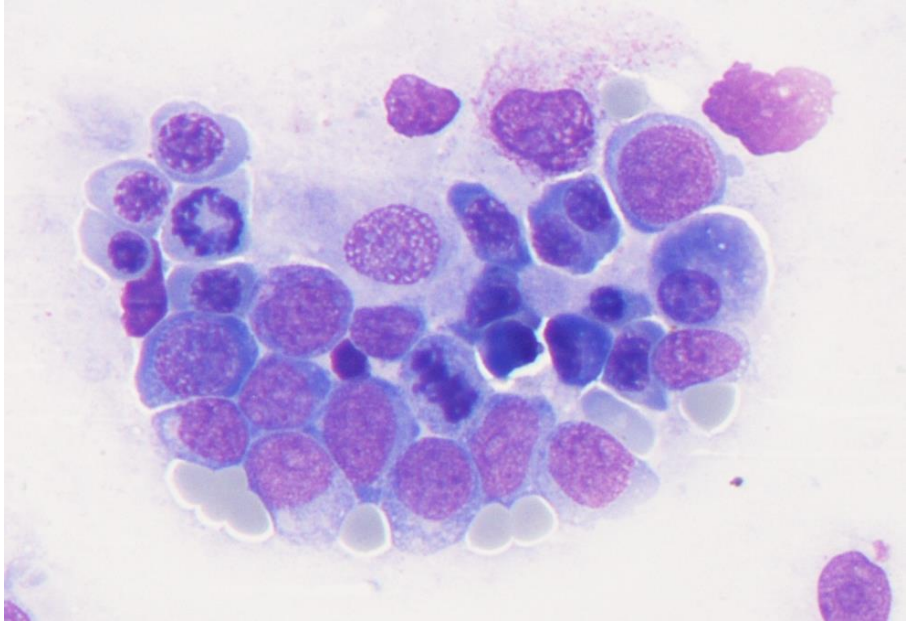

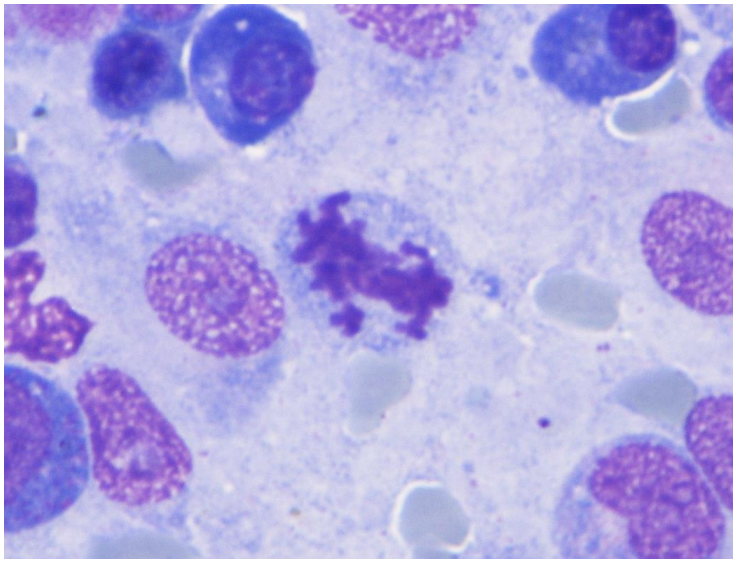

- **Increased number of blasts**
- **Erythroid lineage présent with dyserythropoiesis**
- **Regular abnormal mitoses**

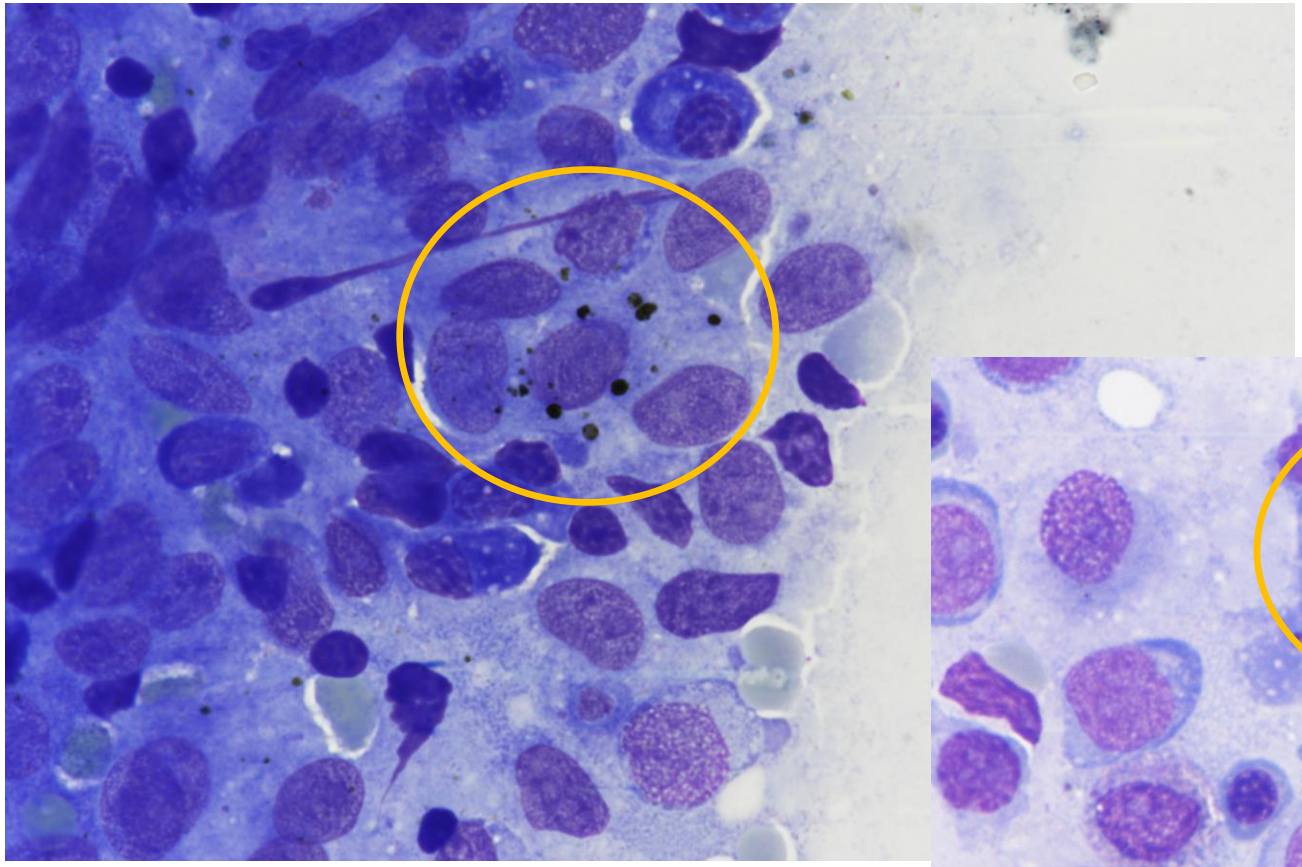

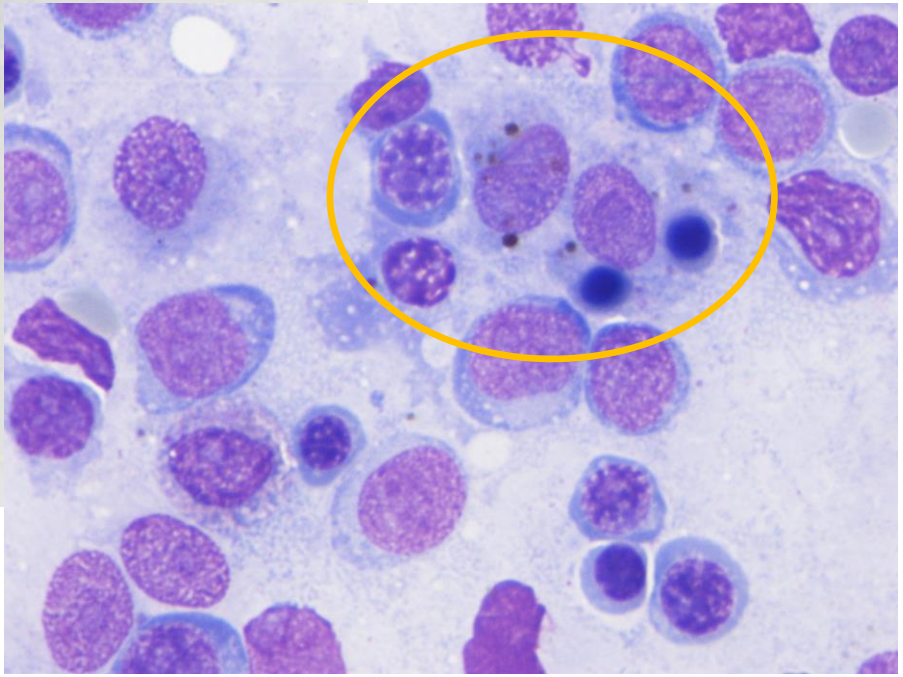

- **Macrophages infiltration**
- **Siderophagic activity - hemophagocytosis**
- **Plasma cells**

Bone marrow differential (total : 300)

MYELOID LINEAGE	Absolut count	Percentage
Myeloblasts	1	0,6%
Pro-myelocytes	1	0,6%
Myelocytes	0	0%
Neutrophil meta-metamyelocytes	2	1,1%
Band neutrophils	7	4,0%
Segmented neutrophils	3	1,7%
Myeloid granulocytic lineage	**14**	**8,0%**
OTHERS		
Eosinophilic cells	0	0%
Lymphocytes	48	16%
Plasma cells	15	5%
Macrophages	43	14,3%
Abnormal cells	86	28,7%

ERYTHROID LINEAGE		
Rubriblasts	4	0,9%
Pro-rubricytes	14	3,1%
Rubricytes	37	8,3%
Meta-rubricytes	39	8,7%
Erythroid lineage	**94**	**21%**

M/E ratio	**0,1**
EMI	**0,24**
MMI	**0,17**

Blood and bone marrow abnormalities

- **Marked macrocytic and regenerative anemia with dyserythropoiesis secondary to:**
  - Erythro and erythroblastophagocytosis
  - Decreased/abnormal erythroid lineage?
    - Bone marrow infiltration by macrophages and blasts of probable monocytic/histiocytic origin
- **Neutropenia secondary to:**
  - Leukophagocytosis?
  - Decreased myeloid lineage
    - Bone marrow infiltration by macrophages and blasts of probable monocytic/histiocytic origin
- **Circulating blasts and macrophages with bone marrow infiltration**

Treatment and follow-up

- Corticotherapy (2,5mg/day) is prescribed waiting for the biological and histological results
- 8 days later, the cat is presented in emergency for dyspnea
- Dies within an hour

Discussion

Histiocytic/monocytic disorders reported in cats

- Hemophagocytic syndrom
- Histiocytic sarcoma
- Feline progressive histiocytosis
- Hemophagocytic histiocytic sarcoma
- Feline pulmonary langherans cell histiocytosis
- AML 4/5

Is there a relationship between the bone marrow hemophagocytic activity and the cutaneous lesion qualified as feline progressive histiocytosis?

Diagnosis and differential

Hemophagocytic syndrom

- 👍bicytopenia, siderophages (blood and BM), hemophagocytosis (BM)
- 👎histiocytic proliferasia highly suspected, cutaneous lesion

Feline progressive histiocytosis

- 👍cutaneous lesions
- 👎bicytopenia, erythrophagocytosis, BM cells infiltration

Hemophagocytic histiocytic sarcoma

- 👍 bicytopenia, siderophages (blood and BM), hemophagocytosis (BM)
- 👎normal biochemistry, cutaneous lesion

Histiocytic sarcoma

- 👍 Multiple lesions, fatal and rapid evolution
- 👎 Low degree of atypia in cutaneous lesion, BM involvement, erythrophagocytosis, bicytopenia

Conclusions

Point of view 1

- ✓Feline progressive histiocytisosis

+

- ✓Hemophagocytic histiocytic sarcoma
  - Blood and BM hemophagocytosis
  - Well-differentiated macrophages
  - Bicytopenia (thrombope considered)

Point of vie

- ✓Late stage progres hist

IMMUNOSTAINING OF BONE MARROW NEEDED

Immunohistochemistry /cytochemistry
CD14+, CD68+, Lysozyme +, α1-antitrypsin +
Iba1+, HLA-DR, CD204+, CD163+, MAC387+
CD18+/CD11b+/CMHII+ (macrophagic profile)
positive for nonspecific esterase with fluoride inhibition (napthol butyrate substrate)

Vittoria Castiglioni

Jaco Van der Lugt

Eleonora Piseddu

Vanessa Turinelli



Manuele Manzocchi



Fabio Aloisio

Raffaella Bergottini

Thanks to ALESSANDRA TOSINI

Laboratorio Veterinario Bresciano

Brescia - Italy